

# Diagnosis and treatment of intraoperative bile duct injuries after cholecystectomy

Hadjibaev Abduhakim Muminovich

*doctor of medical sciences prof. General Director of RSCMP.  
100081. Tashkent city, Chilanzar district, Kichikhalkayuli street 2.*

Hadjibaev Farhod Abduhakimovich

*MD head department, Emergency Surgery RSCMP.  
100081. Tashkent city, Chilanzar district, Kichikhalkayuli street 2.*

Pulatov Mahmujon Muratjon ugli

*Doctor Resident Emergency Surgery No. 1, RSCMP.  
100081. Tashkent city, Chilanzar district, Kichikhalkayuli street 2.*

**Abstract:** *The results of repeated interventions were studied in 68 patients with intraoperative lesions of the intrahepatic ducts after cholecystectomy. There were 46 women (68.5%), 22 men (31.5%). The age of patients averaged 52.4 years. Standard deviation,  $\sigma$ : 18.787751111741. Along with traditional reconstructive operations, as the first stage of correction of intraoperative injuries, we widely used the therapeutic possibilities of endobiliary interventions.*

*In conclusion, it should be noted that the application of various anastomoses during VRS using a metal skeleton significantly reduces the risk of developing their postoperative narrowing and insufficiency of sutures, formed anastomoses and, accordingly, improves treatment results.*

**Keywords:** *biliary tract; postoperative complications, treatment; minimally invasive procedures.*

## **Introduction:**

The increase in the number of surgical interventions for cholecystitis and its complications, the expansion of the range and volume of interventions, led to a significant increase in the frequency of postoperative complications. For example, complications that develop after the traditional cholecystectomy and require repeated surgical intervention are observed in 0.7–4.6% of cases [1, 2, 6, 8, 14, 18, 22]. The complication rate after laparoscopic cholecystectomy (LCE) is 1.0-5.1% [1, 4, 15, 23, 24]. After endoscopic transpapillary interventions, complications occur in 0.6–23.4% of patients, 2% of them require surgical intervention for correction, and mortality in this case ranges from 0.4 to 2.3% [5, 7, 13].

Among the early intra-abdominal complications after various cholecystectomy options, along with postoperative peritonitis with bile leakage (0.3% -1.5%), abdominal abscesses (up to 0.8%), intra-abdominal bleeding (up to 4%), intraoperative injuries occupy a leading place extrahepatic bile ducts (EBD). The number of the latter increases daily, because after traditional interventions, the frequency of damage to the abdominal tract is 0.1-0.5%, after laparoscopic surgery - 0.3-3% [3, 7, 9, 10].

Surgical interventions for this pathology are for the most part very difficult, and their results do not always satisfy surgeons and patients. Scarring strictures after repeated operations on the biliary tract develop in the long term in 20-30% of patients, and mortality

reaches 8-40%. The insidiousness of intraoperative injuries of EBD lies in the fact that up to 90% of these injuries go unnoticed during the first operation [4, 6, 12, 14, 19, 20].

To date, experts have no consensus on the duration and extent of preoperative preparation of patients, the optimal technique for reconstructive and reconstructive interventions, methods of bile diversion, especially with high damage to the urinary tract, determining indications for the application of biliodigestive anastomoses and hepatic drainage of the biliary tract [9, 10, 11].

In this regard, **the purpose of this article** is to improve the results of treatment of intraoperative injuries of the extrahepatic bile ducts by using modern methods of diagnosis and surgical correction.

### **Material and methods**

In total, in the Department of Emergency Surgery, Republican Scientific Centre of Emergency Medical Aid of the Ministry of Health of the Republic of Uzbekistan for the period from 2001 to 2018 For all 10,218 patients, various cholecystectomy options were performed according to emergency indications under balanced general anesthesia with mechanical ventilation.

Moreover, TCE was performed in 4261 (41.7%) patients, cholecystectomy mini-laparotomic access (MLA) - in 864 (8.5%) and LCE - in 5093 (49.8%) patients. Out of 10218 patients undergoing cholecystectomy, only 68 (0.66%) patients in the postoperative period showed intraoperative damage to the urinary tract requiring repeated interventions. Most often, these complications occurred after LCE (41), they were observed less frequently after TCE (21) and MLA (6).

This work is based on an analysis of the results of repeated interventions in 68 patients with intraoperative lesions of EBD with cholecystectomy. There were 46 women (68.5%), 22 men (31.5%). The age of patients averaged 52.4 years.  $\pm$ ,  $\sigma$ : 18.787751111741

A comprehensive examination was performed for all patients with intraoperative damage of EBD after cholecystectomy, including the implementation of general clinical, laboratory and special instrumental research methods. General clinical and laboratory research methods made it possible to assess the general condition of patients, the clinical severity of the existing symptoms of intraoperative damage to the urinary tract, central hemodynamics, microcirculation, and based on them to determine the degree of operative-anesthetic risk. Special instrumental methods of research included the use of modern diagnostic technologies such as ultrasound (ultrasound) of the liver and biliary tract, endoscopic retrograde pancreaticholangiography (ERPC), percutaneous transhepatic cholangiography (PTC), fistulography, MRI cholangiography (MRCP). In addition, intraoperative cholangioscopy and cholangiography were performed during repeated operations. Such a comprehensive examination allowed us to correctly determine the surgical tactics of treating existing intraoperative damage to the urinary tract.

### **Results**

The table. 1 shows data on the variants of primary HEC and types of intraoperative damage of EBD in the examined patients.

**Table 1. :Variants of primary HEC and types of intraoperative damage of EBD in examined patients**

Type of damage / operation	THE n=4261	LHE n=5093	MLA n=864	Total n=10218
Crossing / or stitching of the common bile duct	4 (0,094%)	14 (0,27%)	2 (0,23%)	20 (0,19%)
Bandaging of the common bile duct	14 (0,33%)	-	2 (0,23%)	16 (0,15%)
<i>Parietal complete</i>	8 (0,18%)	-	1(0,15%)	9 (0,088%)
	6 (0,14%)		1(0,15%)	7 (0,068%)
Clipping of the common bile duct	-	18 (0,35%)	-	18 (0,18%)
Defect of the choledoch wall	3 (0,07%)	9 (0,17%)	2 (0,23%)	14 (0,13%)
Total	21 (0,49%)	41 (0,81%)	6 (0,69%)	68 (0,66%)

From the data of Table 1 it is evident that intraoperative injuries of EBD after cholecystectomy were of various nature. Thus, at examination in 20 patients there was revealed an intersection and piercing of hepatocholedoch at the level of the bladder duct, in 16 patients - parietal (9) or complete (7) dressing, in 18 patients - clipping at the level of the bladder duct, in 14 patients - hepatocholedoch defects.

The following main clinical symptoms were accompanied by EBD damage: jaundice - in 34 (0,33%) patients, cholangitis - in 24 (0,23%), bile peritonitis - in 22 (0,21%), external bile fistula - in 15 (0,15%) and hepatic abscess - in 9 (0,88%), while in 25 (0,24%) patients there were a combination of 2 or more symptoms.

It is necessary to note, that for correction of the available intraoperative damages of EBD after cholecystectomy in the examined patients we, along with the restorative and reconstructive operations (RRO) on biliary tracts by traditional laparotomy, used the possibilities of modern endobiliary interventions (EBI).

Table 2. presents data on the types of RRO and EBI used by us to correct the existing intraoperative lesions of EBD in the examined patients.

From the data of Table 2. it is clearly seen that we have applied EBI in 34 patients examined as the first stage of the surgical correction of the intraoperative lesions of EBD accompanied by the clinics of MG (21), GC (10) and external bile fistula (3).

**Таблица 2.: Виды ВРО и ЭБВ, примененных для коррекции интраоперационных повреждений ВЖП после ХЭК (n=102)**

Виды открытых операций	.ч.	%
<b>Endobiliary interventions</b>		<b>3</b>
- ERCP + EST + ENB	<b>4</b>	<b>3,3</b>
- EST + endobiliary stenting		2
- PTC and PTCC	4	3,6
		1,
		9
		7,
		8
<b>Recovery operations :</b>		<b>2</b>
- restoration of hepatic choledochus on the drainage of Pikovsky	<b>2</b>	<b>1,6</b>
- restoration of hepatic choledochus on the drainage of Kera		4,
- restoration of hepatic choledoch, on Vishnevsky's drainage		9
-BBA end to end using a metal ring	2	1
		1,8
		1,
		95
		2,
		95
<b>Reconstructive surgery :</b>		<b>4</b>
- CDA, HDA	<b>6</b>	<b>5,1</b>
- ChEA, HEA on the turned off loop along the Ru of the jejunum		1
- ChEA, HEA with Brown Intestinal Anastomosis	1	0,7
- ChEA, HEA by Ru on a metal frame		5,
- ChEA, HEA with EEA according to Brown on a metal frame		95
- bi HEA by Ru on RTD		5,
- tri HEA by Ru on RTD		95
- HEA at THD by Prader Smith		5,
- tri, bi HEA by Ru on a metal frame		95
- Brown submersible fistuloenteroanastomosis with inter-intestinal anastomosis on a metal frame		5,
		95
		1,
		95
		1,
		95
		1,
		95
		2,
		8
<b>Total</b>	<b>02</b>	<b>00,0</b>
		<b>1</b>

At the same time, we considered ERCP with endoscopic papillosphincterotomy (EPST) and nasobiliary drainage (NBD) as the main EBI, which was performed in 24 (23.6%) patients. In 2 (1.9%) patients, in connection with a tumor lesion of the BDP, EST was supplemented by endobiliary stenting. If the cannulation of the BDP was unsuccessful in 8 patients with intraoperative damage to the HPV, we successfully applied another EBI method in the form of PTC and PTCC.

In 68 patients with intraoperative damage to the urinary tract, as a second final stage, various types of RRO were performed on the biliary tract. Basically (46) we performed these operations in a deferred order. However, in 22 patients with injuries of the common bile duct, we performed reconstructive operations according to emergency and urgent indications.

At the same time, total recovery operations were performed in 22 patients. So, the passage of bile into the intestines in 12 patients was restored by a suture on a T-shaped drainage between the damaged ends of the hepaticoholedoch. Restoration of hepatic choledochus and drainage of the common bile duct was carried out according to Vishnevsky in 2, according to Pikovsky in 5, and in 3 patients biliobiliary anastomosis (BBA) was applied end to end using a metal ring.

Reconstructive operations, consisting in the creation of various types of anastomoses, were performed in 46 patients. Choledocho-, hepaticoduodenoanastomosis (CDA, HDA) was used in 11 patients, hepatic (choledocho) enteroanastomosis (CEA, HEA) in the loop off according to Ru - in 6, HEA / CEA with inter-intestinal anastomosis according to Brown - in 6, HEA / CE or according to Brown on a metal skeleton - in 12. With higher lesions of the hepatic choledochus, three bi-GEAs were performed on an off loop according to R of the jejunum on the metal skeleton in 5 patients. For proximal strictures, external and through removable drainages (4), transhepatic drainage according to Prader-Smith (2) were used for reliable formation of anastomosis. These drains were stored for a long time (up to 2 years) in the lumen of the anastomosis; if necessary, they were replaced (replaceable drains) with others.

In patients with intraoperative lesions of EBD, the average number of bed days was  $12.4 + 1.4$ . In total, 4 (5.9%) patients died in the postoperative period. The cause of death was anastomotic suture failure and continued peritonitis (2), hepatic-renal failure due to severe intoxication with purulent cholangitis and sepsis (1) and pulmonary embolism (1).

## **Discussion**

Intraoperative damage to the EBD - as a postoperative complication of various variants of HEC, is undoubtedly an urgent problem of modern emergency biliary surgery. In this regard, issues of improving timely diagnosis and carrying out adequate correction, these complications always remain in the focus of attention of specialists involved in biliary diseases [3, 7, 9, 10, 12, 14, 17, 21].

This study is devoted to a detailed analysis of the results of diagnosis and treatment of 68 patients with intraoperative damage to the urinary tract after various options for HEC. Along with traditional reconstructive and reconstructive surgeries (RRO), as the first stage of correction, we have widely used the therapeutic possibilities of endobiliary interventions (EBI) for the correction of intraoperative damages of EBD.

At the same time, with regard to the RRO of intraoperative damage to the abdominal tract, it should be noted that in order to improve the treatment results of these patients, when applying various anastomoses, we widely used the capabilities of metal frames in the form of titanium rings (Fig. 1).


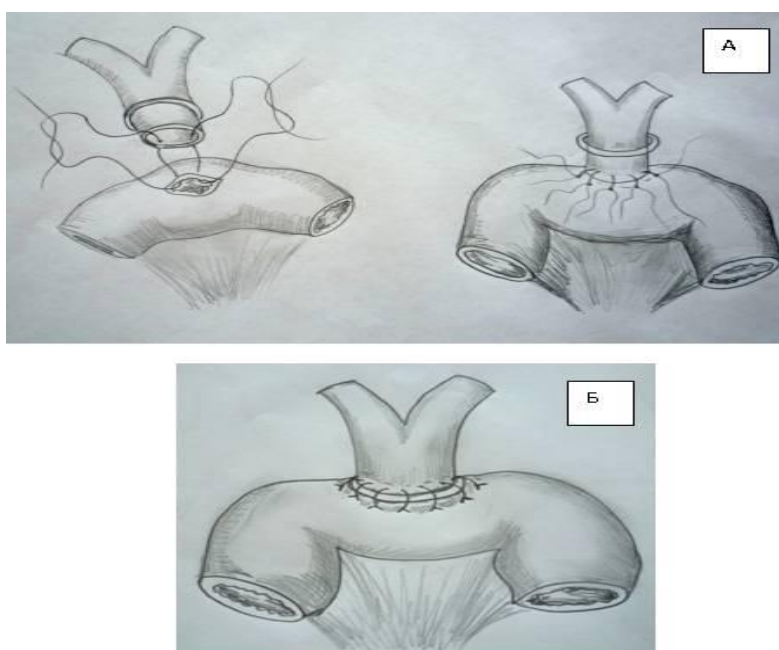


Figure 1. Titanium ring used for bilobiliary and biliodigestive anastomoses.

In total, in 20 patients, metal frames of various diameters were used in the formation of bilobiliary and biliodigestive anastomoses (Fig.2).



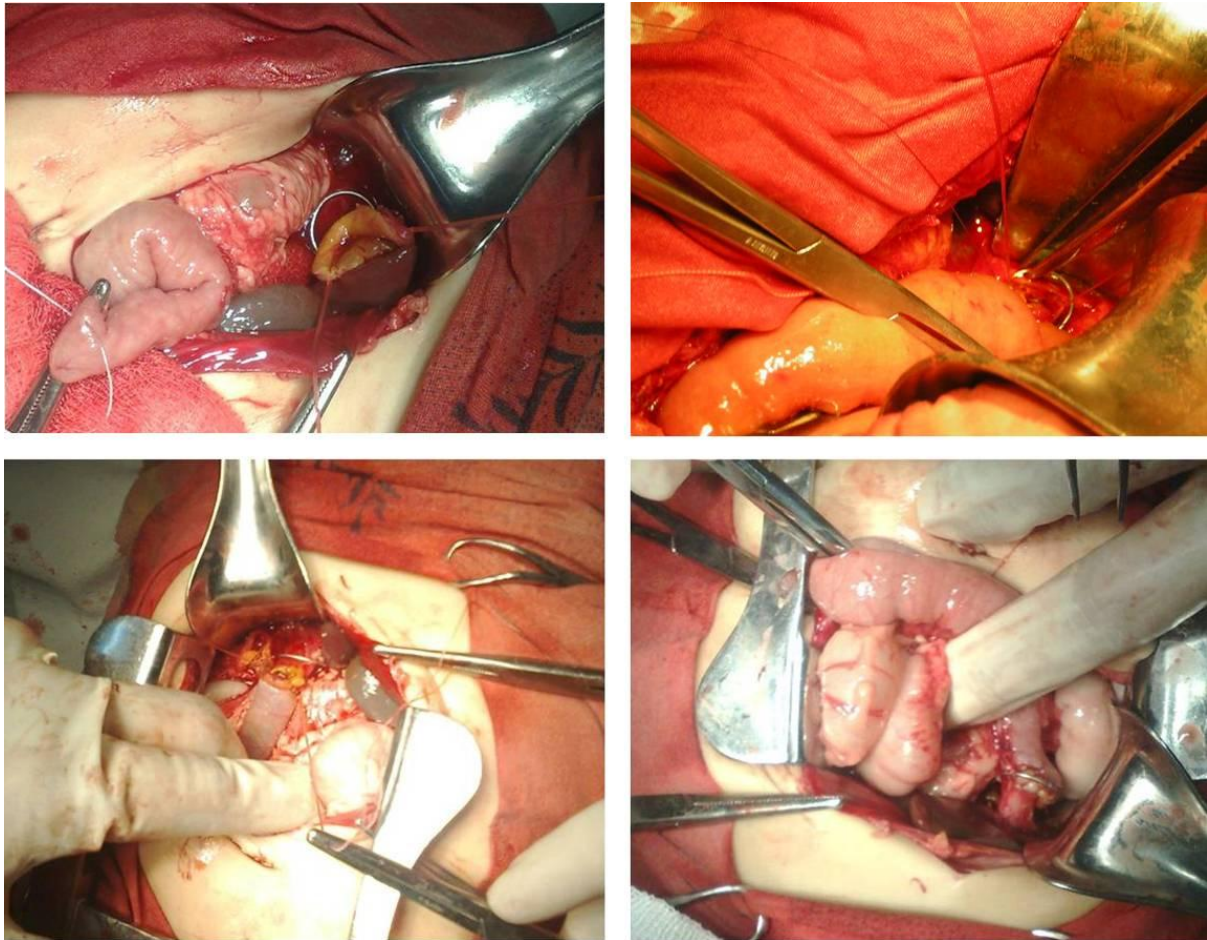


Figure 2. Formation (a) and the final stage of the formation of biliodigestive anastomosis with a fixed outer frame (b).

The main advantages of anastomoses superimposed on a metal frame with RRO, in our opinion, were as follows: the metal ring does not noticeably complicate the technique of applying anastomoses; it is made of a biologically inert material, does not cause an inflammatory, proliferative and structural tissue reaction in the anastomosis zone; being outside the lumen of the EBD, the metal ring does not directly come into contact with bile, does not undergo inlay and obstruction; it is a means of further strengthening the anastomosis line, which significantly reduces the risk of insufficiency of the joints of the anastomosis, mechanically prevents scarring strictures contraction of the anastomosis and prevents the development of anastomotic stenosis in the postoperative period.

Summing up the analysis and discussion of the results of the study, we can conclude that the issues of diagnosis and effective treatment of intraoperative damages of EBD after HEC still remain relevant and require further development.

Surgical tactics in this category of patients is determined on the basis of a comprehensive examination that includes general clinical, laboratory and special instrumental methods of research.

Surgical treatment of intraoperative damage to the EBD in these patients is carried out by traditional RRO and modern EBI, the timing and extent of which depends on the nature of the complication.

The application of various anastomoses during the RRO using a metal frame significantly reduces the risk of developing their postoperative narrowing and insufficiency of sutures, formed anastomoses and, accordingly, improves treatment results.

## References

- [1] Alidzhanov FB, Baimuradov Sh.E., Khozhibayev A.M. et al. Tactics for the treatment of destructive forms of cholecystitis using minimally invasive technologies. Actual problems of the organization of emergency medical care: Abstracts. - Urgench, 2006.-- P.74-75.
- [2] Altiev B.K., Khakimov Kh.Kh., Khadzhibayev F.A., Khashimov M.A. Diagnosis and tactics of treatment of choledocholithiasis with diverticula of the papillary area of the duodenum // Tomsk State University Journal. ext. medicine. - 2013. - No. 1. - S. 8-10.
- [3] Beburishvili A.G., Vedenin Yu.I., Zyubina E.N., Stroganova E.P. Complications of the surgical correction of iatrogenic lesions and strictures of the bile ducts // Annals of surgical hepatology. - Volume 13. - No. 3.-2008.-S. 108
- [4] Halperin E.I., Vetshev P.S. Guidelines for biliary tract surgery. - 2nd ed. - M.: Vidar-M, 2009.-- 568 p.
- [5] Halperin E.I. Obstructive jaundice: a state of "imaginary stability", consequences of a "second stroke", treatment principles // Annals chir. hepatol. - 2011. - T. 16, No. 3. - S. 16-25.
- [6] Delibaltov K.I., Maistrenko N.A., Romashchenko P.N., Pryadko A.S., Aliev K.A. Diagnosis and surgical treatment of iatrogenic damage to extrahepatic bile ducts: Dis. ... cand. honey. sciences. Stavropol, 2011.
- [7] Korolev M.P., Fedotov L.E., Avanesyan A.G., Fedotov B.L., Lepekhin G.M. et al. Combined anti- and retrograde restoration of continuity of the common hepatic duct after combined iatrogenic damage: scientific publication / Herald of Surgery. I.I. Grekova. - SPb., 2016. - Volume 175. - N2. - C. 105-107.
- [8] Mizurov N.A., Derbenev A.G., Voronchikhin V.V. Treatment of cholelithiasis and its complications: Textbook. allowance. Cheboksary: Publishing house of Chuvash. University, 2010.104 s.
- [9] Nazyrov F.G., Khadzhibayev A.M., Altiev B.K. Surgery for injuries and strictures of the bile ducts // Surgery. - 2006. - No. 4. - S. 46-52.
- [10] Nazyrov F.G., Akbarov M.M. et al. A modern strategy for the treatment of iatrogenic injuries of the extrahepatic biliary tract and external biliary fistula: a scientific publication. Surgery of Uzbekistan. - Tashkent, 2014. - Volume 63- N3. - C. 41
- [11] Nazyrov F.G., Akbarov M.M., Devyatov A.V., Nishanov M.Sh., Saidazimov E.M. Surgical treatment of patients with "fresh" injuries of the main bile ducts // Actual problems of hepatopancreatobiliary surgery: Abstract. doc. 21st International congress of hepatopancreatobiliary surgeons of the CIS countries. - Perm, 2014.
- [12] Yakubov E.A., Ergashev N.Sh. Reconstructive operations of extrahepatic bile ducts in some forms of choledochal cysts in children: scientific publication. Journal of Theoretical and Clinical Medicine. - Tashkent, 2016. - N6. - C. 88-92.
- [13] Strusky L.P., Devyatov B.A., Ugarov B.A. Advanced stenting technology for iatrogenic bile duct injuries. Annals surgeon, hepatology. - 2007. - No. 3. - S. 112-113.
- [14] Hadzhibayev A. M., Altiev B.K., Atadzhanov Sh.K., Khoshimov M.A. Diagnosis and treatment of intraoperative bile duct lesions in laparoscopic and traditional cholecystectomy: scientific publication / Surgery of Uzbekistan. - Tashkent, 2011. - No. 3. - C. 17-18
- [15] Hadzhibayev A.M., Atadzhanov Sh.K., Hadzhibayev F.A. Laparoscopic cholecystectomy in acute gangrenous cholecystitis / Surgery of Uzbekistan. - Tashkent, 2011.-- N1. - C. 51-55
- [16] Agarwal N. Agarwal N, Sharma B.C., Garg S., Kumar R. Endoscopic management of postoperative bile leaks / Hepatobiliary-Pancreat-Dis-Int. 2016 May; 5(2): 273-7.
- [17] Akimboye F., Lloyd T., Hobson S. et al. Migration of endoscopic biliary stent and small



- bowel perforation within an incisional hernia // Surg. Laparosc. Endosc. Percutan. Tech. – 2006. –Vol. 16, № 1. –P. 39-40.
- [18] Assaban M., Aube C., Lebigot J., Ridereay-Zins C., Hamy A., Caron C. Mangafodipir trisodium-enhanced magnetic resonance cholangiography for detection of bile leaks // J-Radiol. 2016 Jan; 87(1): 41-7.
- [19] Balmadrid B., Kozarek R. Prevention and management of adverse events of endoscopic retrograde cholangiopancreatography //Gastrointest. En-dosc. Clin. North Amer. – 2013. – Vol. 23, №2. – P. 385-403.
- [20] Becker B.A., Chin E., Mervis E., Anderson C.L., Oshita M.H., Fox J.C. Emergency biliary sonography: utility of common bile duct measurement in the diagnosis of cholecystitis and choledocholithiasis // J. Emerg. Med. – 2014. – Vol. 46, №1. – P. 54-60.
- [21] Christoforidis E., Vasiliadis K., Goulimaris I. et al. A single center experience in minimally invasive treatment of postcholecystectomy bile leak, complicated with biloma formation // J. Surg. Res. – 2007. – Vol. 141, № 2. – P. 171-175.
- [22] De-la-Morena-Madrigal E.J. Impact of combined precut techniques on selective biliary cannulation // Rev. Esp. Enferm. Dig. – 2013. – Vol. 105, №6. – P. 338-344.
- [23] Katsinelos P., Lazaraki G., Chatzimavroudis G., Gkagkalis S., Va-siliadis I., Papaeuthimiou A., Terzoudis S., Pilpilidis I., Zavos C., Kountouras J. Risk factors for therapeutic ERCP-related complications: an analysis of 2,715 cases performed by a single endoscopis // Ann. Gastroenterol. – 2014. – Vol. 27, №1. – P. 65-72.
- [24] Qiu Z., Sun J., Pu Y., Jiang T., Cao J., Wu W. Learning Curve of Transumbilical Single Incision Laparoscopic Cholecystectomy (SILS): A Preliminary Study of 80 Selected Patients with Benign Gallbladder Diseases. World Journal of Surgery. - 2011. Vol. 35, № 9.-P.2092-2101.