

BIFID CONDYLE-

Title Page with Authors details

Correspondance to: Dr. Kirthika.R¹, Post graduate in the department of oral and maxillofacial surgery, Sree balaji dental college and hospital, pallikaranai, chennai-100.

Author Details:

1)Dr. Kirthika.R¹, Post graduate in the department of oral and maxillofacial surgery, Sree balaji dental college and hospital, pallikaranai, chennai-100.

2)Dr. Balakrishnan Ramalingam², professor in the department of oral and maxillofacial surgery, Sree balaji dental college and hospital, pallikaranai, chennai-100.

Department – oral and maxillofacial surgery

College/university name- Sree balaji dental college and hospital / Bharath university.

Location / place – Chennai/ pallikaranai.

Email ID- kirthikar7@gmail.com

Country – INDIA.

ABSTRACT-

Bifid condyle an exceptional and a rare disorder presents with the duplication of the condyle head. Incidence rate- 0.31% to 1.82%. Szentpetery et al, the incidence of bifid condyle to be 0.48% in 1,882 cadaveric skulls. In 1941, Hrdlica first diagnosed on a 21 cases of specimen Smithsonian Institution in Washington DC of which 18 were unilateral and 3 bilateral. In 1948, Schier reported the first live case of bifid condyle. According to Cowan and Ferguson 1997, at least 36 clinical cases of BMC.

KEYWORD-

Bifid condyle, temporal fossa, OPG, trauma.

1. INTRODUCTION-

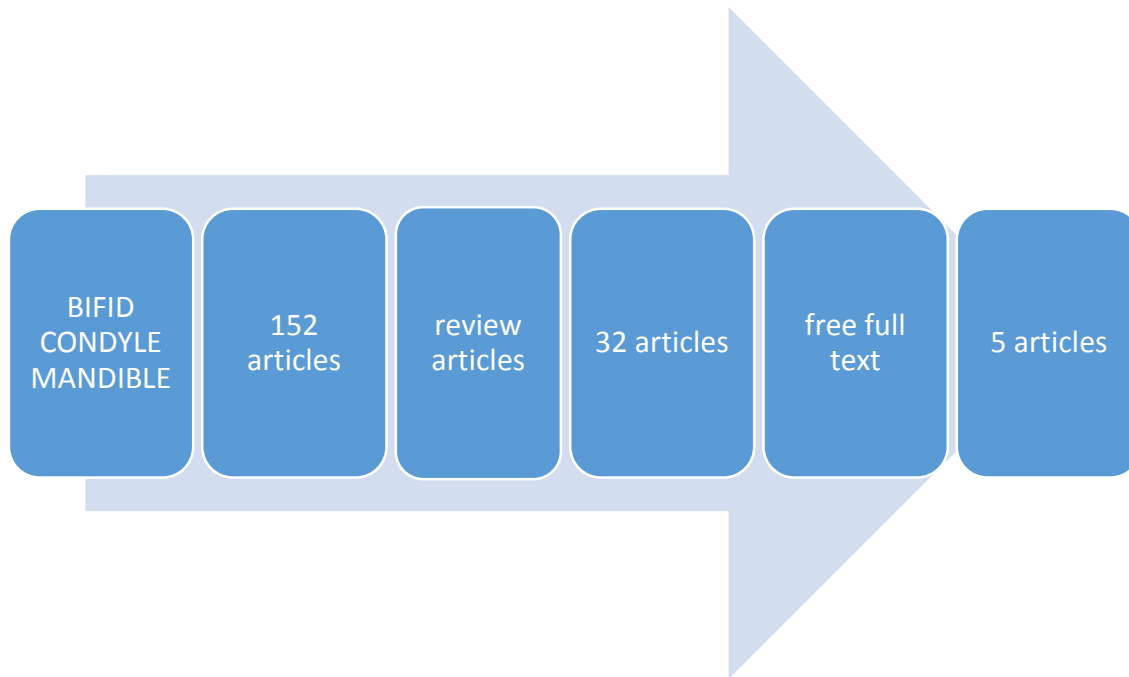
Bifid condyle^(1,3,6) can occur as a result of developmental, infection, trauma, condylar fractures. Be secondary to trauma, obstructed blood supply or embryopathy, developmental anomalies, secondary to condylar fracture, perinatal trauma, and surgical condylectomy. Possible causes may be developmental, traumatic, vascular, abnormal muscle pulling, nutritional, endocrinal (nutrients, irradiation, infection, ankylosis, and genetic factors), teratogenic, and infections.

Many factors that seem to be involved such as integrity and shape of the articular disk, the presence of a fibrous septum(hemarthrosis), the remodeling capability, muscle insertion, presence of fracture or dislocated fragment and the articular capsule status.

There is no marked difference when it comes to sex preference or race. It can occur unilateral or bilateral, but medical literature reveals that more often unilaterally than bilaterally. At the moment june 2020, only 40 cases have been reported in literature. Around 1948- 2010 total of

131 living cases were reported. In recent years, there has been a sudden increase in the number of cases reported, which may be attributed to the widespread use of radiographic (mostly CT scan) methods.

2. **Methods** – pubmed search for the ([All Fields] AND ("bone and bones"[MeSH Terms] OR ("bone"[All Fields] AND "bones"[All Fields]) OR "bone and bones"[All Fields] OR "condyle"[All Fields]) AND ("mandible"[MeSH Terms] OR "mandible"[All Fields])) AND (Review[ptyp] AND "loattrfree full text"[sb]).



3. Discussion –

On Radiographic examination^(2,3)- OPG, computed tomography (CT) – axial and coronal section MRI, ultrasonography, and cone beam CT scan plays an important role. Accordingly, Sampaio et al, 1968 a retrospective study which reported CT was more a reliable method when compared with OPG because it tells you the condylar morphology but also helps to perform differential diagnosis with tumors and primary osseous cysts, metastatic lesions, fracture, dislocation, displacement, degenerative bony lesions and metabolic lesions.

Its Characteristic feature are Vertical depression^(4,5,6) or deep cleft in the middle of the condylar head. Bifid condyle occurring at anteroposterior position is due to trauma and mediolateral plane has developmental origin. Dennison et al. considered that only the anteroposterior-oriented condyles are “true” BMC and that those in mediolateral position must be excluded from the grouping and instead be termed “condylar notching”.

Bifid condyle with akylosis- This may cause a deformity of the articular fossa, compromising functions such as the speech, mastication, and limitation of mouth opening. Asymptomatic (congenital etiology) patients are detected in routine examination. Whereas symptomatic patient has pain, swelling, noise, hypomobility, joint block, deflection, joint luxation, limitation of mouth opening, ankylosis, facial asymmetry, and swelling in the affected region

Non-steroidal anti-inflammatory^(1,4) drugs, physiotherapy or occlusal splint (hard or soft) are recommended as a conservative approach. Surgical treatment has only been described to restore function in BMC with ankyloses, in cases of symptomatic resistant to conservative treatments. Proper treatment depends on the symptom. Patients with associated articular ankylosis might need surgical condylectomy or arthroplasty.

Hrdlicka postulated that obstructed blood supply to the condyle during its development can result in the division to the condyle. Blackwood suggested the persistence of vascularized fibrous septa which disappears normally at the age 2 which might lead to an error in the development (influences the ossification), that could in turn give rise to the bifid condyle.

Poswillo et al⁽⁴⁾ stated that bifidism occurs as a result of changes in the position of disc or form, leading to the formation of intra-articular septa across the joint space (bifid condyle). Gundlach et al⁽⁵⁾ he believed that combination of tetratogenic and misdirection of the muscle fibers influences the bone formation. He experimentally injected N-methyl nitrosourea in rats. According to Artvinli & Kansu⁽³⁾ postulates that the trauma as the major cause with dislocation of joint integrity due to birth trauma, condylar fractures or surgical condylectomy.

According to Hesketh et al, the site of the fracture (head, neck of condyle) and its relation to the insertion of the lateral pterygoid muscles are factors determining the future development of bifid condyle. According to de Sales et al⁽²⁾, 2004 proposed that trauma involving TMJ or micro trauma due to malocclusion might cause bifid condyle. According to Jordi Borrás-Ferrerres et.al⁽⁶⁾, in a systematic review of 431 articles found that patients with bifid condyle had an average age of 30.6 (SD=14.7) years. Women to men ratio found to be 1.4:1. Both right and left bifid condyle were equally prevalent, there was no side discrimination.

Unilateral involvement was the most common in which 25% were Mediolateral condylar position. Bifid condyle was common among patients accounting for about 80.1%, 7 trifid and 2 tetrafid condyles were found. Traumatic etiology was present in 40.8% while 55.9% didn't have any relevant medical background. 60% of the patient were asymptomatic(86 literature) , others the common complaint was hypo mobility(49 literature), arthralgia(38 literature), articular noise(35 literature). Occlusal splint and physiotherapy was the common treatment opted by the patients.

According to Andras szentpetery et al⁽⁵⁾, he assessed 1882 skulls from Hungary at the period of Neolithic period to the 18th century. He analyzed 2077 cases, of which 2077 condyles 7 cases with signs of a bifid condyle were found. No cases with complete bifid condyles were seen. Of these 7 cases, 2 were left and 5 were right partially bifid condyles; sex predilection 2 were found in males, 5 in females. In all 7 cases, the grooving was mainly anteroposteriorly directed, dividing the condyles in a medial and a lateral half. Menezes et al, examined 50,080 OPG radiographs between 1999 and 2006 and reported only nine bifid condyle cases was present. Later in 2010, Miloglu et al examined 10,200 OPG in a Turkish population and reported 32 bifid condyle.

According to Szentpetery⁽⁵⁾ et al in 1990 of 1882 cadaveric study found that the incidence of this anomaly to be 0.48%. According to the current English literature, which concluded that anteroposterior splitting of the condyle occurs in patients due to trauma while mediolateral splitting is usually developmental in origin. Artvinli and Kansu published a clinical case of a 25 years old woman with bifid and trifid condyles with history of a trauma in a same patient. Other

authors ⁽⁶⁾ have proposed that the theory is based on the fact that after a condylar neck fracture, an anteromedial displacement of the condyle is produced due to the lateral pterygoid muscle activity. After the anteromedial displacement a new condylar head appears by metaplasia in a correct anatomic position, whereas the displaced condyle initiates a resorption process. Though this theory cannot be theoretically be same for all age patients. Growth of the condyle in young and adult cannot be the same. According to Almasan et al, the majority of cases have a mediolateral orientation, independently from history of trauma or not.

According to Mahesh et al, he reported a case of 34 years male with gross asymmetry of face, transorbital temporomandibular projection imaging was done and diagnosed with bilateral bifid condyle. The patient was asymptomatic so no treatment was advised. According to Acikoz et al, to evaluate the internal derangement of the TMJ and joint disk magnetic resonance imaging (MRI) is necessary, MRI has been the best tool for diagnosis so far.

The treatment of all symptomatic bifid condyle associated with limited mouth opening, mastication, speech and ankylosis requires surgical intervention (Artvinli & Kansu; de Sales et al.). There are three basic techniques for surgical correction of temporomandibular ankylosis: gap arthroplasty, interpositional arthroplasty and gap arthroplasty along with joint reconstruction (Daniels & Ali), complete ramus condyle reconstruction. In the asymptomatic cases, the treatment is usually conservative or no treatment is necessary, which is similar to the treatment for the closely associated TMJ pain dysfunction syndrome (analgesics and anti-inflammatory agents, muscle relaxants, physiotherapy, splint). Based on Antonia et al.; Martín et al., the patients with bifid condyle must be controlled and followed-up.

Hotz ⁽⁶⁾ studied radiologically the different stages of condylar remodeling (reformation) after fractures in childrens. In his article he gives a detailed report on the formation of a new condyle in normal position and the resorption of the fractured one. He observed that the idea that the fractured condyle will never form a callus with the rest of the mandible, but undergoes total resorption, and an entirely new condyle is formed in normal position in the mandibular fossa. This article supports his concept, as the development of a new functional condyle has been shown and because no functional force would be able to reposition the fractured condyle. These studies demonstrated good growth potential of the mandibular condyle following fractures in childrens. However, this article shows no formation concerning the age up to which the formation of a new condyle can occur.

According to Edward et al ⁽⁶⁾, 53 year old male patient with the history of condyle fracture accompanied by left bifid condyle and a malformed right condyle. The most common al-kayat and bramley incision was used to expose both the joints. The bony and fibrous adhesions present near the anterior clinoid process were excised, leaving a gap of 2 cm, and wired to the zygomatic arch with 2 stainless steel wires to restore the vertical height of the ramus and prevent re-ankylosis of the joints. The Coronoidectomy was not found to be necessary and extensive post-operative physiotherapy to the masticatory muscles was planned.

According to Stadnicki et al 1971 reported a baby girl of 3years with symptoms of limited opening, and a bifid condyle following a forceps delivery. She developed TMJ ankylosis and required surgery and a regular follow up. Rupam Sinha ⁽⁶⁾ 2016 reported a case of 24 year old male with discomfit in TMJ, shoulder and neck with bifid condyle, Eagles syndrome and Ely's cyst and was treated with conservatively and given a physiotherapy.

4. **Conclusions:** The main objective of this systematic review was to describe and to determine etiological, clinical, characteristic features and radiological characteristics and the treatment options (surgical or conservative). BMC may have congenital or traumatic etiology. Hypomobility and arthralgia are the most frequent symptoms and treatment options are often conservative. Etiology of bifid condyle developmental is common in which CT is the best diagnostic tool. Mesiolateral orientation is most common. No direct relationship was present between condyle orientation and etiology.

5. References-

1. Katti G, Najmuddin M, Fatima S, Unnithan J. Bifid mandibular condyle: Rare disease. *BMJ Case Rep* 2012;1-4. [doi 10.1136]. bcr-2012-007051.
2. Kamtane S, Subramaniam A. Bifid mandibular condyle: A very rare entity. *Pak Oral Dent J* 2011;31:14-6.
3. Hrdlicka A. Lower jaw: Double condyles. *Am J Phys Anthropol* 1941;28:75-89.
4. Szentpétery A, Kocsis G, Marcsik A. The problem of the bifid mandibular condyle. *J Oral MaxillofacSurg* 1990;48:1254-7.
5. Stadnicki G. Congenital double condyle of the mandible causing temporomandibular joint ankylosis: Report of case. *J Oral Surg* 1971;29:208-11.
6. Gunduz K, Avsever H, Karacayli U. Bilateral bifid condylar process. *Int J Morphol* 2010;28:941-4.