

Original research article

Functional and Radiological Outcome following Surgical Management of Bimalleolar and Trimalleolar Ankle Fractures

Dr Vikramadityasingh V Samorekar

Senior resident, Department of Orthopaedics, Gadag Institute of Medical Sciences,
GADAG

Corresponding Author: Dr Vikramadityasingh V Samorekar

Abstract

Introduction: Ankle fractures are extremely common. However, the outcomes of operatively treated bimalleolar and trimalleolar ankle fractures remain unclear. We aimed to evaluate clinical, functional and radiological outcomes of operatively treated bimalleolar and trimalleolar ankle fractures.

Materials and Methods: A retrospective review of all patients with operatively treated ankle fractures for a period of 3 years was performed. Demographics, fracture pattern, operative details, postoperative radiographs, and complications were obtained, studied and analyzed statistically. Outcome variables included union rates, pain ratings using the visual analogue scale (VAS) and the Olerud and Molander (O&M) score, satisfaction with surgery and surgical complications.

Results: Sixty patients with bimalleolar and trimalleolar ankle fractures were recruited. At 1 year postoperatively, most patients regained good function and had mostly good O&M scores. There were no notable differences in terms of VAS and O&M scores for both the bimalleolar and trimalleolar ankle fracture patient group. However, 33 (55%) of 60 patients had residual pain. Thirty seven (62%) patients complained of stiffness, and 27 (45%) patients had ankle swelling.

Conclusion: Most of our patients despite some residual deficits recovered well in their second year following surgery. No difference was observed in functional outcome between bimalleolar and trimalleolar ankle fractures, although it is a great concern that notable number of patients will continue to have residual symptoms. Hence residual symptoms and functional limitation must be emphasized to patients prior to surgery to manage postoperative expectations.

Key words: Unimalleolar, Bimalleolar, Trimalleolar, Olerud and Molander score, Haraguchi, Denis Weber, Lauge Hansen, Visual analogue score(VAS).

Introduction

Ankle fractures are common injuries seen in Orthopaedic practice.¹ Ankle fractures are classified based on the number of malleoli involved: unimalleolar, bimalleolar, and trimalleolar. Uni- and bimalleolar fractures account for majority of ankle fractures, whereas trimalleolar fractures constitute only 7% of all ankle fractures.^{2,3,4} Previous studies have shown that unstable ankle fractures following operative fixation will have some residual functional deficits.⁵ Trimalleolar fractures have also been shown to result in poorer functional outcome

scores, severe osteoarthritic changes, and residual symptoms depending on the size of the posterior malleolar fragment.⁶ Despite this, there is a lack of studies directly comparing the results of operatively treated bimalleolar and trimalleolar ankle fracture. Even less is known about the functional and radiological outcome for bimalleolar and trimalleolar ankle fractures. We aim to evaluate Clinical, functional and radiological outcome following surgical management of bimalleolar and trimalleolar ankle fractures

Materials and Methods

We retrospectively reviewed all patients admitted to our institution for surgical management of ankle fractures from January 2016 to December 2018. These patients were identified using the diagnosis and their unique UHID number given by the hospital. Their case sheets, X-rays and CT-scans were reviewed. Fractures were categorized radiographically into Uni, Bi and Trimalleolar fractures. Denis weber and Lauge Hansen classification was used. Outcome variables were union rates, pain assessed using visual analogue scale (VAS) and Olerud and Molander (O&M) score¹⁸ (Figure 1), satisfaction with surgery, and complications.

Inclusion criteria:

1. Patients having closed bi and tri-malleolar ankle fractures.
2. Patients who are above the age of 18 years

Exclusion criteria-

- 1) open fractures
- 2) Poly-trauma
- 3) Concomitant fractures in the ipsilateral lower limb
- 4) Pathological fracture
- 5) Concomitant neurovascular injury in the ipsilateral lower limb
- 6) Pilon fracture
- 7) Unimalleolar ankle fractures
- 8) Patients who were treated by non operative methods

All patients were 18 years old and above and completed at least 1 year of follow up. Pertinent data on patients' demographics, clinical assessments, pre-operative X-ray and CT-scan findings, operative details, post-operative X-rays and complications were extracted and analyzed statistically.

Modified Olerud and Molander scoring system¹⁸

Scores range from a minimum (zero) to a maximum (100) points.

Parameter	Degree	Score
Pain	None	25
	While walking on uneven surface	20
	While walking on surface outdoors	10
	While walking indoors constant and severe	5
Stiffness	None	10
	Stiffness	0
Swelling	None	10
	Only in evenings	5
	Constant	0
Stair climbing	No problems	10
	Impaired	5
	Impossible	0
Running	Possible	5
	Impossible	0
Jumping	Possible	5
	Impossible	0
Squatting	No Problems	5
	Impossible	0
Supports	None	10
	Taping, Wrapping	5
	Stick or Crutch	0
Work, Activities of daily life	Same as before injury	20
	Loss of Tempo	15
	Change to simpler job	15
	Severely impaired work capacity	0

Figure 1:

Haraguchi classification (Figure-2) was used to determine the extent of posterior malleolar fragment.

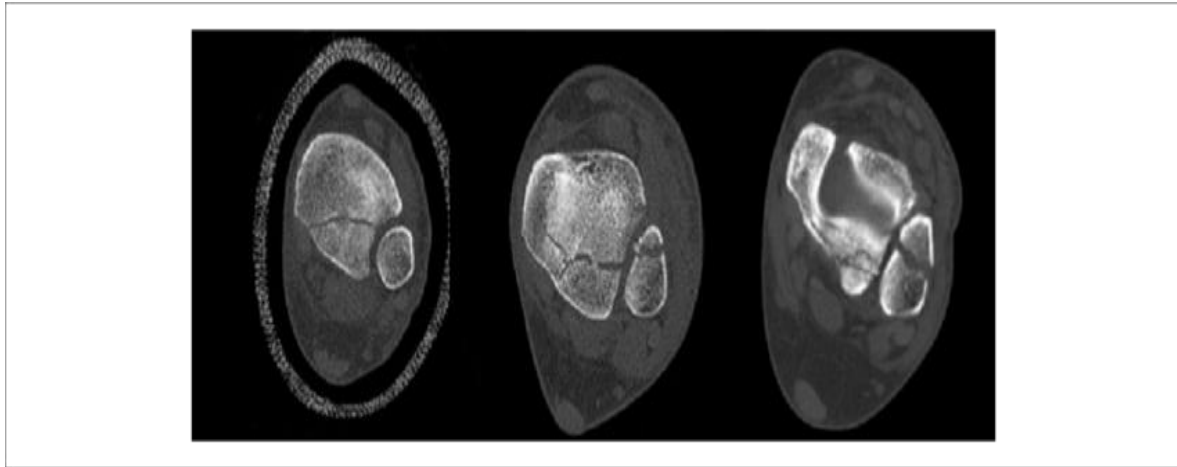


Figure 2: HARAGUCHI classification for posterior malleolus fractures

There were 12 patients with Haraguchi type-I and 8 patients with Haraguchi type-II fractures. We identified 100 patients with ankle fractures. 46 of 60 patients had completed the outcome survey and were analyzed, giving a comparison between 26 bimalleolar fractures and 20 trimalleolar fractures.

Results

Twenty-six (56.5%) of 46 patients still had residual pain. In addition, 29 (63.04%) patients were still complaining of stiffness and 21 (45.7%) patients still had ankle swelling. However, there were no statistical differences in age, gender, residual pain, stiffness, and swelling between the bimalleolar and trimalleolar ankle fractures. Fracture dislocations were more likely to have a trimalleolar fracture pattern (P < .001) (Table-1)

Table 1: Results with bimalleolar and trimalleolar Ankle Fracture

	Bimalleolar Ankle Fracture (n = 26)	Trimalleolar Ankle Fracture (n = 20)
Age	46 years	45 years
Male gender, n (%)	12(46%)	8(40%)
Fracture dislocation, n (%)	-----	9(45%)
Residual pain, n (%)	14(54%)	12(60%)
Residual stiffness, n (%)	15(58%)	12(60%)
Residual swelling, n (%)	12(46%)	11(55%)
Visual analog scale	1.8	2
Mean 1.8 2 .74 Olerud and Molander score	82.1	78.4
Mean satisfaction with surgery, n (%)	24(92)	19(95)

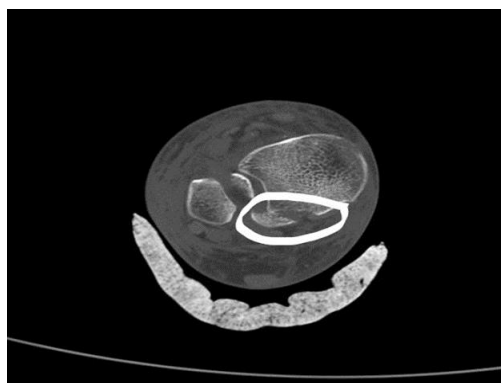
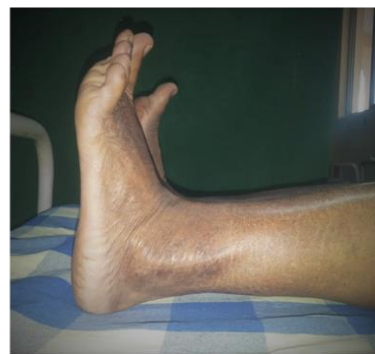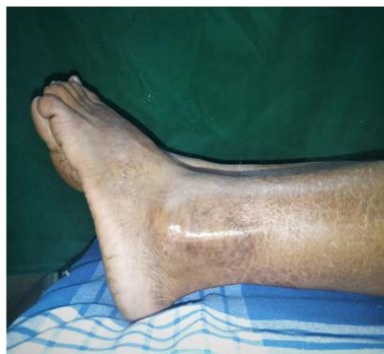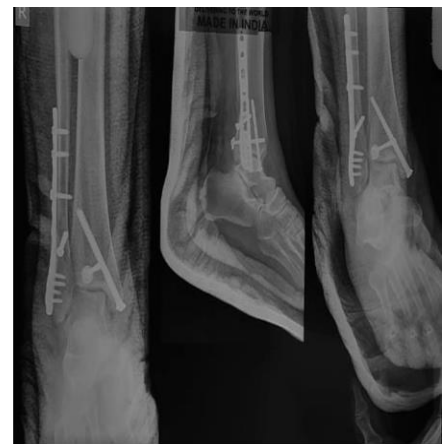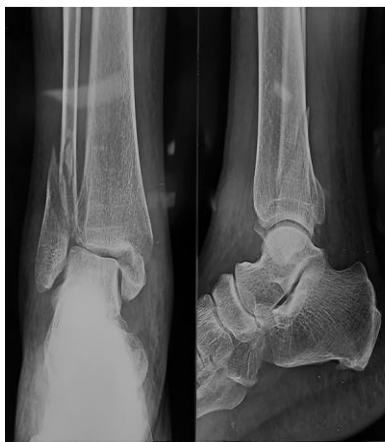In general, the majority of our patients with bimalleolar and trimalleolar ankle fractures achieved good to excellent results post fixation according to the O&M score (mean score 82.1),

and there were no notable differences in the VAS and O&M score for both groups (Table 2). Almost all of our patients, 45 (97.7%), were satisfied with the surgery. All cases achieved union.

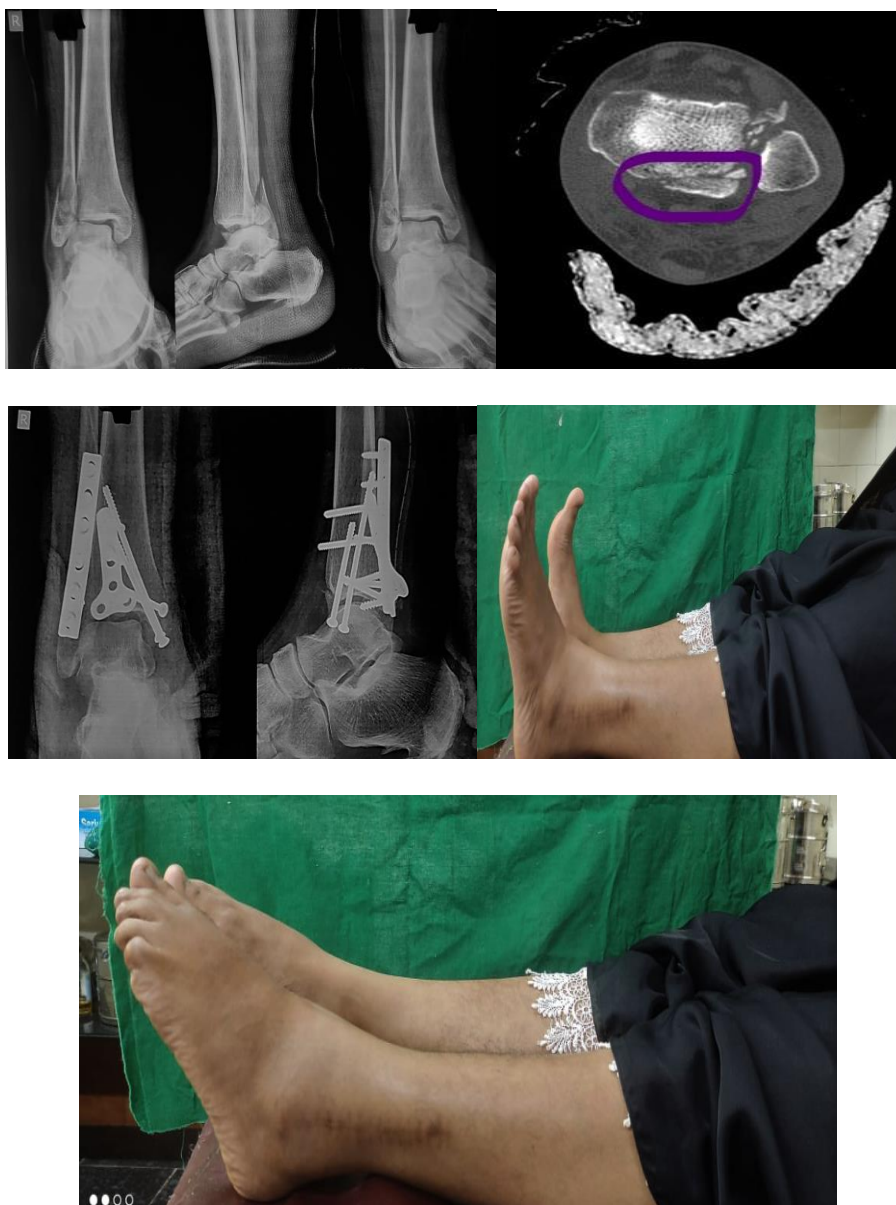Table 2: Results using Olerud and Molander Score: Values are n (%).

Olerud and Molander	Bimalleolar Ankle Fracture (n = 26)	Trimalleolar Ankle Fracture (n = 20)
Excellent (>90)	5 (19.2%)	4 (20%)
Good (61-90)	18 (69.2%)	13 (65%)
Fair (31-60)	3 (11.5%)	3 (15%)

There were no notable complications except for 2 bimalleolar ankle fracture cases and 2 trimalleolar ankle fracture cases with superficial wound infection that resolved following oral antibiotics.



Denis weber type-B tri-malleolar fracture of right ankle. (Case-1)



Discussion

Ankle fractures are among the most common injuries treated in orthopedic surgery today. The incidence of ankle fractures is reported to be around 107 to 184 per 100,000 per year.^{2,4,5} Operative treatment of displaced ankle fractures has been shown to provide results that are better than those of nonoperative treatment.^{1,9} Day et al reported on the long-term outcome of 25 patients with bimalleolar ankle fractures over a 10- to 14-year period that 52% of the patients showed good to excellent results whereas 24% had a poor overall outcome⁶. Similarly, we found approximately half of our patients (57%) experienced pain and 59% of these patients complained of residual ankle stiffness at 1 year postoperatively. Almost 50% of them had persistent ankle swelling. However most of our patients achieved good to excellent functional outcome according to the O&M score. More than 90% of them were also satisfied with the surgical outcome despite some residual symptoms.

Kennedy et al reported that bimalleolar and trimalleolar ankle fractures resulted in poorer outcome compared with unimalleolar ankle fractures in their sample of 107 patients over a 3-year period¹². Limitations of our study include a small cohort of patients and a relatively small number of patients who underwent surgical fixation for their posterior malleolar fracture. Our

study is also retrospective in design. Syndesmosis fixation was not taken as a variable in this study.

Conclusion

Majority of our patients recovered well and were satisfied with the outcome in their second year although there were some residual deficits. Residual ankle pain and stiffness are the most common deficits seen. There was no significant difference in functional outcome between bimalleolar and trimalleolar ankle fractures at an average follow-up of 2 years. Hence it is necessary to counsel patients regarding the postoperative functional recovery prior to surgery. More research is required with the aim of managing this group of patients in an attempt to improve their post-operative function and quality of life.

References

1. Court-Brown CM, McBirnie J, Wilson G. Adult ankle fractures: an increasing problem? *Acta Orthop Scand.* 1990;69: 43-47
2. Bengnér U, Johnell O, Redlund-Johnell I. Epidemiology of ankle fracture 1950 and 1980. Increasing incidence in elderly women. *Acta Orthop Scand.* 1986;57:35-37.
3. Colvin AC, Walsh M, Koval KJ, et al. Return to sports following operatively treated ankle fractures. *Foot Ankle Int.* 2009;30(4):292-296.
4. Belcher GL, Radomisli TE, Abate JA, et al. Functional outcome analysis of operatively treated malleolar fractures. *J Orthop Trauma.* 1997;11(2):106-109.
5. Daly PJ, Fitzgerald RH Jr, Melton LJ, Ilstrup DM. Epidemiology of ankle fractures in Rochester, Minnesota. *Acta Orthop Scand.* 1987;58:539-544.
6. Day GA, Swanson CE, Hulcombe BG. Operative treatment of ankle fractures: a minimum 10-year follow-up. *Foot Ankle Int.* 2001;22(2):102-106.
7. De Vries JS, Wijnman AJ, Sierveit IN, Schaap GR. Longterm results of ankle fractures with a posterior malleolar fragment. *J Foot Ankle Surg.* 2005;44(3):211-217.
8. Egol KA, Dolan R, Koval KJ. Functional outcome of surgery for fractures of the ankle: a prospective, randomized comparison of management in a cast or a functional brace. *J Bone Joint Surg Br.* 2000;82(2):246-249.
9. Egol KA, Tejwani NC, Walsh MG, Capla EL, Koval KJ. Predictors of short-term functional outcome following ankle fracture surgery. *J Bone Joint Surg Am.* 2006;88:974-979.
10. Hartford JM, Gorczyca JT, McNamara JL, Mayor MB. Tibiotalar contact area. *Clin Orthop.* 1995;320:182-187.
11. Jasulka RA, Ittner G, Schedl R. Fractures of the posterior tibial margin: their role in the prognosis of malleolar fractures. *J Trauma.* 1989;29:1565-1570.
12. Kennedy JG, Johnson SM, Collins SL, et al. An evaluation of the Weber classification of ankle fractures. *Injury.* 1998;29:577-580.
13. Lash N, Horne G, Fielden J, Devane P. Ankle fractures: functional and lifestyle outcomes at 2 years. *ANZ J Surg.* 2002;72:724-730.
14. Lin CW, Moseley AM, Refshauge KM. Rehabilitation for ankle fractures in adults. *Cochrane Database Syst Rev.* 2008;(3):CD005595.
15. Macko VW, Matthews LS, Zwirkoski P, Goldstein SA, Arbor A. The joint-contact area of the ankle. *J Bone Joint Surg Am.* 1991;73:347-351.
16. Makwana NK, Bhowal B, Harper WM, Hui AW. Conservative versus operative treatment for displaced ankle fractures in patients over 55 years of age: a prospective, randomised study. *J Bone Joint Surg Br.* 2001;83:525-529.
17. McDaniel WJ, Wilson FC. Trimalleolar fractures of the ankle: an end result study. *Clin Orthop.* 1977;122:37-45.
18. Olerud C, Molander H. A scoring for symptom evaluation after ankle fracture. *Arch*

Orthop Trauma Surg. 1984; 103(3):190-194.

19. Rowley DI, Norris SH, Duckworth T. A prospective trial comparing operative and manipulative treatment of ankle fractures. *J Bone Joint Surg Br.* 1986;68:610-613.
20. Shah NH, Sundaram RO, Velusamy A, Braithwaite IJ. Fiveyear functional outcome analysis of ankle fracture fixation. *Injury.* 2007;38:1308-1312.
21. Tejwani NC, McLaurin TM, Walsh M, et al. Are outcomes of bimalleolar fractures poorer than those of lateral malleolar fractures with medial ligamentous injury? *J Bone Joint Surg Am.* 2007;89:1438-1441.
22. Vioreanu M, Dudeney S, Hurson B, Kelly E, O'Rourke K, Quinlan W. Early mobilization in a removable cast compared with immobilization in a cast after operative treatment of ankle fractures: a prospective randomized study. *Foot Ankle Int.* 2007;28(1):13-19.