

## ORIGINAL RESEARCH

## Functional Outcome of Surgical Management of Diaphyseal Fractures of the Femur with Closed Intramedullary Interlocking Nail: A Prospective Study

Pratheesh Mohanraj<sup>1</sup>, Adhiyamaan R.V<sup>2</sup>, Gopinath G<sup>3</sup>, Ajin Raj<sup>4</sup>, F. Abdul Khader<sup>5</sup>, Rupesh Kanna<sup>6</sup>, Dinesh Ram<sup>7</sup>, Harish. S<sup>8</sup>

<sup>1</sup>Assistant Professor, Department of Orthopaedics, Shri Sathya Sai Medical College & Research Institute, Ammapettai, Chengalpet District – 603108, India.

<sup>2</sup>Assistant Professor, Department of Orthopaedics, Shri Sathya Sai Medical College & Research Institute, Ammapettai, Chengalpet District – 603108, India.

<sup>3</sup>Assistant Professor, Department of Orthopaedics, Shri Sathya Sai Medical College & Research Institute, Ammapettai, Chengalpet District – 603108, India.

<sup>4</sup>Post Graduate, Department of Orthopaedics, Shri Sathya Sai Medical College & Research Institute, Ammapettai, Chengalpet District – 603108, India.

<sup>5</sup>Professor, Department of Orthopaedics, Shri Sathya Sai Medical College & Research Institute, Ammapettai, Chengalpet District – 603108, India.

<sup>6</sup>Post Graduate, Department of Orthopaedics, Shri Sathya Sai Medical College & Research Institute, Ammapettai, Chengalpet District – 603108, India.

<sup>7</sup>Post Graduate, Department of Orthopaedics, Shri Sathya Sai Medical College & Research Institute, Ammapettai, Chengalpet District – 603108, India.

<sup>8</sup>Post Graduate, Department of Orthopaedics, Shri Sathya Sai Medical College & Research Institute, Ammapettai, Chengalpet District – 603108, India.

### ABSTRACT

**Introduction:** One of the most common fractures encountered are the fractures of femoral shaft. Intra-medullary nailing provides speedy recovery, early mobilization and early pre-fracture state achievement and decreased complications. **Objectives:** To determine the outcome of management of closed femoral shaft fractures with Intramedullary Interlocking nailing based on Thorasen B.O., et al score. **Methods and Materials:** 35 inpatients of Department of Orthopaedics, with fracture shaft of femur surgically treated with IMIL nailing selected. A careful history and Informed consent taken from the patient and the attender. Detailed clinical examination done for the patient and decided whether the patient comes under the inclusion criteria. Radiographic evaluation included anteroposterior and lateral radiographs of full length of femur. Patient was subjected to all pre-operative investigations and anaesthetic fitness for surgery. All patients were operated using standard operative guideline and all fractures were fixed with standard AO femoral IMIL nail using closed technique under image intensifier. Follow up was done at 3, 6 and 12 weeks. All fractures were closed fractures. All patients underwent closed IMIL nailing for shaft of femur. 30(85.7%) didn't have any complications, 5(14.3%) had delayed union. Among 35 study subjects, 16(45.7%) had fair outcome and 19(54.3%) had good outcome, based on Thorasen B.O., et al score. **Conclusion:** The treatment of choice for closed diaphyseal fractures of femur in adults with comminution, long spiral, and segmental fractures is closed IMIL nailing of the femur. Advantages being, less complications, reduced hospital stay, excellent to good functional outcome.

**Keywords: Intramedullary interlocking nail (IMIL), Diaphyseal Fractures of Femur, Shaft of Femur**

**Corresponding Author:** Dr. F. Abdul Khader, Professor, Department of Orthopaedics, Shri Sathya Sai Medical College & Research Institute, Ammapettai, Chengalpet District – 603108, India.

**INTRODUCTION**

A fracture is a breach in the structural continuity of the bone cortex, with a degree of injury to the surrounding soft tissues.<sup>1</sup> A significant percentage of bone fractures occur because of high force impact or stress. Many of the fractures are associated with multiple injuries which need emergency care and support.

One of the most common injuries necessitating emergency intervention by orthopaedic surgeon is Fractures of the femoral shaft (FSF). Mainly accompanied with polytrauma and needs emergency intervention. Motor Vehicle Collisions (MVC) i.e., high energy trauma is the most commonly involved mechanism in the young and in the elderly, lower-energy trauma. The most common treatment for physiologically stable patients is intramedullary interlocking nailing (IMIL) and the goal is early healing and long-term functional recovery<sup>2-4</sup>. Proper anatomical alignment and early functional rehabilitation of limb is the main outcome goal of femoral fracture care. Surgery is indicated for most femur fractures.

The gold standard of treatment for femoral shaft fractures is intramedullary interlocking nailing (IMIL). Early treatment reduces pulmonary complications, infection rates, and mortality.<sup>5</sup>

Open Reduction and Internal Fixation (ORIF) is not the primary treatment except in cases of extension to the proximal or distal femur

Injuries requiring external fixation are open fractures, vascular injuries, polytrauma, stabilization for transfer, and those unstable for early definitive care. Negligible consequence on the trauma patient's disease burden occur after application of External fixators.<sup>6,7</sup>

The study was done to determine the functional outcome of Intramedullary interlocking nailing procedure in patients with shaft of femur fractures. The reduction in pain, improvement in physical function, early mobility, ease of mobility and decrease in mobility are aimed in intramedullary inter-locking procedure.

**MATERIALS AND METHODS**

A Prospective Observational study was done after the Institutional Ethical Committee approval and after obtaining informed consent from all the patients. 35 in-patients of the Department of Orthopaedics, Tertiary Care Centre, Chengalpattu district, with shaft of femur fracture, treated with closed Intramedullary Interlocking Nailing.

From all admitted patients, a careful history was taken and informed consent to be taken from the patient and the attender. Detailed clinical examination was done for the evaluation of the patient and then decided whether the patient comes under the inclusion criteria or not. For the study, the inclusion criteria were, Age group >18 years, acute isolated fracture involving the diaphysis of femur, closed fractures or grade I Gustillo-Anderson compound fracture classification, segmental fractures, all comminuted fracture (Winqvist Hansen classification Type I – Type IV) and the exclusion criteria were, Age group <18 years, grade- II, III Gustillo-Anderson compound fracture classification, un-displaced fractures requiring conservative management or patient not willing or medically unfit for surgery.

Radiographic evaluation included anteroposterior and lateral radiographs of the entire femur. Application of traction to the limb during radiographs was done to enhance the view of morphology of the fracture site. Then immobilization was done with Thomas splint and skin

traction was applied. Patient was subjected to all pre-operative investigations and anesthetic fitness for surgery. All patients were operated using standard operative guideline and all fractures were fixed with standard AO femoral intramedullary interlocking nail using closed technique under image intensifier. Follow up was done at 3, 6 and 14 weeks.

The patients were assessed post operatively on the functional outcome based on Thorasen B.O. et.al. (Table 1)

**Table 1: Thorasen B.O. et. al**

<b>Excellent:</b>			
1	Malalignment of the femur (degrees)	Varus or valgus	05
		Internal rotation	05
		Antecurvatum or recurvatum	05
		External rotation	10
2	Shortening of the femur (cms)		01
3	Range of motion of the knee (degrees)	Flexion	> 120
		Extension deficit	05
4	Pain or swelling		None
<b>Good :</b>			
1	Malalignment of femur (degrees)	Varus or valgus	05
		Internal rotation	
		Antecurvatum or recurvatum	10
		External rotation	15
2	Shortening of the femur (cms)		02
3	Range of motion of the knee (degrees)	Flexion	120
		Extension deficit	10
4	Pain or swelling		Sporadic, minor
<b>Fair:</b>			
1	Malalignment of the femur (degrees)	Varus or valgus	10
		Internal rotation	15
		Antecurvatum or recurvatum	15
		External rotation	20
2	Shortening of the femur (cms)		03
3	Range of motion of the knee (degrees)	Flexion	90
		Extension deficit	15
4	Pain or swelling		Significant
<b>Poor:</b>			
1	Malalignment of the femur (degrees)	Varus or valgus	>10
		Internal rotation	>15
		Antecurvatum or recurvatum	>15
		External rotation	>20
2	Shortening of the femur (cms)		>03

3	Range of motion of the knee (degrees)	Flexion	>90
---	---------------------------------------	---------	-----

### Operative Procedure:

Under Spinal / epidural anesthesia, the patients were placed supine on the fracture table with the affected lower limb in traction and adduction. Incision was taken over the tip of the greater trochanter and extended 4 cm proximal. The entry-point for the nail was confirmed under C-arm guidance in both antero-posterior and lateral view & entry was made over the lateral aspect of piriformis fossa at the junction medial wall of greater trochanter with the help of bone awl. The guidewire inserted through the entry point and passed upto the fracture site followed by closed reduction and then across the fracture site. This was further confirmed under C-arm guidance in both the views. The canal then reamed in 1.0mm increments starting from 7mm using flexible/non-flexible intramedullary reamers The IMIL nail was mounted onto the proximal jig. The alignment of proximal jig holes to nail holes confirmed under C-arm before and after insertion. The distal locking bolts were inserted and confirmed in both the views under C-arm guidance. Proximal locking done with the help of the proximal jig and the wound closed in layers.

The standard post-operative protocol was followed with mobilization of the patient.

All the patients were followed up with, clinical and radiological examination at 6 weeks, 14 weeks, 24 weeks and then once in three months.

The data was entered in MS excel sheet and analyzed using SPSS software version 16.

When a Numerical variable is associated with the Numerical variables such as Pearson's correlation test is used after checking for normality.

When a Categorical Variable is associated with a categorical variable, the variables are represented in both by tables and bar diagrams.

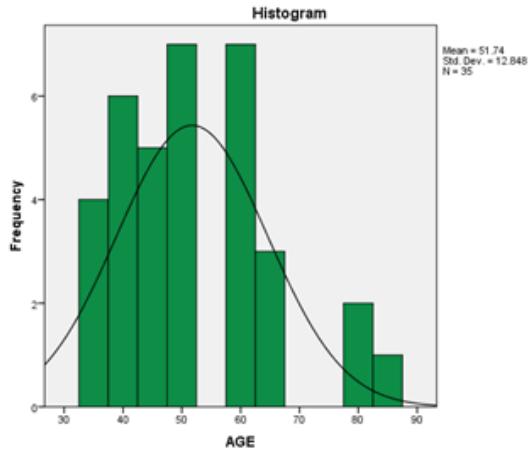
For test of significance, chi-square test is used. Fisher's exact test is used when more than 20% of the cell values had expected cell value less than 5. P-values less than 0.05 were considered statistically significant.

### RESULTS

Amongst 35 patients with closed shaft of femur fractures treated with closed intramedullary interlocking nailing the age distribution among study subjects was as referenced in Table 2 & Figure 1.

**Table 2: Age distribution among study subjects**

Statistics	
AGE	
Mean	51.74
Median	48.00
Mode	48
Std. Deviation	12.85
Minimum	35
Maximum	84



**Figure 1: Age distribution among study subjects**

In our study, 24(68.6%) were males and 11 (31.4%) were females, 23 (65.7%) had history of Road Traffic Accidents, 8 (22.9%) had history of fall from height and 4(11.4%) had history of slip and fall. 31 (88.6%) had no associated injuries, 2 (5.8%) had calcaneum fracture, 1 (2.9%) had distal radius fracture, 1 (2.9%) had humerus shaft fracture. It was found that left side was affected among 15 (42.9%) of study subjects and right side was affected in 20 (57.1%). 15 (42.9%) patients were mobilized on post-operative day 3, 11 (31.4%) on post-operative day 4 and 9 (25.7%) on post-operative day 2. The mean (SD) blood loss among study subjects were 350.54(114.823) ml. The minimum blood loss was 150 ml and maximum were 600 ml, 10(28.5%) of subjects had 9 days of hospital stay, 9(25.7%) had 12 days of hospital stay and 8(22.9%) each had 10 days and 14 days hospitals stay. 15(42.9%) were mobilised on post-operative day 3, 11(31.4%) on post-operative day 4 and 9(25.7%) were mobilised on post-operative day 2. 30(85.7%) didn't have any complications and 5(14.3%) had delayed union.

The Functional outcome was assessed based on union by 14 weeks (Table 3)

**Table 3: Functional outcome by percentage of union by 14 weeks**

FUNCTIONAL OUTCOME	Frequency	Percentage
FAIR (50-75%)	16	45.7
GOOD (75-85%)	19	54.3
Total	35	100.0

The cross tabulation between age and functional outcome for the study is been referenced in Table 4.

**Table 4: Cross tabulation between age and functional outcome**

		Functional outcome		Total
		FAIR (50-75%)	GOOD (75-85%)	
Age group	<50 years	10	11	21
		47.6%	52.4%	100.0%
		62.5%	57.9%	60.0%
	>50 years	6	8	14
		42.9%	57.1%	100.0%
		37.5%	42.1%	40.0%

For the cross tabulation between the age and functional outcome, The Chi-square value was 0.077 and p value was 0.78. Among 21 study subjects with age less than 50 years, 52.4% had good functional outcome and 47.6% had fair functional outcome. Among 14 subjects with >50 years 57.1% had good functional outcome and 42.9% had fair functional outcome. This was not statistically significant (p value: 0.78).

## DISCUSSION

Surgical intervention is necessary in the shaft of femur fractures as these fractures are associated with complications which are related to the immobilization of the patient and delayed weight bearing. Out of the various surgical modalities, the functional outcome with closed intramedullary nailing was studied in this study.

The intramedullary nail can endure twisting and torsional-loads better than plates and the locking-mechanism delivers less-tensile and shear-stress than plates. The intramedullary interlocking nail is less loaded than plates causing less cortical osteopenia of stress shielding, which is a feature of the load-bearing plates. No damage to extra periosteal soft tissue occurs and the biological environment around the fracture is minimally disturbed in closed nailing technique. The chance of early ambulation of the patient which reduces the complications of prolonged bed confinement is high in closed intra-medullary nailing technique.<sup>8-12</sup> Restoration of anatomical length and alignment of comminuted fractures, biological fixation resulting in high union rates, decreased incidence of fatigue, strength for femoral shaft fracture in all three planes of loading-bending, compression, and torsion, early joint mobilization, early-muscle- rehabilitation, shortened-hospital stay, reduced the incidence of complications like infection, cortical osteopenia, malunion, and non-union, and most importantly early return to work and pre-fracture state are the advantages of intra-medullary nailing.<sup>13</sup>

The main objective of the study was to determine the outcome of management of closed femoral shaft fractures with Intramedullary Interlocking nailing based on Thorasen B.O. et al score and to compare the functional outcome of Intramedullary Interlocking nailing in shaft of femur fractures in young age group from 20-50 years and age group 50 years and above.

The preservation of fracture hematoma, using closed technique, early surgical intervention, early mobilization, and early weight bearing are the reasons for high union rates in our study.

**Mahendranath Reddy and Muralidhar B M** found that the surgery was done at an average 3 days ranging from 2 –5 days<sup>14</sup>. Duration of hospital stay was 12 days ranging from 10-15 days. Mean time for union was 20 weeks. In this study it was found that the excellent to good result was seen in 75% of cases among 40 patients with femoral fractures. Similarly, in our study the duration of hospital stay ranged between 9 to 14 days and at the end of 14 weeks among 35 study subjects >85% had excellent outcome, 75-85% had good outcome, 50-75% had fair outcome and <50% poor outcome.

**Deepak et al** showed that the union rate was 86.6%.<sup>13</sup> Five patients had superficial infection, four had shortening of limb, and in two cases union was delayed. Whereas in our study, out of 35 study patients, 5 had delayed union.

**Arun Kumar et al** found that 82.5% of patients had excellent results after treating with Intramedullary Nailing of diaphyseal femur fractures<sup>15</sup>. They found that Closed nailing results in less intraoperative blood loss, shorter operative time, earlier weight bearing, early union rates and early return to work with reduced morbidity compared to open techniques. Similarly, in our study the mean (+/- SD) blood loss among the study subjects was 350.54(114.823) ml.

**Chokotho et al** found that treatment with Intra-Medullary Nailing (IMN) enhanced early quality of life and function and permitted patients to return to work faster in comparison with treatment with Skeletal Traction (ST).<sup>16</sup>

**Ibeanusi SE and J Chioma** did a study to evaluate the pattern of presentation of fractures of the femur among 1334 patients and found that significant majority of cases seen in the age group (21 to 30) years. Most of the fractures were closed (1040, 78%)  $P < 0.00001$ , involving the shaft of the femur (775, 56.1%). Majority of the patients particularly adults were treated by operative methods including open reduction and internal fixation with intramedullary nails (629, 47.2%), plates and screws (206, 15.4%), and K-wires (18, 1.3%), external fixation (176, 13.2%) and amputations ( $n = 5$ , 0.4%).<sup>17</sup>

**Vijaya Kumar** found that maximum number of patients sustained femur fracture due to RTA (42 cases) followed by fall (08 cases) among 50 patients with femoral fractures treated with intramedullary nailing. 32 patients had excellent functional results and 10 patients had good functional outcome, while only 5 patients had fair functional outcome<sup>18</sup>. Similarly in our study, out of 35 cases with closed shaft of femur fractures, treated with closed Intramedullary Interlocking Nailing 16 had fair outcome and 19 had good outcome.

#### **Limitations:**

Smaller sample size, hence the decreased chance of generalizability. Long-term follow-up was not possible.

#### **Recommendations:**

Further studies with increased sample size matched for confounding factors done also in other settings such as primary and secondary care will represent the true nature of findings.

#### **CONCLUSION**

The study was done among 35 patients with closed intra-medullary nailing among diaphyseal femoral fractures to find out the functional outcome and the mean (SD) among study subjects was 51.74(12.85) years, 24(68.6%) were males, 23(65.7%) had history of Road Traffic Accidents. All fractures were closed fractures. All patients underwent closed intramedullary nailing and Intramedullary Interlocking Nail for the femur was used. 30(85.7%) didn't have any complications, 5(14.3%) had delayed union. Among 35 study subjects, 16(45.7%) had fair outcome and 19(54.3%) had good outcome.

#### **REFERENCES**

1. Sheen JR, Garla VV. Fracture healing overview. InStatPearls, Bayram F, Çakıroğlu M. DIFFRACT: DIaphyseal Femur FRACTure Classifier SysTem. Biocybern Biomed Eng. 2016 1;36(1):157–71.
2. Medda S, Unger T, Halvorson J. Diaphyseal Femur Fracture. InStatPearls 2021
3. Denisiuk M, Afsari A. Femoral shaft fractures. InStatPearls 2021.
4. Weiss RJ, Montgomery SM, Al Dabbagh Z, Jansson KÅ. National data of 6409 Swedish inpatients with femoral shaft fractures: stable incidence between 1998 and 2004. Injury. 2009 1;40(3):304-8.
5. Enninghorst N, McDougall D, Evans JA, Sisak K, Balogh ZJ. Population-based epidemiology of femur shaft fractures. J Trauma Acute Care Surg. 2013;74(6):1516–20.
6. Denisiuk M, Afsari A. Femoral shaft fractures. InStatPearls 2021.
7. Diaphyseal Femur Fractures Treatment & Management: Approach Considerations, Nonoperative Therapy, General Principles of Surgical Therapy. 2021.
8. Campbell WC, Canale ST, Beaty JH. Campbell's operative orthopaedics. Philadelphia, PA: Mosby.
9. Wolinsky P, Tejwani N, Richmond JH, Koval KJ, Egol K, Stephen DJG. Controversies in intramedullary nailing of femoral shaft fractures. Instr Course Lect. 2002;51:291–303.
10. Meena RC, Kundnani V, Hussain Z. Fracture of the shaft of the femur: Close vs open interlocking nailing. Indian J Orthop. 2006 (4):243-6.

11. Fadero PE, Alabi S, Adebule GT, Odunubi OO, Yinusa W, Eyesan SU, et al. Locked intramedullary nailing for the treatment of femoral shaft fractures: experience and result in 19 cases. *Niger J Med.* 2008 (2):168–72.
12. Bucholz RW, Heckman JD, Tornetta P, McQueen MM, Ricci WM. Rockwood and Green's fractures in adults. In *Rockwood and Green's fractures in adults 2010* (pp. 1275-1275).
13. Deepak MK, Jain K, Rajamanya KA, Gandhi PR, Rupakumar CS, Ravishankar R. Functional outcome of diaphyseal fractures of femur managed by closed intramedullary interlocking nailing in adults. *Ann Afr Med.* 2012 (1):52–7.
14. Mahendranath RD, Muralidhar BM. A prospective study of surgical management of fracture shaft femur with closed intramedullary interlocking nail. *J. Evol. Med. Dent. Sci.* 2013 2(47):9098-106.
15. Kumar A, Gopala Krishnaiah T, Biju R, Krishnamurthy MO. Study of Outcome of Closed Interlocking Intramedullary Nailing Of Fracture Shaft of Femur in Adults. *J. Evol. Med. Dent. Sci.* (Mar. 2015), PP 48-52
16. Chokocho L, Wu HH, Shearer D, Lau BC, Mkandawire N, Gjertsen JE, Hallan G, Young S. Outcome at 1 year in patients with femoral shaft fractures treated with intramedullary nailing or skeletal traction in a low-income country: a prospective observational study of 187 patients in Malawi. *Acta Orthopaedica.* 2020 91(6):724-31.
17. Ibeanusi SE, Chioma J. Pattern and Outcome of Femoral Fractures Treated in a Regional Trauma Centre in South South, Nigeria. *Int. Arch. Orthop. Surg.* 2019;2(6).
18. Kumar BV. Surgical management of diaphyseal fracture of femur with closed intramedullary interlocking nail. *Int J Res Orthop.* 2019 Sep;5(5):879.