

Penile Fracture - A Study Of Outcome

Kapil Rampal, Harkanwalpreet Kaur, Parampreet Singh, Manish Kumar, Sudhir Khichy.

Introduction.

The first case of penile fracture was documented 10 centuries back by Abul Kasen.[1] Penile fracture is defined as traumatic rupture of corpora cavernosa. It can involve corpora spongiosum and urethra. [2]

Penile fracture occurs commonly after slipping of the erect penis from vagina and hitting the pubis or perineum during sexual intercourse. [3]. The various other causes include over enthusiastic masturbation, falling or rolling onto erect penis and practice of bending erect penis for changing shape or size of penis called as taqaanadan.[4]

The circumstances lead on to the presenting chief complaint of sudden loss of erection with pop up sound, swelling and discoloration with typical eggplant deformity. However, the feeling of embarrassment and social stigma prevents patient from seeking early treatment.

The shaft of penis is composed of three erectile tissues, a pair of corpora cavernosa and one corpus spongiosum. Tunica albuginea composes of outer longitudinal and inner circular layer, it can resist the rupture until intra-cavernous pressure rise to more the 1500mm Hg.[5].Ventrally corpus spongiosum is adjusted in the groove formed by tunica albugina. [6]

The tributaries from the internal pudendal artery are chief supplier of blood to penis. The cavernous artery supplies the erectile tissues of the penis. The venous blood from cavernous spaces is drained by the deep dorsal veins. The superficial group of inguinal nodes drains the lymph from the penial skin, whereas the lymph from intermediate and proximal cavernous drains in the internal iliac nodes and the deep inguinal lymph nodes drains the glans of the penis. [7]

SIGNS AND SYMPTOSM

- Sudden loss of erection with severe pain.
- Popping or cracking sound.
- Aubergine sign – deviation of penis to opposite side of the injury.
- Penile ecchymosis and swelling.
- Hematuria.
- Dysuria.

Diagnosis

An appropriate clinical examination and history is necessary for the diagnosis of penile fracture. The patient presents with sudden loss of erection with popping sound, on examination penis is swollen, tender and would be deviated to opposite of side of injury. Depending on severity of the injury, single corporal or both along with corpus spongiosum may be involved.

In about one third of the cases urethral injury has been observed, which usually partial disruption of the urethra is. (8) Various investigation like ultrasound, magnetic resonance, retrograde urethrography and angiography may be helpful in making the diagnosis.

MANAGEMENT

Initially ice packs, Foley's catheterization and anti – inflammatory drugs were considered as standard management of the penile fracture. This conservative management was associated with relative high morbidity rate and patient would land up in various complication like painful erection, arterio–venous fistulas, abscess formation and even impotence.(9] . Because of high morbidities associated with conservative approach, immediate surgical exploration is the necessity.

Surgical exploration is done usin. The defect in the tunica albuginea is repaired using absorbable suture like 3-0 or 2-0 vicryl round body. During Postoperative period patient receives supportive treatment in form antibiotic, anti-inflammatory and sedative agents. Patients can be discharged after 24-36 hours and sexual activity can be resumed after 30-45 days.

In this study we aim to assess the outcome in terms of sexual function after surgical management of the cases.

Materials and methods.

We conducted a retrospective study and evaluated the records for all the case of penile fracture who presented to our department over last 5 years. Patients were contacted telephonically and then physically examined in hospital OPD.

Case 1

A 30 year male presented to emergency department with history of penile injury 3 hours post coitus. Patient gave history of slippage of penis out vagina while having rough sexual intercourse. Patient was vitally stable, penis was edematous and showed typical eggplant appearance whereas defect was not palpable. Surgical exploration revealed hematoma of size 2x2 cm and transverse defect 1x1 cm over right tunica albuginea. Hematoma was drained and defect was closed by 3-0 vicryl suture. Postoperatively patient had uneventful course. During follow up for 6 months patient reported normal erectile function.



Figure 1: Clinical view of Penile Fracture

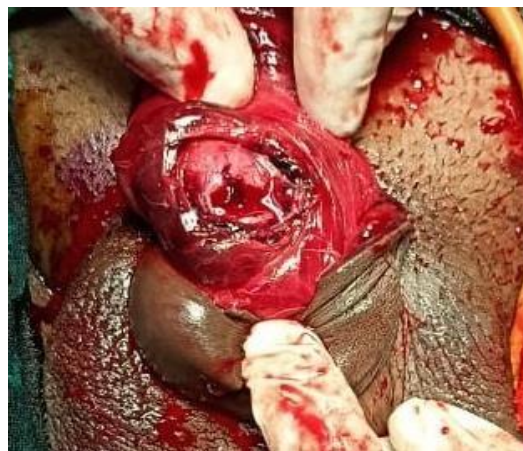
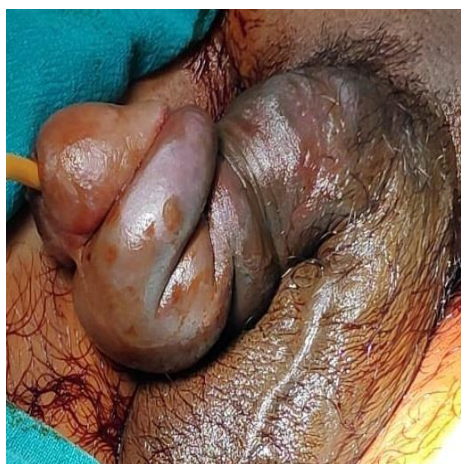
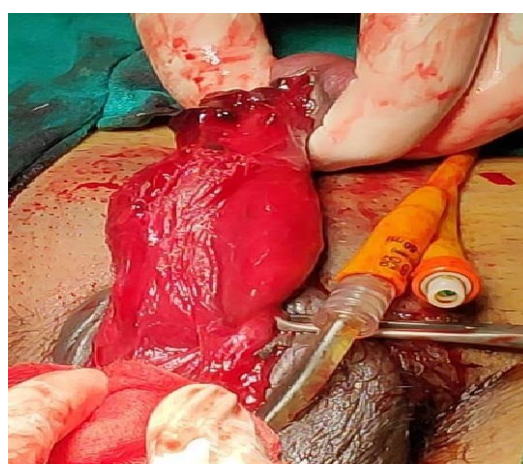
Figure 2: Defect in tunica albuginea

Case 2

A 32 year male presented to emergency department with eggplant deformity of penis following rough sexual intercourse. Patient reported to emergency after 24 hour of injury. Surgical exploration revealed 2x1.5 cm transverse defect on bilateral the tunica albuginea. The defects were repaired with 3-0 vicryl suture. Patient gained erectile functions after 20 days of surgery, that was painful to start but normalized at the end of 1 month.



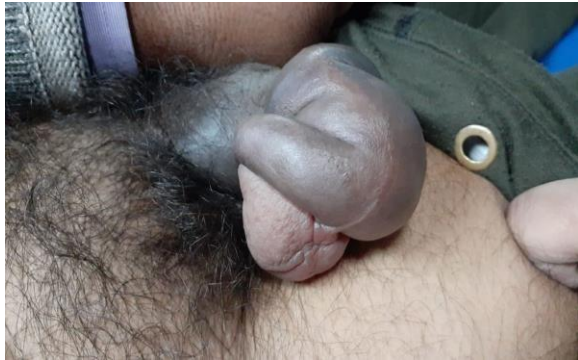**Figure 3: Eggplant deformity
hematoma**



**Figure 4: Transverse defect in tunica albuginea with
hematoma**

Case 3

A 31 year male presented to emergency department with penile injury following vigorous sexual act. Patient reported after 6 hours of the injury. The diagnosis of penile fracture was made clinically and went surgical exploration by degloving incision and transverse defect of size 2x1 cm was repaired with 3-0 vicryl suture over left tunica albuginea. Postoperative period was uneventful. Patient had normal erectile function during follow up.



**Figure 5: Deformed Penis
Albuginea**

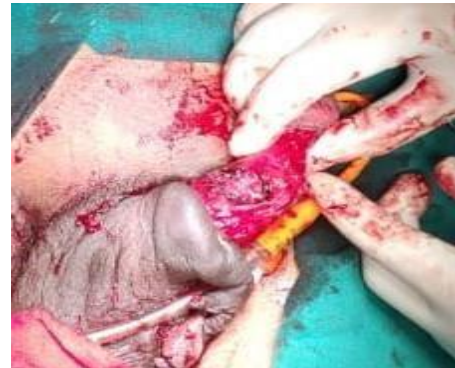
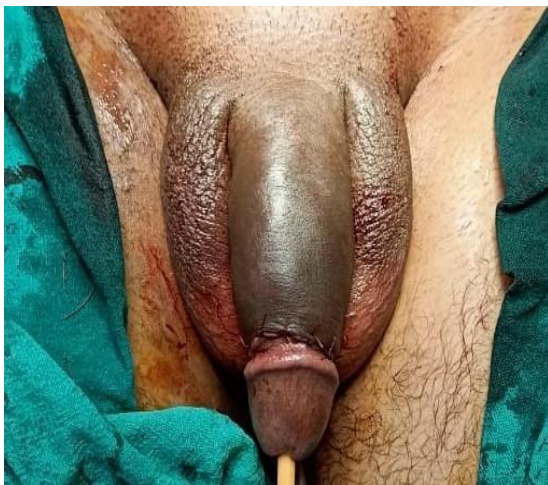
Figure 6: Transverse defect in Tunica

Case 4

A 60 years old male presented to emergency department after 2 weeks of penile injury. Patient was vitally stable and penis was edematous with classical eggplant deformity. After clinically diagnosing the penile fracture, patient received surgically intervention. The transverse defect over left tunica albuginea of size 1x1cm was repaired using 3-0 vicryl. Postoperatively patient had wound infection which was managed with regular aseptic dressing and antibiotics. Patient had normal erectile function during 6 months follow.



**Figure 7: Repaired Coronal incision
Dressing**

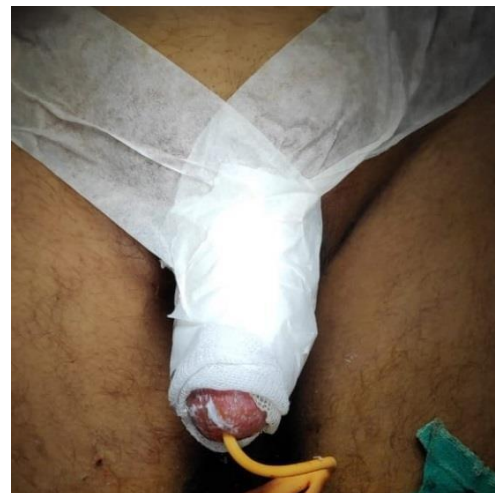


Figure 8: Postoperatively after Antiseptic

Case 5

A 29 year male presented to emergency department after 12 hours of penile injury following vigorous sexual practice. On examination patient was vitally stable and penis was swollen with deviation to opposite of the injury. Diagnosis was made clinically and on surgical exploration by degloving incision revealed transverse defect of size 1x1 cm on left side which was repaired by 3-0 vicryl. Postoperative period was uneventful. Patient had normal sexual and erectile function during 6 months of follow.

Case 6

A 19 year male presented to emergency department after 4 hours of penile injury following over enthusiastic masturbation. Patient was vitally stable and went under surgical exploration, defect of size 2x1cm on right tunica albuginea which was repaired with 3-0 vicryl. Postoperative period was uneventful and had normal erectile function during follow of 6 months.

Case 7

A 24 year old male reported to emergency department after 5 hours of penile trauma following sexual intercourse. On examination penis was swollen with typical eggplant deformity. Surgical exploration revealed defect 2x1 cm over left tunica albuginea which repaired with vicryl 3-0. Patient had uneventful postoperative period and had normal erectile function during 6 month of follow.

Results

The mean age of the patients was 36.4 years and following observation were derived.

Cases	Mode	Side	Time of presentation	Time from presentation to surgery	Hospital stay	Erection on day 10	Erection on day 30	Erection on day 180
1	Sexual intercourse	Right	3 hours	2 hours	3 days	Present	Present	Present
2	Sexual intercourse	Bilateral	24 hours	3 hours	4 days	Absent	Present	Present
3	Sexual intercourse	Left	6 hours	2.5 hours	3 days	Present	Present	Present
4	Sexual intercourse	Left	2 days	3.5 hours	5 days	Absent	Present	Present
5	Sexual intercourse	Left	12 hours	2 hours	3 days	Absent	Present	Present
6	Masturbation	Right	4 hours	1 hour	3 days	Present	Present	Present
7	Sexual intercourse	Left	5 hours	1.5 hour	4 days	Present	Present	Present

The mean time of presentation and time to surgery were 14 hours and 2.2 hours respectively. Whereas the average hospital stay was 3.5 days.

57% of the patient had normal erectile function on day 10 of surgery whereas 100 % had normal erectile function on day 30 and 180 following surgery.

Discussion

Penile fracture is a surgical emergency that is rarely encountered by the general surgeon. It challenges that patient both physiologically and psychologically. The feeling of embarrassment and social stigma associated with injury delays the treatment which hence result in increased morbidity. Cummings et al reported that delay of 28-48 hours in treatment does not effects adversely the outcome of the disease.(10)

Penile fracture may involve one or both corpus cavernosum along with the corpus spongiosum. It may also associated with urethral injury. The incidence of urethral injury in the penile fracture is higher in Europe and United States as compared to Asia and Middle East. The diagnosis of penile fracture can be easily made by clinical history and clinical examination, radiological examination like color Doppler, MRI, angiography may aid the diagnosis. The treatment of choice is urgent surgical exploration with evacuation of hematoma and repair of the tunica albugenia.(11). Postoperatively various studies demonstrate different percentage of complication. Chung CH et al reported 3 out of 11 patient had erectile dysfunction and one had mild deformity.[12]. Where as in our study all the patient were able to gain erectile function and 1 out of 5 had wound infection which was managed by antibiotics and regular dressing .

Conclusion

Penile fracture is rare surgical emergency that challenges the patient both socially and mentally. The appropriate history and clinical examination are definitive for diagnosis. Early surgical intervention is key to better outcome.

1. Taha SA, Sharayah A, Kamal BA, Salem AA, Khwaja S. Fracture of the penis: surgical management. *Int Surg.* 1988;73(1):63-64.
2. Eke N. Fracture of the penis. *Br J Surg.* 2002;89(5):555-565.
3. Orvis BR, McAninch JW. Penile rupture. *Urol Clin North Am.* 1989;16(2):369-375.
4. Majzoub AA, Canguven O, Raidh TA. Alteration in the etiology of penile fracture in the Middle East and Central Asia regions in the last decade; a literature review. *Urol Ann.* 2015;7(3):284-288.
5. Morey AF, Dugi DD. Genital and lower urinary tract trauma. *Campbell Walsh urology.* 10th edition. Saunders: 2012;2507-2508.
6. Lue TF, Zeineh SJ, Schmidt RA, Tanagho EA. Neuroanatomy of penile erection: its relevance to iatrogenic impotence. *J Urol.* 1984;131(2):273-280.
7. Sam P, LaGrange CA. Anatomy, Abdomen and Pelvis, Penis. In: *StatPearls.* Treasure Island (FL): StatPearls Publishing; 2021.
8. Nicolaisen GS, Melamud A, Williams RD, McAninch JW. Rupture of the corpus cavernosum: surgical management. *J Urol.* 1983;130(5):917-919.
9. Wespes E, Libert M, Simon J, Schulman CC. Fracture of the penis: conservative versus surgical treatment. *Eur Urol.* 1987;13(3):166-168.
10. Cummings JM, Parra RO, Boullier JA. Delayed repair of penile fracture. *J Trauma.* 1998;45(1):153-154.
11. Devendra P, Rampal K, Ali I, Rangera M, Chaurasia S, et al. Penile fracture and its management. *Int Surg.* 2016;3(4):1714-1717.

12. Chung CH, Szeto YK, Lai KK. 'Fracture' of the penis: a case series. Hong Kong Med J. 2006;12(3):197-200.