

## “SCAPHOID A WICKED CROOK-WHETHER TO OPERATE/NOT” FUNCTIONAL OUTCOME OF PERCUTANEOUS FIXATION OF SCAPHOID FRACTURES WITH HERBERT SCREWS

Samir Dwidmuthe<sup>1</sup>, Amey S Sadar<sup>2</sup>, Suhas Aradhya, Bhikshavarthimath<sup>3</sup>, M Harsha Vardhan Reddy<sup>4\*</sup>, Mainak Roy<sup>5</sup>, Deepanjan Das<sup>6</sup>

<sup>1, 2,3,4\*,5,6</sup> Department of Orthopaedics, All India Institute of Medical Sciences, Nagpur

\*Corresponding author: M Harsha Vardhan Reddy

\*Department of Orthopaedics, All India Institute of Medical Sciences, Nagpur

### Abstract:

**Background:** Scaphoid waist fractures make up 66% of scaphoid fractures and are mostly nondisplaced. Treatment of nondisplaced scaphoid waist fractures has evolved from conventional cast immobilization to percutaneous screw insertion.

**Methodology and results:** In this study, we assess the clinical and radiologic outcomes of volar percutaneous screw fixation for 20 type B2 scaphoid fractures (according to the Herbert and Fisher classification). All patients were followed for an average of 11 months (range, 6-18 months). All fractures achieved radiographic union at an average of 8.5 weeks (range, 7-12 weeks), requiring no additional procedures. No patients exhibited X-ray indications of osteoarthritis, osteonecrosis of the scaphoid, or complications related to the hardware. In cases of scaphoid waist fractures without collapse, percutaneous screw fixation yielded favourable outcomes, including a high union rate, prompt restoration of function, and minimal complications.

**Conclusion:** Percutaneous fixation of acute, nondisplaced scaphoid fractures is a safe, effective technique that minimizes the need for long-term wrist immobilization, allows an expeditious return to vocational activity, and results in reliable rates of union.

**Keywords:** scaphoid waist fracture, percutaneous osteosynthesis, non-displaced, minimally displaced

### Introduction:

The scaphoid bone is the most commonly fractured carpal bone, accounting for 50% to 80% of all carpal bone fractures and approximately 11% of all hand fractures. Scaphoid fractures are most common in young active athletic between the ages of 15 and 40(1,2). Approximately 80% of these fractures occur at the scaphoid waist. The Herbert and Fisher classification has been used most frequently to describe scaphoid fractures (3).

The treatment options for non-displaced scaphoid waist fractures include cast stabilization and percutaneous screw osteosynthesis.

These fractures are usually considered stable and have a tendency to heal with conservative treatment. Immobilization in a thumb spica cast for 8 to 12 weeks is the most common treatment; However, this may be rejected, Among the reasons for this is that, the plaster cast remains in place for an extended period, delaying a return to sports and other activities. The patient group is primarily young active population desiring to participate in professional or sports-related activities or for social reasons. Moreover, cast immobilization has disadvantages such as stiffness and decreased hand grip (4).

As an alternative to conservative treatment, percutaneous screw fixation has gained popularity. Percutaneous screw fixation of the scaphoid was first reported by Strelly (5) in 1970. It allows for more rapid return to work and sports activities. This technique avoids devascularization of the scaphoid and division of the carpal ligaments and provides a much more aesthetic scar (1,6,7). Potential points of entry for fixation devices are limited by approximately 80% of the surface of the scaphoid bone being covered with articular cartilage. An additional constraint is the boat shape of the scaphoid,

requiring special skills on the part of the surgeon to manoeuvre a wire or a fixation device along the true central axis of the scaphoid (8).

In this study, we present the results for a homogeneous sample of patients with type B2 fractures treated with percutaneous screw fixation, highlighting technical details and outcomes.

### **Materials and Methods:**

We treated 20 patients with scaphoid fractures using the percutaneous scaphoid fixation technique with prior information and consent. There were 17 men and 3 women with a mean age of 28 years (range, 17-40 years). There were 13 scaphoid fractures on the right side and 7 on the left side. Mechanisms of trauma were fall on outstretched hands for 18 patients and road traffic accident for 2 patients. Mean time from injury to surgery was 2 weeks (range, 6 days to 3 weeks). Plain radiographs revealed the Scaphoid fractures with complete fracture configuration. A computed tomography (CT) scan is strongly recommended if a percutaneous procedure is planned.

During the intraoperative procedure, the patient was positioned lying on their back with the affected upper limb extended at a 90° angle and the operative hand secured on a radiolucent arm board. General anaesthesia was administered, and a pneumatic tourniquet was applied. The wrist was set in a hyperextended position with maximum ulnar deviation. Using fluoroscopy, the central axis of the scaphoid was identified in both the front and side views. Along this axis, a guidewire was carefully positioned on the skin. The wrist's hyperextension, ulnar deviation, and thumb traction were employed to aid in fracture reduction.

Under the guidance of an image intensifier, a 0.5-cm incision was made at the most distal radial aspect. Blunt dissection exposed the distal pole of the scaphoid. A 1.1-mm percutaneous guidewire was then carefully introduced into the scaphoid, avoiding any bending. The wire was directed at a 45° angle dorsally and 45° angle medially, aligning with the mid-axis of the scaphoid in both anteroposterior and lateral planes. The guidewire's length within the scaphoid was determined using a depth gauge. A drill, guided to protect soft tissues, was used to create a track for the screw.

Achieving central screw placement is crucial for biomechanical stability but demands a high level of technical skill. A self-tapping, 3-mm Herbert screw was inserted under intensifier control, and the wire was removed. Compression was confirmed through image intensifier imaging. The screw's end was buried beneath the distal surface of the scaphoid to minimize damage to the scaphotrapezium joint. In most cases, a 20-mm screw was sufficient, although in some complete fracture configurations, an 18- or 22-mm screw was used.

### **Postoperative Care:**

Patients received a volar thumb slab splint for approximately 2 weeks following the operation. During the initial postoperative days, individuals were instructed to elevate the treated limb to manage swelling. Nonsteroidal anti-inflammatory drugs and pain medications were prescribed for swelling and pain control, respectively. At the 2-week postoperative follow-up, active wrist range of motion exercises and hand grip exercises were initiated, with the precaution to avoid lifting heavy weights. Subsequent follow-up visits took place every 4 weeks. During each visit, radiographs were taken to assess the progress of fracture healing. The duration of follow-up was contingent on both radiographic evidence of fracture healing and clinical outcomes.

### **Functional Outcome:**

In this study, we utilized the modified Mayo wrist score (9) to assess outcomes. Fractures were deemed consolidated when follow-up radiographs in all planes displayed significant trabeculation spanning the fracture, accompanied by the absence of pain. Union was successfully attained in every case. The duration for a return to work varied between 18 to 40 days, contingent on the patient's occupation, while the resumption of sports activities ranged from 49 to 70 days. The primary cause of the delay was the necessity for radiological confirmation of fracture union. All patients achieved

full flexion, extension, and ulnar deviation within 6 weeks, and radial deviation matched that of the unaffected side after 3 months for 12 patients and after 4 months for 3 patients.

(Figure 3).

Mean power grip was 90% of the contralateral hand at 6 weeks, and 98% at 3 months. Pinch grip rapidly returned to normal, with the mean value being equal to the contralateral side at 3 months. In this study, the average postoperative modified Mayo score was 98 (range, 95- 100) Postoperative complications such as wound infection, reflex sympathetic dystrophy, scar pain, hypertrophy, hardware failure or loosening, mal-union, or avascular necrosis were not observed.

### **Radiologic Outcome:**

All patients had consolidated fractures. Radiographs showed that the screw was in a central position within the scaphoid in 16 patients but somewhat peripheral in 4 patients.

In every instance, the screw effectively spanned the fracture, and there were no instances of migration or loosening observed. Fracture union was seen at a mean of 57 days (range, 35-70 days). There has been no radiographic evidence of scapholunate instability or osteo arthritis at the site of screw insertion and none of the screws has been removed.

### **Discussion:**

There is a lack of agreement among scientists on the optimal surgical approach for treating acute non-displaced scaphoid waist fractures. However, the rise of minimally invasive percutaneous procedures has led to a shift towards the operative management of these fractures, particularly in cases where the displacement is minimal or non-existent.

Arora et al. (10) and Bond et al. (11) reported that the mean time to fracture union with percutaneous screw fixation was six to seven weeks, but with cast immobilization this time increased to eleven to twelve weeks. Dinkar et al. reported that all fracture cases treated by percutaneous fixation achieved union within 8.75 weeks (range, 6-12 weeks) [12]. In this study, we found the mean time to union with percutaneous screw fixation was 8.5 weeks (range, 7-13 weeks). Naranje et al. [13] reported a 100% union rate with percutaneous Herbert screw fixation in 32 patients; we observed a similar result in this study with percutaneous screw fixation.

Bone healing occurs more quickly and postoperative immobilization is shorter with percutaneous fixation than with non-operative treatment. Percutaneous (minimally invasive) treatment has the advantages of internal fixation without the disadvantages of a wide surgical approach; the palmar ligament complex and local vascularity are preserved, while reflex sympathetic dystrophy, painful scar, and postoperative immobilization are avoided (14). Union was obtained in all patients at a mean of 8.5 weeks (range, 7-13 weeks). The range of movement after union was equal to that of the contralateral limb, and grip strength was 98% of the contralateral side at 3 months. Patients were able to return to their activities as early as 3 weeks.

Central screw placement is crucial step in percutaneous fixation, there are 2 screw portals—volar and dorsal. The volar approach might be preferred because the entry point to the bone can be detected more easily, there is little risk of damaging the radiocarpal joint and the extensor tendons, the fracture is usually stabilized in extension, and there is often no need for additional maneuvers. Moreover, the volar approach may be preferable for fractures located close to the distal pole, while the dorsal approach may be preferable for proximal fractures. During the dorsal approach, the extensor tendon of the thumb and index finger and posterior interosseous nerve are at risk. During the volar approach, the superficial palmar arch and the recurrent branch of the median nerve may be injured. Use of a mini- incision to avoid anatomical risks has been suggested (15). According to Polsky et al(16) and Jeon et al(17) there was no statistically significant difference in clinical outcomes, union times, and gripping and pinching strengths between patients treated with the dorsal vs the volar approach. In the current study, all cases were fixed through the volar approach. This seemed to be easier because all fractures were around the scaphoid waist.

In our present research, the volar approach was exclusively employed for fixing all cases, a choice facilitated by the fact that all fractures were concentrated around the scaphoid waist. When it comes to placing screws on the volar side, there is ongoing debate regarding whether to go through the trapezium or avoid it. Opting for the trapezium provides a biomechanical advantage, especially when compared to placing screws centrally in only the proximal pole. However, this technique may lead to scapho-trapezium joint damage, so an entry point avoiding this joint is preferable (18). Regarding the use of the percutaneous technique for the treatment of recent and delayed scaphoid waist fractures, Wozasek and Moser (19) described 25 cases with delayed union and 8 with established nonunion that were treated using a percutaneous dorsal approach. Bony healing was achieved in 81.8% after a mean of 82 months. However, the current authors agree with others (2022) that it seems logical to use an open technique for the treatment of delayed scaphoid fractures because a bone graft is routinely required.

Furthermore, there is ongoing discussion about the selection of screws for fixation. Various options, including Herbert screws, headless compression screws, 3.5-mm cannulated screws, and Acutrak screws from Acumed in Hillsboro, Oregon, have been considered and employed. Shaw (23) and Rankin et al (24) showed that there were greater compression forces with the cannulated screw, but accepted the biological advantages of the headless Herbert screw, which can be buried within the scaphoid without disrupting its bony architecture. Newport et al (25) found better compression with the Herbert screw. The Acutrak screw is a headless, tapered, self-tapping, and fully threaded device designed to provide interfragmentary compression. The Acutrak screw may therefore have some of the advantages of the Herbert screw in being headless, having a variable pitch, and also providing improved interfragmentary compression. Adla et al (26) found no significant difference in compressive effects between the Herbert screw and the Acutrak screw. However, there is general agreement that central screw placement determines fixation and compression.

In the current study, all 20 patients were treated with Herbert screw and the volar approach, with a union rate of 100% achieved. The average postoperative modified Mayo score was 98 (range, 95-100). There were no recorded complications. Others who used the same technique of fixation (ie, Ledoux et al (27) for 23 patients, Inoue and Shionoya (28) for 40 patients, and Brutus et al (29) for 30 patients. The major limitations of the current study were the small number of patients and the lack of a control group. The results cannot be compared with those of other treatment modalities, including dorsal percutaneous fixation, open reduction, or conservative treatment, did not evaluate cost effectiveness, occupation of individuals. Nevertheless, volar percutaneous screw fixation for scaphoid fractures (type B2) seems to be a reasonable treatment option, offering an excellent union rate in a short time and a low complication rate with good functional outcome.

### **Conclusion:**

Percutaneous screw fixation of scaphoid fractures has gained popularity due to improved instrumentation, low morbidity, and excellent results. The disadvantages of a long period of cast immobilization are avoided, and this technique allows a more rapid return to work and sports activities than conservative treatment. Consequently, percutaneous screw fixation is appealing for the young, active population.

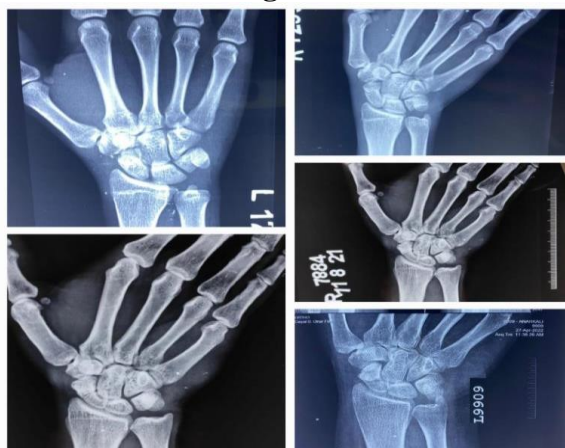### **References:**

1. Evans S, Brantley J, Brady C, Salas C, Mercer D. Structures at risk during volar percutaneous fixation of scaphoid fractures: a cadaver study. Iowa Figure 6: Scaphoid radiograph 3 months postoperatively showing complete union. *Orthop J*. 2015; 35:119-123.
2. Weinberg AM, Pichler W, Grechenig S, Tesch NP, Heidari N, Grechenig W. The percutaneous antegrade scaphoid fracture fixation: a safe method? *Injury*. 2009; 40(6):642-644.
3. Herbert TJ, Fisher WE. Management of the fractured scaphoid using a new bone screw. *J Bone Joint Surg Br*. 1984; 66(1):114-123.

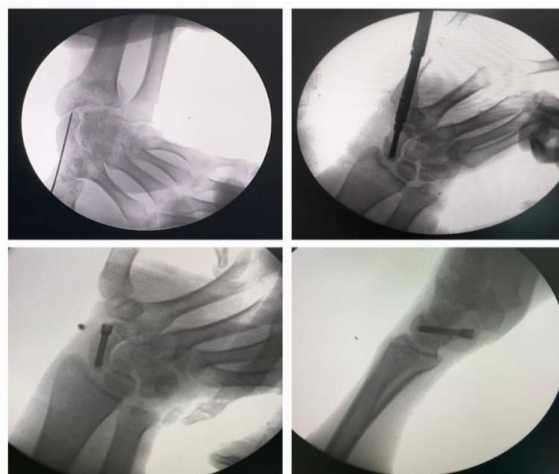
4. Cooney WP, Dobyns JH, Linscheid RL. Fractures of the scaphoid: a rational approach to management. *Clin Orthop* JULY/AUGUST 2017 | Volume 40 • Number 4 e73n tips & techniques *Relat Res.* 1980; 149:90-97.
5. Strelt R. Percutaneous screwing of the navicular bone of the hand with a compression drill screw (a new method) [in German]. *Zentralbl Chir.* 1970; 95(36):1060-1078.
6. Hegazy G. Percutaneous screw fixation of scaphoid waist fracture non-union without bone grafting. *J Hand Microsurg.* 2015; 7(2):250-255.
7. Gehrman SV, Grassmann JP, Wild M, et al. Treatment of scaphoid waist fractures with the HCS screw. *GMS Interdiscip Plast Reconstr Surg DGPW.* 2014; 3:Doc 10.
8. Smith EJ, Ellis RE, Pichora DR. Computer-assisted percutaneous scaphoid fixation: concepts and evolution. *J Wrist Surg.* 2013; 2(4):299-305.
9. Cooney WP, Bussey R, Dobyns JH, Linscheid RL. Difficult wrist fractures. Peri lunate fracture dislocations of the wrist. *Clinical Orthopaedics and Related Research.* 1987 Jan 1(214):136-47.
10. Arora R, Gschwentner M, Krappinger D, Lutz M, Blauth M, Gabl M. Fixation of nondisplaced scaphoid fractures: making treatment cost effective. Prospective controlled trial. *Arch Orthop Trauma Surg.* 2007 Jan;127(1):39-46. doi: 10.1007/s00402-006-0229-z. Epub 2006 Sep 27. PMID: 17004075.
11. Bond CD, Shin AY, McBride MT, Dao KD. Percutaneous screw fixation or cast immobilization for nondisplaced scaphoid fractures. *J Bone Joint Surg Am.* 2001 Apr;83(4):483-8. doi: 10.2106/00004623-200104000-00001. PMID: 11315775.
12. Smith BS, Cooney WP. Revision of failed bone grafting for non-union of the scaphoid: treatment options and results. *Clin Orthop Relat Res.* 1996; 327:98-109
12. Dinkar K, Kapoor R, Verma A, Dwivedi S, Patel J, Verma A. Comparison between functional outcome of scaphoid fracture treated by open reduction internal fixation vs percutaneous fixation. *Indian J Orthop.* 2021;7:267-72.
13. Naranje S, Kotwal PP, Shamsery P, Gupta V, Nag HL. Percutaneous fixation of selected scaphoid fractures by dorsal approach. *Int Orthop.* 2010 Oct;34(7):997-1003. doi: 10.1007/s00264009-0891-1. Epub 2009 Nov 10. PMID: 19902210; PMCID: PMC2989038.
14. Majeed H. Nonoperative treatment versus percutaneous fixation for minimally displaced scaphoid waist fractures in high demand young manual workers. *J Orthop Traumatol.* 2014; 15(4):239-244.
15. Gürbüz Y, Kayalar M, Bal E, Toros T, Küçük L, Sığün TS. Comparison of dorsal and volar percutaneous screw fixation methods in acute Type B scaphoid fractures. *Acta Orthop Traumatol Turc.* 2012; 46(5):339-345.
16. Polsky MB, Kozin SH, Porter ST, Thoder JJ. Scaphoid fractures: dorsal versus volar approach. *Orthopedics.* 2002; 25(8):817-819.
17. Jeon IH, Micic ID, Oh CW, Park BC, Kim PT. Percutaneous screw fixation for scaphoid fracture: a comparison between the dorsal and the volar approaches. *J Hand Surg Am.* 2009; 34(2):228-236.
18. Meermans G, Van Glabbeek F, Braem MJ, van Riet RP, Hubens G, Verstreken F. Comparison of two percutaneous volar approaches for screw fixation of scaphoid waist fractures: radiographic and biomechanical study of an osteotomy-simulated model. *J Bone Joint Surg Am.* 2014; 96(16):1369-1376. 102.
19. Wozasek GE, Moser KD. Percutaneous screw fixation for fractures of the scaphoid. *J Bone Joint Surg Br.* 1991; 73(1):138-142.
20. Iacobellis C, Baldan S, Aldegheri R. Percutaneous screw fixation for scaphoid fractures. *Musculoskelet Surg.* 2011; 95(3):199-203.
21. Chen AC, Chao EK, Hung SS, Lee MS, Ueng SW. Percutaneous screw fixation for unstable scaphoid fractures. *J Trauma.* 2005; 59(1):184-187.

22. McQueen MM, Gelbke MK, Wakefield A, Will EM, Gaebler C. Percutaneous screw fixation versus conservative treatment for fractures of the waist of the scaphoid. *J Bone Joint Surg Br.* 2008; 90(1):66-71.
23. Shaw JA. A biomechanical comparison of scaphoid screws. *J Hand Surg Am.* 1987; 12(3):347-353.
24. Rankin G, Kuschner SH, Orlan- do C, McKellop H, Brien WW, Sherman R. A biomechanical evaluation of a cannulated com- pressive screw for use in fractures of the scaphoid. *J Hand Surg Am.* 1991; 16(6):1002-1010.
25. Newport ML, Williams CD, Bradley WD. Mechanical strength of scaphoid fixation. *J Hand Surg Br.* 1996; 21(1):99
26. Adla DN, Kitsis C, Miles AW. Compression forces generated by mini bone screws: a compar- ative study done on bone model. *Injury.* 2005; 36(1):65-70.
27. Ledoux P, Chahidi N, Moermans JP, Kinnen L. Percutaneous Herbert screw osteosynthesis of the scaphoid bone [in French]. *Acta Orthop Belg.* 1995; 61(1):43-47.
28. Inoue G, Shionoya K. Herbert screw fixation by limited access for acute fractures of the scaph- oid. *J Bone Joint Surg Br.* 1997; 79(3):418-421.
29. Brutus JP, Baeten Y, Chahidi N, Kinnen L, Moermans JP, Ledoux P. Percutaneous Herbert screw fixation for fractures of the scaphoid: review of 30 cases. *Chir Main.* 2002; 21(6):350-354

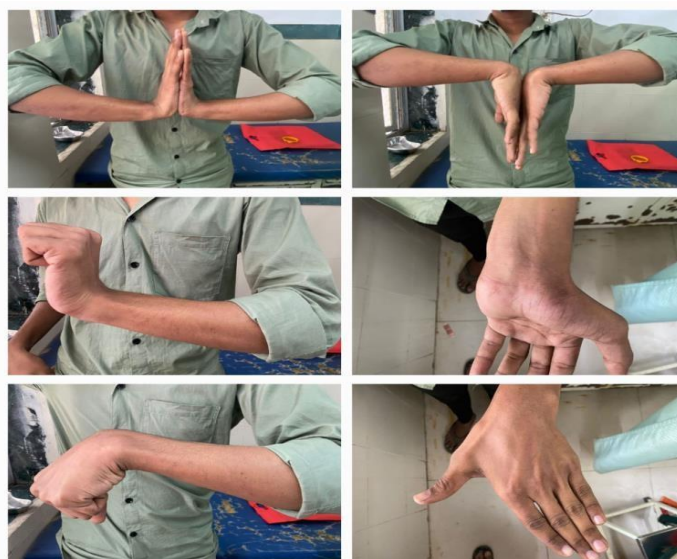### Figures:



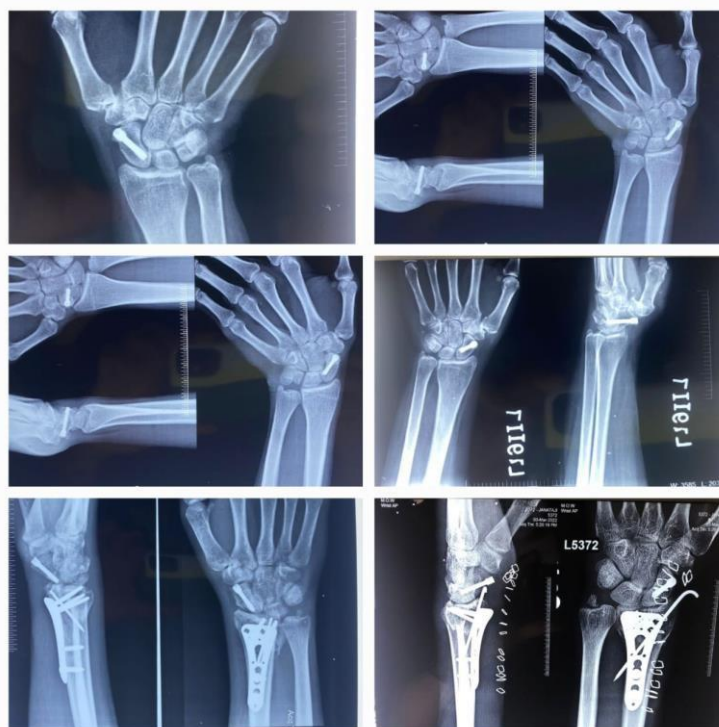
**Figure 1.** Plain radiographs showing minimally displaced fractures of patients of our study



**Figure 2.** Intraoperative fluoroscopy. Scaphoid view showing screw entry over the guidewire (A). Scaphoid view showing central screw placement (B). Oblique wrist view showing central screw placement (C).



**Figure 3.** Showing Full flexion, extension, ulnar deviation radial deviation



**Figure 4.** Follow up radiographs at 10 weeks showing well united scaphoid fractures with no signs of arthritis, necrosis with screws in situ