

**Original Research Article****A RETROSPECTIVE OBSERVATIONAL STUDY OF THE CLINICAL SCENARIO AND OUTCOME OF THE TRAUMATIC POPLITEAL ARTERY INJURY IN A TERTIARY CARE CENTRE**

<sup>1</sup>Prof. (Dr) K. Elancheralathan, <sup>2</sup>Dr. Shanmugavelayutham Chitravelu, <sup>3</sup>Dr. D. Ashok Kumar, <sup>4</sup>Dr. Reddi Jhansi, <sup>5</sup>Dr. Karthick Kalaichelvan, <sup>6</sup>Dr. Shabnam Fathima A

<sup>1</sup> HOD And Professor, Department of Vascular Surgery, Stanley Medical College, Chennai

<sup>2</sup> Associate Professor, Department of Vascular Surgery, Tamilnadu Government Multi Superspeciality Hospital, Chennai

<sup>3</sup> Associate Professor, Department of Vascular Surgery, Stanley Medical College, Chennai

<sup>4</sup> Resident, Department of Vascular Surgery, Stanley Medical College, Chennai

<sup>5</sup> Assistant Professor, Department of Vascular Surgery, Stanley Medical College, Chennai

<sup>6</sup> Assistant Professor, Department of Vascular Surgery, Stanley Medical College, Chennai

**Corresponding Author: Dr. Reddi Jhansi**

**Abstract**

**Introduction and objective:** Injuries to the popliteal artery from blunt or penetrating trauma are routinely found in trauma centres. Early detection of the possibility of arterial injury is crucial for the limb salvage.

**Material and methods:** We retrospectively reviewed the records of the patients who were managed for popliteal artery injury at our institution during the study period (2020-2022). 30 Patients were treated during the study period 2020-2022. Information extracted and analysed included demographic data, clinical presentation, physical examination, blood investigation, colour Doppler. Surgical data included vessel injury, technical aspects of repair, associated complications and outcomes.

**Results:** There were 30 patients: 22males (73.3%) and 8 females (26.6%). Mean age  $\pm$  SD was  $24.7 \pm 5.8$  years. Most patients (90%) were under the age of 30 years. Blunt trauma was the common cause of popliteal artery injury (60%) and penetrating trauma accounted for 40% which included traumatic and iatrogenic injuries during orthopaedic procedures. All the patients had associated skeletal injury. Concurrent popliteal vein injury with popliteal artery injury was seen in 36.6% of patients. All patients had undergone popliteal artery bypass with reverse great saphenous vein graft harvested from the contralateral lower limb and popliteal vein injury was managed with vein ligation. Mean ischemia time at presentation was  $9.26 \text{ hrs} \pm 3.91$ . Five patients had delayed presentation. Seven patients (23.3%) underwent amputation. Of these 5 sustained tibial plateau fractures and 2 both bone fracture associated with severe soft tissue injury. There were no intraoperative or in-hospital deaths. Associated skeletal injury was managed by orthopaedic department.

**Conclusion:** Popliteal artery injury represents a great challenge due to their complexity and low frequency. Early diagnosis and surgical repair is recommended. Despite technical improvements in management of popliteal artery injury, a high amputation rate is still seen,

especially in patients with extensive soft-tissue injury, associated skeletal trauma especially with tibial plateau fracture. Liberal use of fasciotomies, perioperative anticoagulation, antibiotics and presence of orthopaedician for skeletal fixation play an important role to achieve acceptable outcome.

**Keywords :** Popliteal artery ,saphenous vein graft ,fracture, amputation

### **Introduction**

Injuries to the peripheral vascular system account for 4–6% of all serious traumas. [1] Popliteal vascular injuries (PVI), in particular, are still rare, constituting only 0.2% of all traumas, yet they are potentially fatal and have a significant morbidity rate. [1]. Blunt or penetrating injuries commonly result in popliteal artery damage. Popliteal artery injuries are related to high-energy impact injuries and devastating orthopaedic injuries as they are caused by blunt mechanism. The popliteal artery is particularly vulnerable to damage from blunt extremity trauma because of its anatomic proximity to the femur, tibial plateau, and knee joint apparatus. [2,3] .These injuries frequently result in debilitating soft tissue disruption, bone deformities and nerve impairments, which can result in amputations and relatively bad outcomes. The most common reason for amputation in this limb-threatening injury is delay in diagnosis. Unacceptably high amputation rates occur when revascularization is not accomplished within 6–8 hours. [4.] Open surgery is the choice of management in acute trauma setting. Endovascular has limited role though some surgeons prefer in cases of dissection and pseudoaneurysm. For the extremities to be saved, early detection of the likelihood of vascular damage is essential. Vascular damage control manoeuvres maximise the chance of saving life and limb in severe injuries.

### **Objectives:**

To study and analyse the clinical profile, evaluation, management and outcome of the patients with popliteal artery injury treated at our institute.

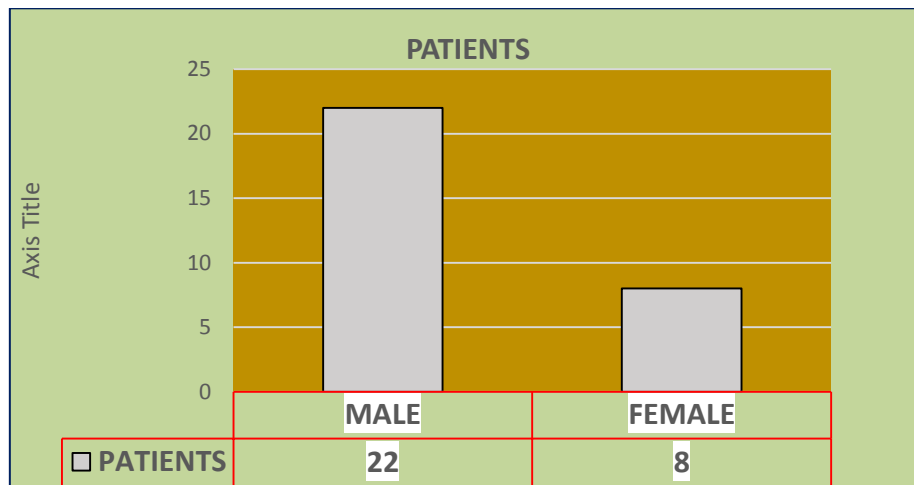
### **Materials and Methods:**

We retrospectively reviewed the records of patients who were managed for popliteal artery injury at our institution during the study period (2020-2022). 30 Patients were treated and the information extracted and analysed included demographic data, clinical presentation, physical examination, blood investigation, colour Doppler. Surgical data included vessel injury, associated skeletal and nerve injuries, technical aspects of repair, associated complications and outcomes. Vascular damage to the popliteal vessels was identified using preoperative clinical assessment and radiographic imaging, upon arrival, routine x-rays of the lower extremity were taken to check for bony fractures or dislocations. Results from specific diagnostic tests, such as duplex ultrasonography and computed tomography angiography (CTA) were gathered and compared to the results of the physical examination.

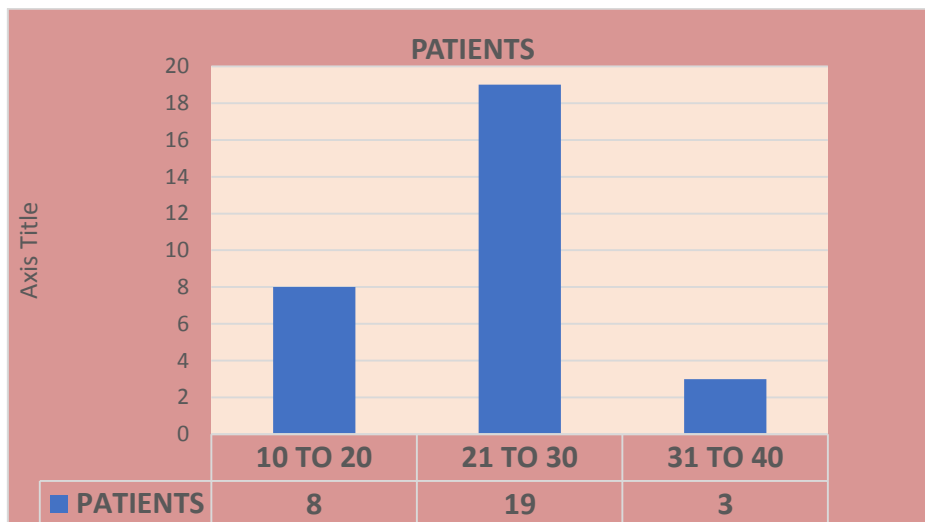
Classic "hard signs" of vascular compromise include pulsatile bleeding, reduced or absent pulses, enlarging or pulsatile hematomas, the existence of a bruit or palpable thrill or symptoms of distal ischemia such as pain, pallor, paraesthesia, paralysis or poikilothermia. [1,5,6]. Presence of neurological deficits, cyanosis and temperature change are reliable indicators of vascular compromise. [1,6].The popliteal artery may become damaged due to transection, blockage, intimal injury, pseudoaneurysm or the development of a fistula. [3,7] Presence of hard signs suggest for rapid surgical intervention without additional diagnostic testing. The artery injuries were repaired by standard open surgical revascularization methods. All skeletal fractures accompanied by decreased pulses required rapid reduction and vascular reevaluation. All patients with features suggestive of compartment syndrome underwent 2-incision 4-compartment calf fasciotomies.

**Results:**

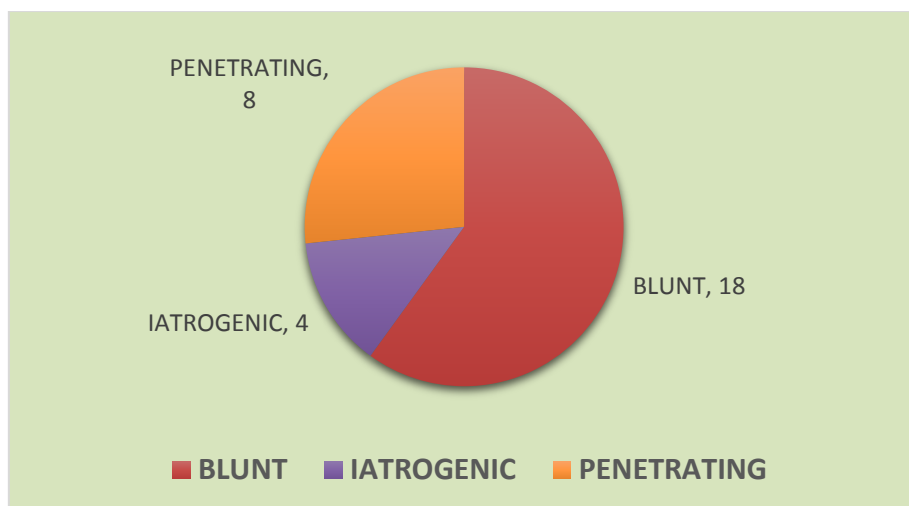
There were 30 patients: 22 males (73.3%) and 8 females (26.6%).

**Graph 1:**

Most patients (90%) were under the age of 30 years. Mean age  $\pm$  SD was  $24.7 \pm 5.8$  years.

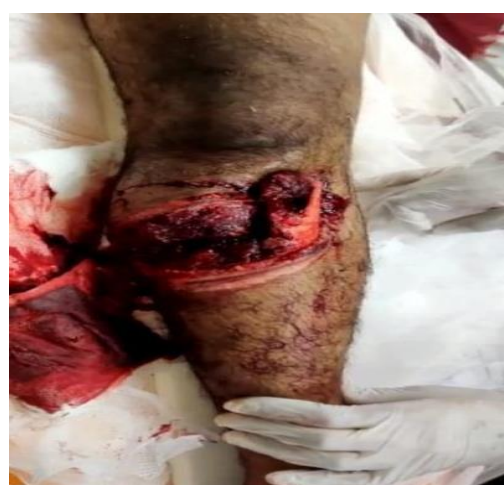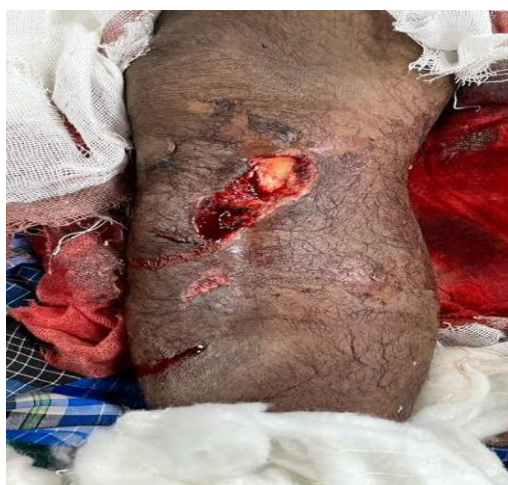**Graph 2:**

Blunt trauma was common cause of popliteal artery injury (60%) and penetrating trauma accounted for 40% which included traumatic (26.6%) and iatrogenic injuries (13.3%). All the patients had associated skeletal injury.

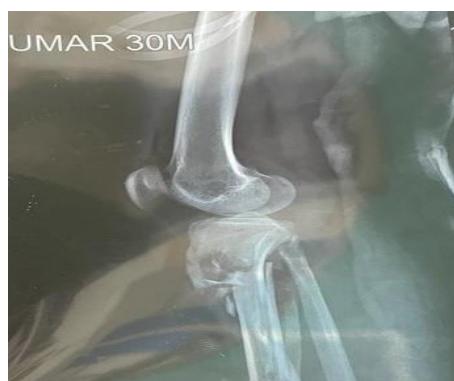

**Graph 3:**

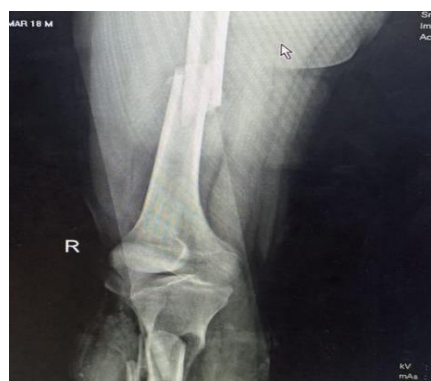**PREOPERATIVE IMAGES**



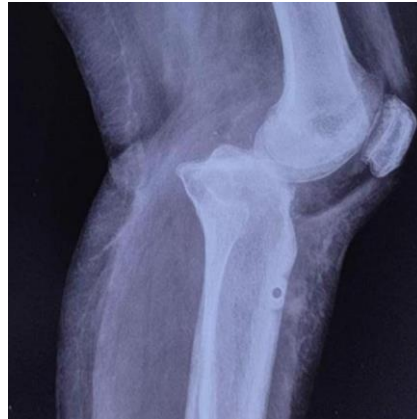**ASSOCIATED SKELETAL INJURY:**



**Tibial plateau fracture fracture**

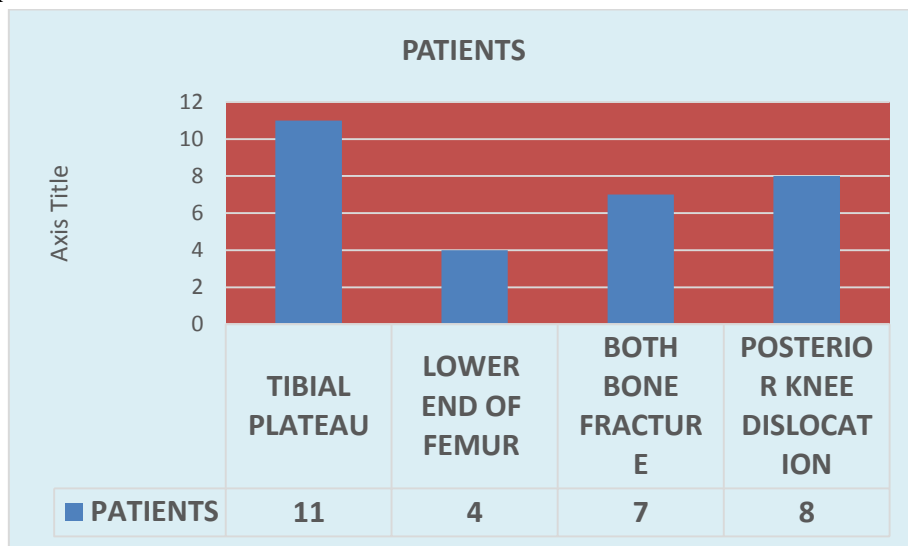


**Fracture shaft of femur +tibial plateau**

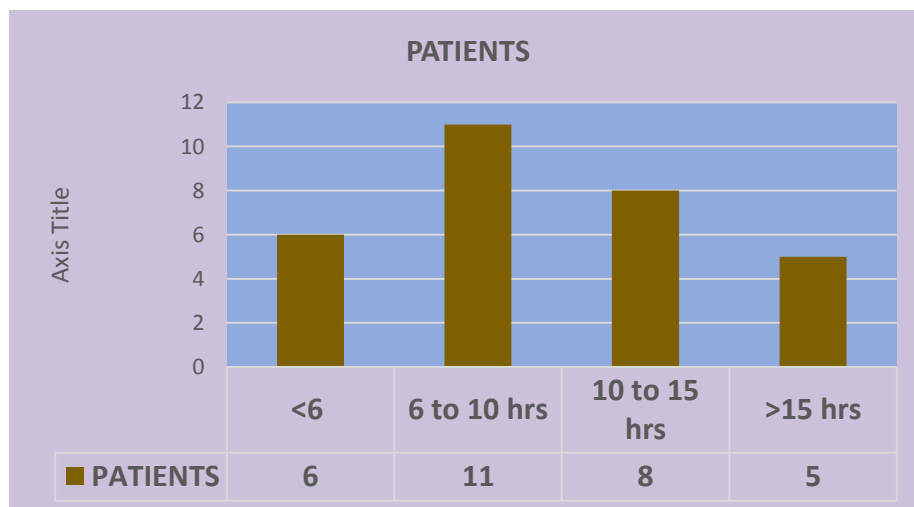


**Posterior knee dislocation**

Most common associated skeletal injury was tibial plateau followed by posterior knee dislocation



Mean ischemia time at presentation was 9.26 hrs ± 3.91 hours.



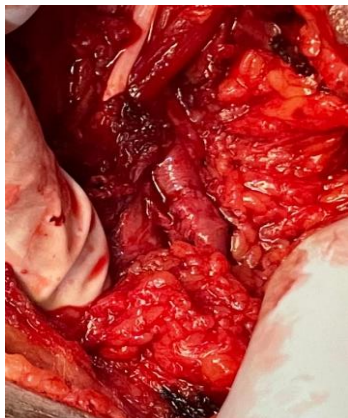
**Revascularisation:**

Of 30 patients,

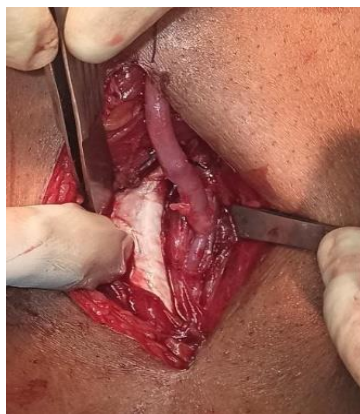- All 30 patients underwent bypass with reverse saphenous vein graft
- Of 30 patients, 7 underwent redo anastomosis for compromised distal flow; which further underwent amputation.
- None of the patients underwent patch angioplasty or end to end anastomosis
- No patient underwent prosthetic graft repair
- None of the patients underwent endovascular intervention

**Operative steps:**

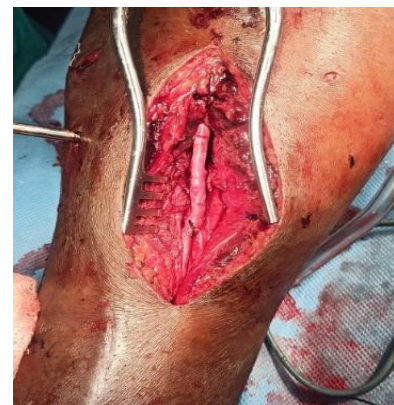- General or regional (most of the cases) anaesthesia was given based on the patients' clinical condition.
- Muscle viability was verified following fasciotomy.
- After skeletal stabilisation, exposure of the proximal popliteal/superficial femoral artery and the mid-posterior tibial artery (or anterior tibial in one case) were done and controls taken.
- The saphenous vein of the opposite lower limb was harvested and reversed.
- Depending on the severity of the soft tissue injury, infection and bone injury, the tunnel was created in the anatomical plane or subcutaneous plane (in 2 patients).
- Systemic heparinisation was done.
- Reversed GSV to proximal popliteal artery/SFA end to side anastomosis was completed.
- Graft was tunneled to the distal vessel and good forward flow in graft was confirmed and clamped.
- 3Fr Fogarty catheter was passed distally via the tibial vessel to remove thrombus and to get back bleed. Heparin saline was filled in the distal vasculature.
- Vein graft to the distal tibial vessel end to side anastomosis was completed.
- After bypass, the flow status was assessed with hand held doppler.

**INTRAOPERATIVE IMAGES:**

**GSV TO PROXIMAL ARTERY**

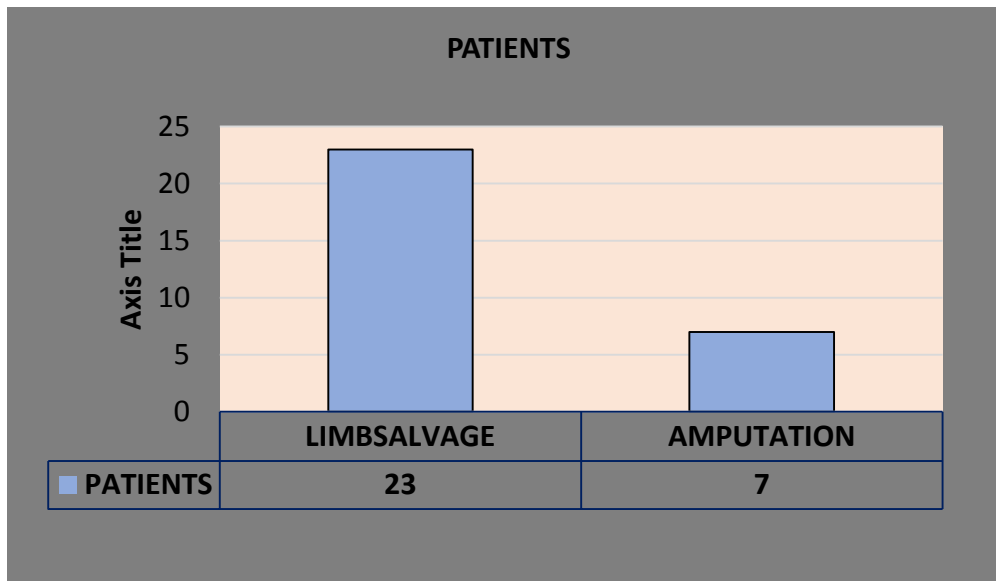


**GSV TO MID PTA BYPASS.**



**END TO SIDE ANASTOMOSIS**

**OUTCOME:**



- Of 7 (23.3%) patients who underwent amputation, 5 had sustained tibial plateau fracture (3 of them presented late (>15 hrs)) and 2 patients had both bone fracture associated with severe soft tissue injury.
- All the patients underwent above knee amputation.
- Prolonged ischaemia associated with all or none phenomenon, no reflow phenomenon, distal segment contusion and infection leading to blow out / sepsis led to amputation in these patients.
- 76.6% of vascular repairs were patent upon hospital discharge.
- 9 patients sustained popliteal vein injury. All underwent vein ligation.
- 4 of 9 patients with popliteal vein injury underwent amputation.
- Among 10 patients with MESS score >7, 7 patients underwent amputation.
- 2 patients had foot drop.
- There were no intraoperative or in-hospital deaths.
- Associated skeletal injury was managed by orthopaedic department.

#### Impact of study variables on amputation rate:

STUDY VARIABLES	AMPUTATION RATE	
	Number	Patients
<b>AGE</b>		
10 to 20 yrs	1/8	12.5%
21 to 30 yrs	5/19	26.3%
31 to 40yrs	1/3	33.3
<b>MECHANISM OF INJURY</b>		
BLUNT	5/18	27.7%
PENETRATING	2/12	16.6%
<b>ASSOCIATED SKELETAL INJURY</b>		
TIBIAL PLATEAU	5/11	45.4%
BOTH BONE FRACTURE	2/7	28.5
<b>MESS SCORE</b>		
<7	1/20	5%
>	6/20	60%

<b>ISHEMIA TIME (HOURS)</b>	
-LIMB SALVAGE GROUP	7.00 hrs $\pm$ 3.007
-AMPUTATION GROUP	13.57.hrs $\pm$ 3.55

### Discussion :

Among traumatic lower extremity vascular injuries, popliteal artery injuries (PAIs) continue to be a problematic condition and pose the highest risk of limb loss. [8] Penetrating trauma is the most frequent reason for vascular damage in the extremities. Blunt trauma, which includes injuries from road accidents, high-angle falls, and crush injuries, ranks as the second most frequent cause. [9]. The popliteal artery is most commonly injured during physical trauma. With the transmission of force to the lower extremity that results in major blunt trauma, there is a risk of soft tissue, vascular, bone and nerve damage. [5,10]. Due to blunt mechanisms, PAIs are frequently accompanied by high-energy impact injuries, such as posterior knee dislocations, complex tibial plateau fractures or supracondylar femur fractures, which can have serious orthopaedic consequences [1,10]. The popliteal surface of the femur, the fascia of the popliteus muscle and the capsule of the knee joint make up the popliteal fossa's floor. The popliteal artery is particularly vulnerable in this region due to osseous injuries, such as complicated fractures or dislocations. [1,5,10]. The trauma team leader, the nursing staff, specialists in orthopaedics, anaesthesia, emergency medicine and vascular surgery must all work together in an organised manner to offer care quickly. A sequential MDT strategy is needed in cases with severe soft tissue loss, bone injuries and neurovascular compromise in order to increase the likelihood of saving the limb. The most effective management practises for vascular trauma are currently being researched, despite significant attempts to establish protocols and guidelines. The overall treatment of patients can be enhanced by early detection of lower limb vascular injuries. Early resuscitation and the avoidance of exsanguination need immediate involvement of the trauma team. Hard signs of vascular injury are bleeding, hematomas that are growing, pulsatile bleeding, the presence of bruits or thrills, and symptoms of distal ischemia .[11]. "Soft" signs (suggest additional imaging evaluation, traditionally catheter-based angiography) of vascular injury at presentation have been used to guide the workup of severe extremity trauma. In the acute context, peripheral nerve injuries are challenging to identify. In most cases, having a nerve injury does not make you more likely to lose a limb. Between 15% and 35% of identified venous injuries occur when there is an extremities arterial disruption. There is disagreement over whether vein repair or ligation leads to better outcomes [12]. Recent studies have found higher VTE rates in patients with repaired than ligated venous injuries, suggesting that the treatment of the vein does not appear to affect the risk of VTE. [13,14]. A proper vascular exam is necessary at first evaluation. A complete neuromuscular evaluation should include a physical examination, ABI, Doppler examination and duplex ultrasound. Additional radiographic imaging should be done if the patient has an abnormal pulse exam or an ABI of less than 0.9. In the majority of trauma facilities, radiographic imaging using either computed tomography (CT) angiography (CTA) or traditional angiography is easily accessible. The "gold standard" for vascular examination, conventional angiography, has mostly been replaced by CTA due to the resource burden and extended acquisition time of subtraction angiography. in selected cases like stable patients, non-expanding hematoma, multisegment fractures, CT angiogram is done to identify the damaged segments and distal patent vessels for landing zone. It is recommended to restore blood flow by damaged control management principles before skeletal stabilisation.

#### 1. Temporary Hemorrhage control

- Tourniquet



- Direct manual pressure (junctional – proximal axillary and femoral)
- Intraoperative image guided endovascular balloon occlusion (in unstable lower limb junctional hemorrhage[15,16])

## 2. Temporary Shunting

- Temporary vascular shunts - allowing for the restoration of perfusion during orthopedic manipulation or to allow for intensive resuscitation or transfer of a patient
- Any flexible tube with a lumen can be used as an improvised vascular shunt (pediatric feeding tubes are frequently used) [17]
- Shunt thrombosis is directly related to dwell time and is more common in distal vessels, with overall thrombosis rates of about 5%.[18,19,20]

### Commercially available shunts

- The **Argyle** is a relatively rigid simple plastic tube
- The **Sundt** is a flexible, reinforced silicone tube with flared ends to prevent dislodgement.

### Surgical options:

Various surgical options available are patch angioplasty, end-to-end anastomosis, interposition or bypass graft. A small arteriotomy wound can be repaired with patch angioplasty. It is possible to conduct a spatulated end-to-end anastomosis in straight, nonbranching vessels with focal trauma by resecting a short wounded section and freeing up enough of the vessel proximally and distally. It is recommended to use a suitable length reversed saphenous vein interposition or bypass graft from the opposite thigh [21,22,23]. In smaller vessels, prosthetic conduit has lower patency rates than autologous vein, and its high infection rates are challenging to treat, leading to high rates of graft explanation and amputation [24]. The majority of occlusions happen within the first week, which points to technical issues as the cause of graft failure. However, we advise temporarily implanting a vascular shunt in order to restore blood flow before skeletal stabilisation. The temporary shunt may be withdrawn once skeletal stabilisation is complete and proceeding for revascularization. To achieve the MDT aim, the knee must be immobilised with external fixators, and after the patient's condition has improved, open reduction and internal fixation (ORIF) must be performed. In some cases, extra-anatomic bypass can restore flow while attempting to avoid infected wounds or when there has been significant soft tissue loss. As per the literature, 5.9% of all the acute peripheral artery injuries are treated by endovascular management. Injuries presenting with bleeding and occlusion have been effectively treated with stent grafts as well as occlusive artery lesions treated with balloon angioplasty and bare metal stents [25,26]. Smaller vessels can be treated using catheter directed embolization using coils and/or adhesive, and it appears to work particularly well for treating arteriovenous fistulas and minor pseudoaneurysms. [27]. There is no role of endovascular management in the popliteal artery injuries due to its anatomical constraints. Leg loss and compartment syndrome are two typical side effects of PAIs. Liberal fasciotomies can lower the rate of amputation. [28,5]. Amputation risk factors for lower extremity arterial injuries have been repeatedly found as being high-energy mechanism with MESS score >7, older age, multiple arterial injuries, severe soft tissue injury, fracture and onset of compartment syndrome [29]. Systemic anticoagulation, primary arterial repair and the presence of a good doppler signals distally within 24 hours were all related with limb salvage. [30] Many patients with successful limb salvage may exhibit neurological abnormalities related to PAIs throughout the course of long-term follow-up. [1,5] Patients had foot drop and temporary or permanent peroneal nerve dysfunction upon discharge. Early mobilisation, together with integrated occupational and physical therapy activities, improves recovery and results in stronger and better conditioned muscles. Poorer extremity's function is predicted by advancing age, blunt mechanisms (and related limb

injuries) and extended ischemia periods. For patients who report to urban trauma centres with a isolated popliteal vessel injury, the death rate related with lower extremity vascular trauma is still modest. Thoracic, abdominal and brain traumas that co-exist with extremities injuries increase mortality. Early MDT approach and coordinated trauma care begin with field triage standards for emergency medical services and training in the early application of tourniquets and direct pressure. Primary amputation is more frequently determined by the patient's physiologic state than by difficult vascular reconstruction technique. The term "secondary amputation" describes limb loss that occurs after a vascular limb salvage attempt.

### Review of literature:

STUDY	OUR-2022	JUAN,etal-2021[31]	Amr Eletal-2017[32]	JASON,etal-2015[33]	MAZRI etal-2005[34]	SUBASI etal 2001[35]
PATIENTS	30	10	20	47	19	41
GENDER	M-22 (73.3%) F -8 (26.6%)	M-8 (75%) F-2 (25%)	M-16(80%) F -4(20%)	M-43(91.4%) F -5(8.6%)	M-17(89.5%) F-2(10.5%)	M-35(85.6%) F-6(14.4%)
MEAN AGE IN YRS	24.7 ± 5.8	32.5	33 ±1.3	38.1 ±16.1	34	23
MEC. OF INJURY	B-18 (60%) P-12 (40%)	B-5(50%) P-5(50%)	B-14(70%) P-6(30%)	B-26(55.3%) P-21(44.7%)	B-13(68.4%) P-6(31.6%)	B-22(53.6%) P-17(46.4%)
SKELETAL INJURY	30(100%)	7(70%)	14(70%)	25(53.1%)	16(84.6%)	41(100%)
MEAN ISHEMIA TIME IN HRS	9.26±3.91	10	13±6	-	-	10.25±2.78
SURGERY METHODS	BYGRAFT – 30 (100%)	BYGRAFT-6 (60%) E-E-4(40)	INTERPOSITION GSV – 9 (45%) END TO END – 3(15%) VEIN PATCH – 2(10%) SIMPLE REPAIR – 2(10%) PTFE – 2(10%)	BYGRAFT-38 (80.8%) E-E-4(8.51%) PTFE-2(4.25%) THROMBECTOMY-3(6.38%)	BYGRAFT-10 (52.63) E-E-1(5.2%) INTERPOSITION-1(5.2%) REPAIR- 2 (10.5%) VEIN PATCH-1(5.2%) AVF-R-2(10.5%)	BY-GRAFT-29(70.7%) E-E-5(12.19%) THROMBECTOMY -7 (17.07%)
LIMB SALVAGE	23(76.6%)	10(100%)	16(80%)	39(83%)	14(77%)	32(78%)
AMPUTATION	7 (23.3%)	-	4(20%)	8(17%)	5(13%)	9(22%)

### Conclusion :

Popliteal artery injury represents a great challenge due to their complexity and low frequency. Early diagnosis and surgical repair is recommended. Despite technical improvements in management of popliteal artery injury, a high amputation rate is still seen, especially in

patients with extensive soft-tissue injury, associated skeletal trauma especially with tibial plateau fracture. Liberal use of fasciotomies, perioperative anticoagulation, antibiotics and presence of orthopedician for skeletal fixation play an important role to achieve acceptable outcome

**Conflict of interest:** None

### References :

1. J.D. Sciarretta, A.J. Perez-Alonso, D.J. Ebler, et al., Popliteal vessel injuries: complex anatomy, difficult problems and surgical challenges, *Eur. J. Trauma Emerg. Surg.* 38 (2012) 373e391.
2. Chapman JA. Popliteal artery damage in closed injuries of the knee. *J Bone Joint Surg Br.* 1985;67:420-423.
3. Abou-Sayed H, Berger DL. Blunt lower-extremity trauma and popliteal artery injuries. *Arch Surg.* 2002;137:585–589.
4. Steele HL, Singh A. Vascular Injury after Occult Knee Dislocation Presenting as Compartment Syndrome. *J Emerg Med.* 2009;4:1.
5. Sciarretta JD, Macedo FI, Otero CA, et al. Management of traumatic popliteal vascular injuries in level I trauma center: a 6-year experience. *Int J Surg.* 2015;18:136–141.
6. Feliciano DV. For the patient: evolution in the management of vascular trauma. *J Trauma Acute Care Surg.* 2017;83(6):1205–1212.
7. Teixeira PGR, DuBose J. Surgical management of vascular trauma. *Surg Clin North Am.* 2017;97(5):1133–1155.
8. Tan TW, Joglar FL, Hamburg NM, et al. Limb outcome and mortality in lower and upper extremity arterial injury: A comparison using the national trauma data bank. *Vasc Endovascular Surg.* 2011;45(7):592–597.
9. Subasi M, Cakir O, Kesemenli C. Popliteal artery injuries associated with fractures and dislocations about the knee. *Acta Orthop Belg.* 2001;67:259–266. Sciarretta JD, Macedo FI, Otero CA, et al. Management of traumatic popliteal vascular injuries in level I trauma center: a 6-year experience. *Int J Surg.* 2015;18:136–141.
10. Trieman GS, Yellin AE, Weaver FA, et al. Examination of the patient with knee dislocation. The case for selective arteriography. *Arch Surg.* 1992;127(9):1056–1062.
11. Fox N, Rajani RR, Bokhari F, et al. Evaluation and management of penetrating lower extremity arterial trauma. *J Trauma Acute Care Surg.* 2012;73(5):S315–S320.
12. Rich NM, Collins Jr GJ, Andersen CA, McDonald PT. Autogenous venous interposition grafts in repair of major venous injuries. *J Trauma Acute Care Surg.* 1977;17(7):512–520
13. Manley NR, Magnotti LJ, Fabian TC, et al. Impact of venorrhaphy and vein ligation in isolated lower-extremity venous injuries on venous thromboembolism and edema. *J Trauma Acute Care Surg.* 2018;84(2):325–329.
14. Hobson RW, Yeager RA, Lynch TG, et al. Femoral venous trauma: Techniques for surgical management and early results. *Am J Surg.* 1983;146(2):220–224.
15. Scerbo MH, Holcomb JB, Taub E, et al. The trauma center is too late: Major limb trauma without a pre-hospital tourniquet has increased death from hemorrhagic shock. *J Trauma Acute Care Surg.* 2017;83(6):1165–1172.
16. Brenner M, Inaba K, Aiolfi A, et al. Resuscitative endovascular balloon occlusion of the aorta and resuscitative thoracotomy in select patients with hemorrhagic shock: early results from the American Association for the Surgery of Trauma's Aortic Occlusion in Resuscitation for Trauma and ACU. *J Am Coll Surg.* 2018;226(5):730–740
17. Alarhayem AQ, Cohn SM, Cantu-Nunez O, et al. Impact of time to repair on outcomes in

- patients with lower extremity arterial injuries. *J Vasc Surg.* 2019;69(5):1519–1523
18. Inaba K, Aksoy H, Seamon MJ, et al. Multicenter evaluation of temporary intravascular shunt use in vascular trauma. *J Trauma Acute Care Surg.* 2016;80(3):359–365.
  19. Mathew S, Smith BP, Cannon JW, et al. Temporary arterial shunts in damage control: Experience and outcomes. *J Trauma Acute Care Surg.* 2017;82(3):512–517.
  20. Subramanian A, Verduyck G, Dente C, et al. A decade's experience with temporary intravascular shunts at a civilian level I trauma center. *J Trauma.* 2008;65(2):316–324.
  21. Borman KR, Snyder WH, Weigelt JA. Civilian arterial trauma of the upper extremity. An 11 year experience in 267 patients. *Am J Surg.* 1984;148(6):796–799.
  22. Ray HM, Sandhu HK, Meyer DE, et al. Predictors of poor outcome in infrainguinal bypass for trauma. *J Vasc Surg.* 2019;70(6):1816–1822.
  23. Klocker J, Bertoldi A, Benda B, et al. Outcome after interposition of vein grafts for arterial repair of extremity injuries in civilians. *J Vasc Surg.* 2014;59(6):1633–1637
  24. Frech A, Pellegrini L, Fraedrich G, et al. Long-term clinical outcome and functional status after arterial reconstruction in upper extremity injury. *Eur J Vasc Endovasc Surg.* 2016;52(1):119–123
  25. Carrfielo G, Lagan D, Mangini M, et al. Percutaneous treatment of traumatic upper-extremity arterial injuries: A single-center experience. *J Vasc Interv Radiol.* 2011;22(1):34–39.
  26. Piffaretti G, Tozzi M, Lomazzi C, et al. Endovascular treatment for traumatic injuries of the peripheral arteries following blunt trauma. *Injury.* 2007;38(9):1091–1097
  27. du Toit DF, Lambrechts AV, Stark H, Warren BL. Long-term results of stent graft treatment of subclavian artery injuries: Management of choice for stable patients? *J Vasc Surg.* 2008;47(4):739–743
  28. Asensio JA, Marengo J, Petrone P. Popliteal artery injuries. *Less ischemic times leads to improve outcomes (unpublished data)* [Google Scholar]
  29. Wallin D, Yaghoubian A, Rosing D, et al. Computed tomographic angiography as the primary diagnostic modality in penetrating lower extremity vascular injuries: a level I trauma experience. *Ann Vasc Surg.* 2011;25(5):620–623.
  30. Wagner W, Calkins E, Weaver F, Goodwin JA, Myles RA, Yellin AE. Blunt popliteal artery trauma: one hundred consecutive injuries. *J Vasc Surg.* 1988;7(5):736–743. [PubMed] [Google Scholar]
  31. Juan O. Marín Peraltal, Daniel Gutiérrez Véliz2, et al *ARGENTINE JOURNAL OF CARDIOVASCULAR 62 SURGERY - VOLUME XIX - ISSUE 3*
  32. Amr El Shazly, et al Ahmed El Barbary *POPLITEAL ARTERY INJURY: Tanta University Hospital experience.* <https://www.researchgate.net/publication/283516015>
  33. Jason D. Sciarretta, Francisco Igor B. Macedo\*, et al Management of traumatic popliteal vascular injuries in a level I trauma center: A 6-year experience: J.D. Sciarretta et al. / *International Journal of Surgery* 18 (2015) 136–141.
  34. M AZRI M. Y AHYA, \* B IBOMBE P. M WIPATAYI, \*: Popliteal artery injury: Royal Perth experience and literature review: 2005, *ANZ Journal of Surgery.*
  35. M. SUBASHI1, O. CAKIR2, C. KESEMENLI1 et al. : *POPLITEAL ARTERY INJURIES ASSOCIATED WITH FRACTURES AND DISLOCATIONS ABOUT THE KNEE: Acta Orthopædica Belgica, Vol. 67 - 3 – 2001.*