

Histological outcome on liver and testis in male rats received Tamsulosin

(1) **Rand Abdulateef Abdullah** Department of Anatomy, College of Medicine,
University of Mosul, Mosul, Iraq (**Corresponding author**) ORCID ID:0000-0001-
5355-5948

E- mail :rundabdullateef@uomosul.edu.iq

(2) **H. kh. Ismail** Department of pathology, College of Veterinary Medicine, University
of Mosul, Mosul, Iraq.

Abstract

Tamsulosin is alpha-1 adrenergic receptor antagonist which can alleviate the symptoms of urinary tract infections in elderly men because it reduces spasm of periurethral smooth muscle fibers and reduce the obstruction around bladder. Thirty animals were separated into 3 groups. Group (1) is control group, group (2) received 0.4mg/kg/day of the medicine orally for seven days. Group (3) received 0.4mg/kg body weight of the medicine for thirty days. Results: Group (2) liver tissue sections showed dilatation of portal vein, ballooning degeneration and necrosis of some hepatocytes while group (3) showed Severe congestion of portal vein with inflammatory cell infiltration and necrosis of most of hepatocytes. Microscopic examination of testis tissue slides of group (2) showed the tubules were less numerous, degeneration and necrosis of germinal epithelium while in group (3) testis sections showed reduced number of atrophied seminiferous tubules with interstitial edema. Vacuolation of spermatocytes and distortion of the process of spermiogenesis. It is concluded that tamsulosin can produce some histological effects on both liver and testis tissues when used for short duration (one week) while it can lead to harmful histological damage when it is given for long period (four weeks).

Keywords: tamsulosin, liver, testis, rat

Introduction

Benign prostatic hyperplasia is a well-known problem affecting especially old males and the risk of occurrence of this disease becomes higher with aging as it affects 80% of males after age of eighty. In fact, this hyperplasia occurs normally without underling cause like malignancy but, it is considered as part of the aging process (1).

On tissue examination, only tissue hyperplasia is detected. Treatment of this condition is only indicated when it is accompanied with associated symptoms especially lower urinary tract infections which are very irritative to the patient like dysuria, weak stream, frequency (2).

As many categories were designed for medical treatment alpha blockers is considered as first line of treatment as it has been shown to be superior to other lines of treatment. Tamsulosin is alpha-1 adrenergic receptor antagonist which can alleviate the symptoms as it reduces spasm of periurethral smooth muscle fibers and reduce the obstruction around bladder (3). It is metabolized in the hepatocytes by cytochrome P450 followed by sulfate coupling of metabolites and excreted in renal system (4).

Many side effects were recorded in patients using this medicine like hypotension, cognitive problems,

(5). Many experimental studies showed that it enhances the glucose uptake and increases the blood glucose level (6, 7). It can induce 2nd type of diabetes mellitus in elderly males (8).

The aim of the study is to establish whether tamsulosin has damaging effect on the testis and liver tissues in rats.

Materials and Methods

Animals

Adult male Wistar rats weighing 250-300 gram were chosen randomly from animal section of Veterinary college / university of Mosul. Thirty animals were kept for 2 weeks for acclimatization in plastic cages at room temperature with 12 hours light/ 12 hours dark cycle. Free access to ad libitum and tap water. Animals were separated into 3 groups. Group (1) is control group, group (2) received 0.4mg/kg/day of the medicine orally for seven days. Group (3) received 0.4mg/kg body weight of the medicine for thirty days.

Approval of ethical committee

It was received by the ethical committee of college of medicine, university of Mosul, Mosul, Iraq.

Drugs used

Tamsulosin hydrochloride, Tabuk pharmaceutical Mfg. Co. Saudi Arabia.

Experimental Design

Rats were separated into 3 groups with (N=10), The control group (1) received distilled water for 1 week, The second group (2) Tamsulosin (0.4mg/kg bodyweight) for 1 week, the third group

(3) tamsulosin (0.4mg/kg bodyweight) for 4 weeks. Treated animals of each group were killed 48 hours after ending the treatment.

Preparation of Histology sections

Liver and testis were dissected, liver specimens were fixed in 10% neutral buffered formalin while testis were fixed in Bouin's solution for 24 hours then they were transferred to 10% neutral buffered formalin fixative agent. Histology sections were made and stained with hematoxylin and eosin for histopathological changes.

Observation and results

The histological sections of liver of control groups (1) showed normal histological features, no congestion or necrosis detected (figure 1). Group (2) tissue sections showed dilatation of portal vein in the portal trait, ballooning degeneration of some hepatocytes with pale cytoplasm and pyknotic nuclei (figure 2). In addition, necrotic hepatocytes especially around central vein with inflammatory cell aggregation were observed (figure 3).

Microscopic examination of testis sections of control group showed normal seminiferous tubules with normal spermatocytes and spermiogenesis. Normal interstitial tissue (figure 4).

Microscopic examination of testis tissue slides of group (2) which received tamsulosin for 7 days showed the tubules were less numerous than control group (figure 5), some looked narrow with empty lumen, degeneration and necrosis of germinal epithelium with even distortion of architecture of seminiferous tubules (figure 6), some spermatocytes suffered from vacuolation, interstitial edema was noticed with destructed Leydig cells (figure 7).

Microscopic examination of liver tissue of group (3) which received tamsulosin for 4 weeks showed more serious and severe histopathological changes. Dilatation of central vein with vacuolation of hepatocytes and necrosis around it (figure 8). Severe congestion of portal vein with inflammatory cell infiltration around it and coagulative necrosis of hepatocytes was detected (figure 9). Sinusoidal dilatation with focal infiltration of inflammatory cells (figure 10). perivascular cuffing of inflammatory cells around central vein with foci of inflammatory cells in addition to scattered inflammatory cells infiltration (figure 11). Deposition of eosinophilic material in the connective tissue and extensive vacuolar necrosis were evident in this group (figure 12).

Microscopic examination of testicular tissue of group (3) showed reduced number of atrophied seminiferous tubules with interstitial edema (figure 13). Vacuolation of spermatocytes

and distortion of the process of spermiogenesis (figure 14), some tubules showed stenosis of lumen which is occupied by cellular debris without sperms. Necrosis of both Leydig cell and Sertoli cells (figure 15).

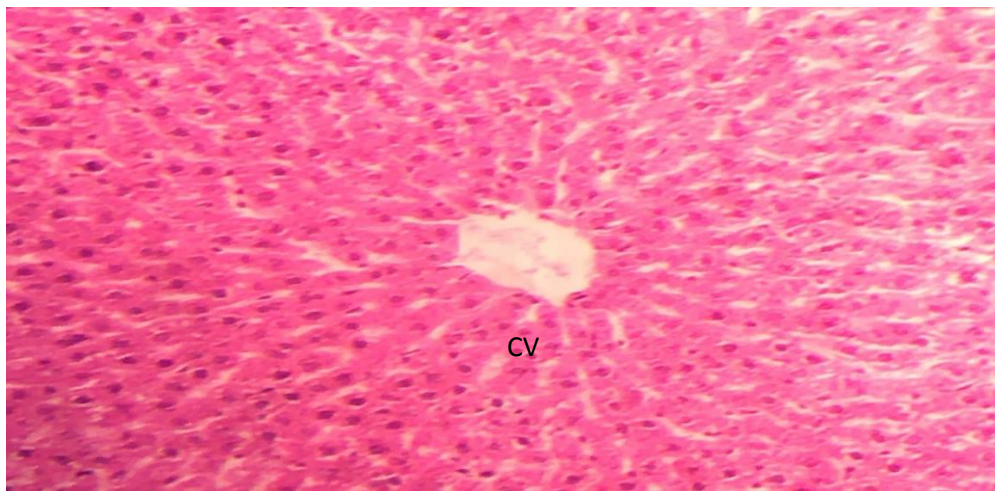


Figure (1): Sections of control group showed normal hepatocytes, normal central venule (CV). (H &E, 400X).

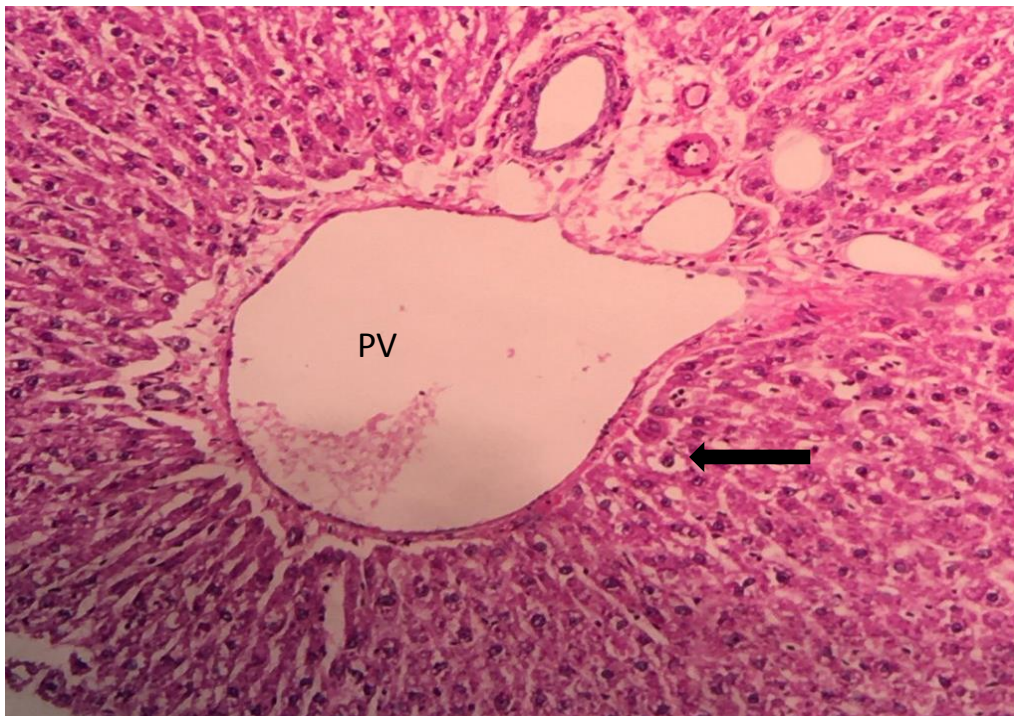

Figure (2): Sections of group (2) showed dilatation of portal vein (PV) in the portal trait, ballooning degeneration of some hepatocytes (black arrow). (H &E, 400X).

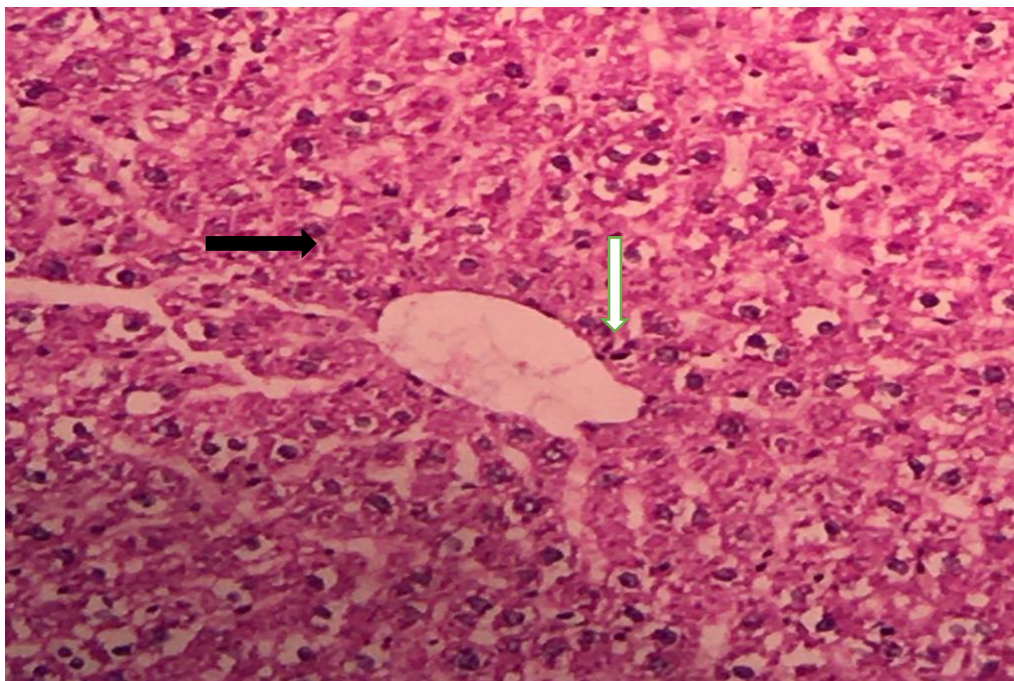


Figure (3): Sections of group (2) Showed necrotic hepatocytes around central vein (black arrow) with inflammatory cell aggregation (white arrow). (H &E, 400X).

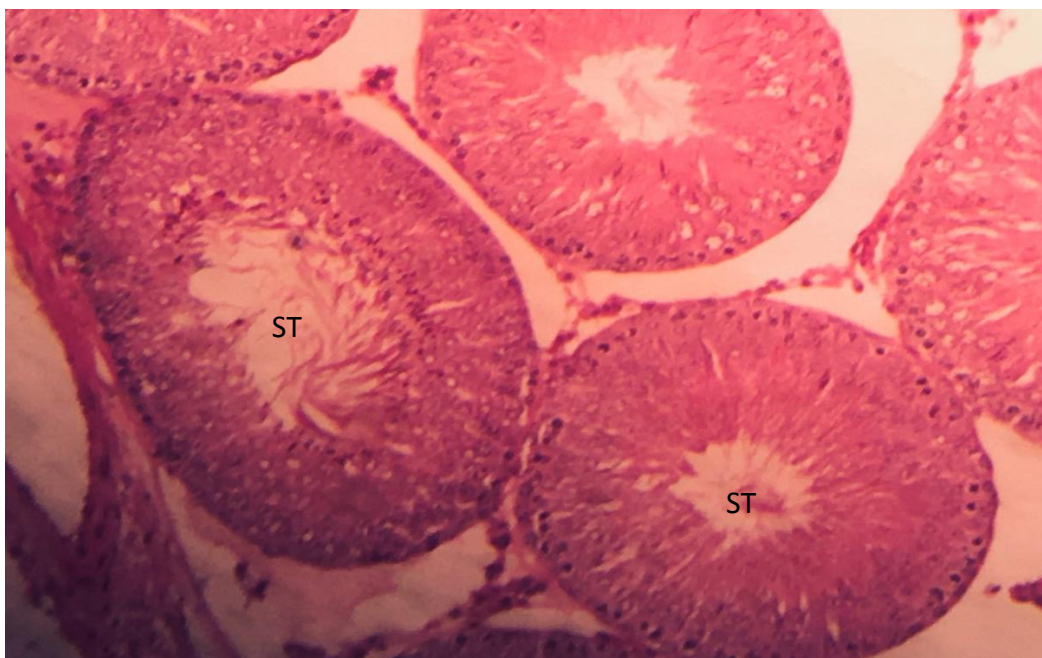


Figure (4) : Sections of control group showed normal seminiferous tubules (ST), normal spermatocytes .(H &E, 400X).

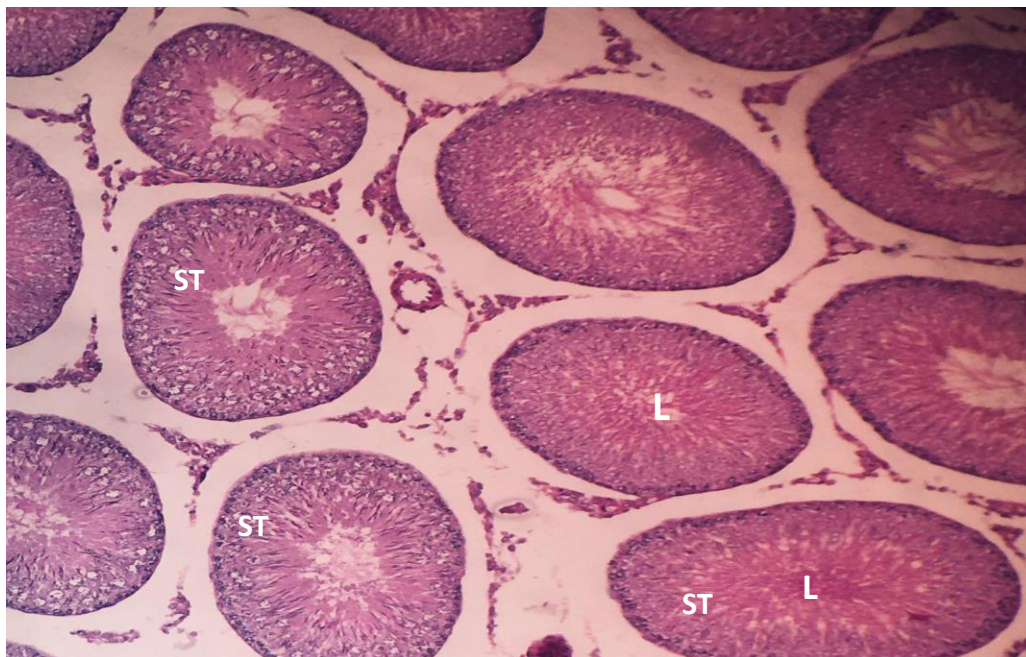


Figure 5:) Sections of group (2) revealed reduction in the number of seminiferous tubules (ST). narrow lumen (L) H &E, 100X).

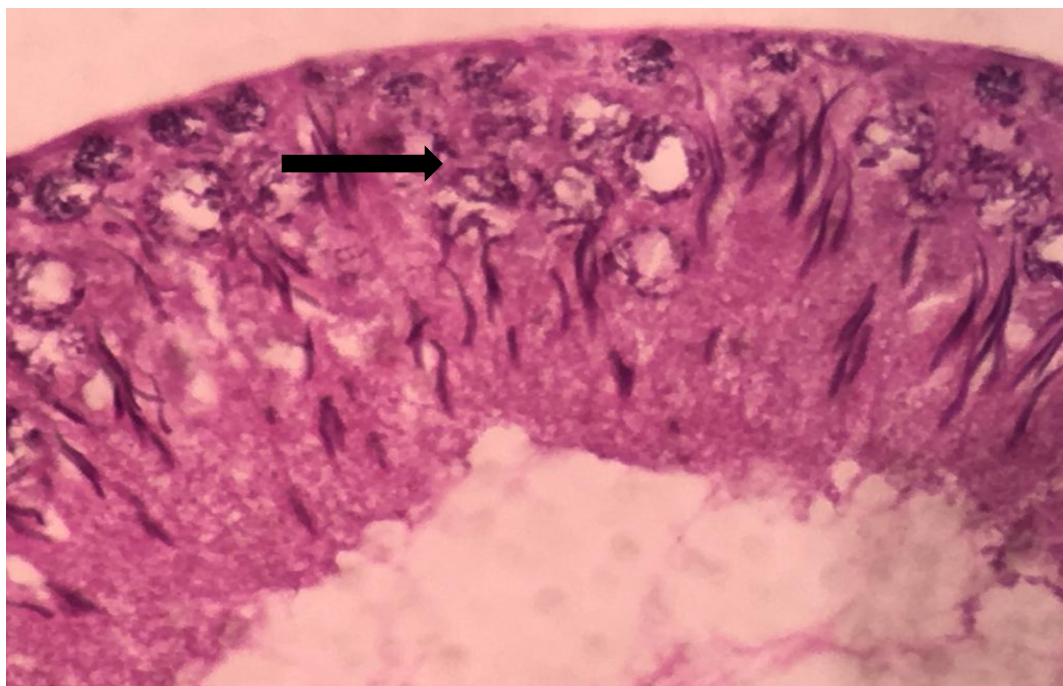


Figure 6: Sections of group (2) showed degeneration and necrosis of germinal epithelium with distortion of spermatocytes (black arrow).(H&E, 450X).

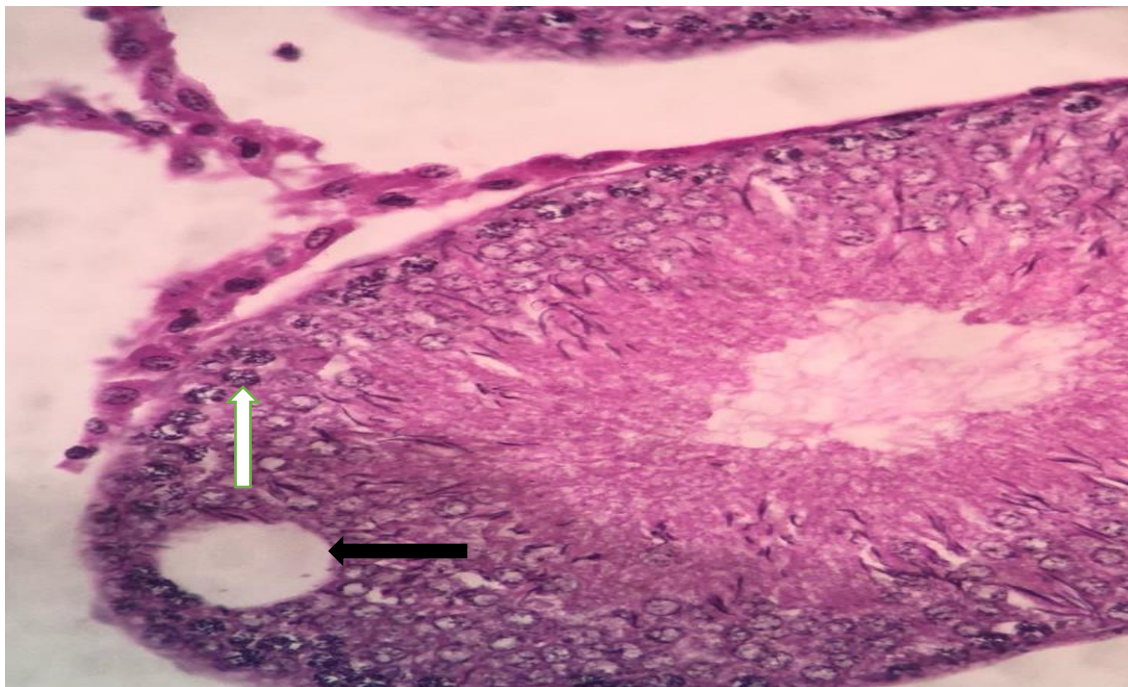


Figure 7: Sections of group (2) Showed vacuolation of spermatocytes (black arrow). Destroyed Leydig cells in the interstitial tissue (white arrow). (H&E, 400X).

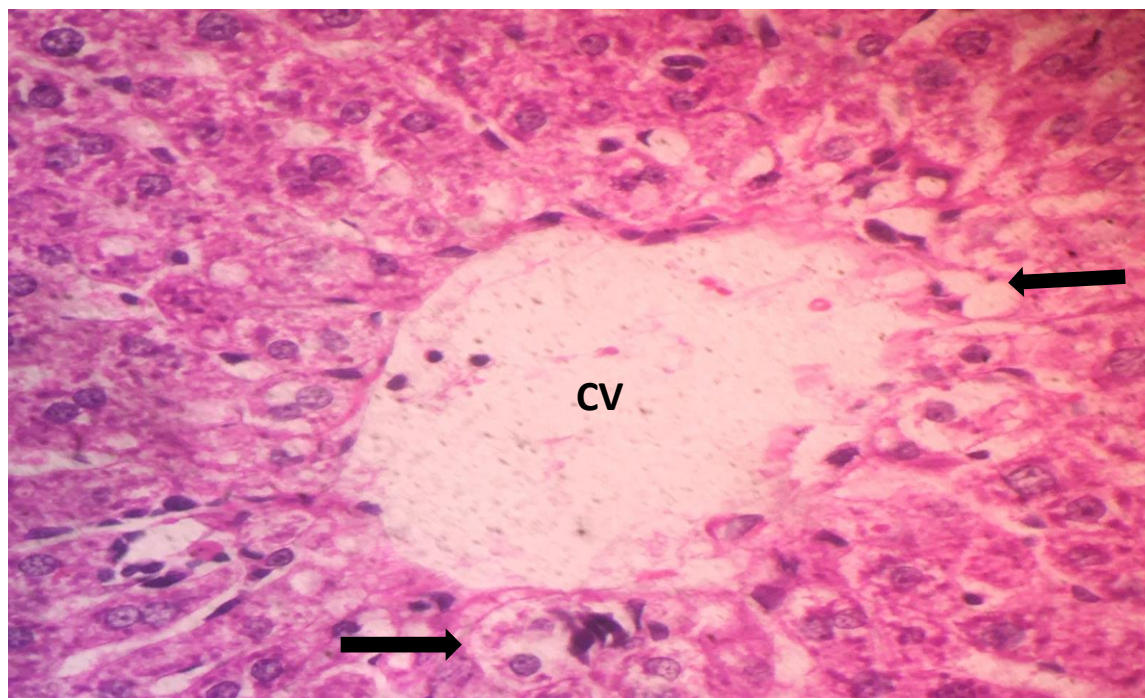


Figure 8: Sections of group (3) showed dilatation of central vein (CV) with vacuolation of hepatocytes and necrosis (black arrows). (H&E, 450X).

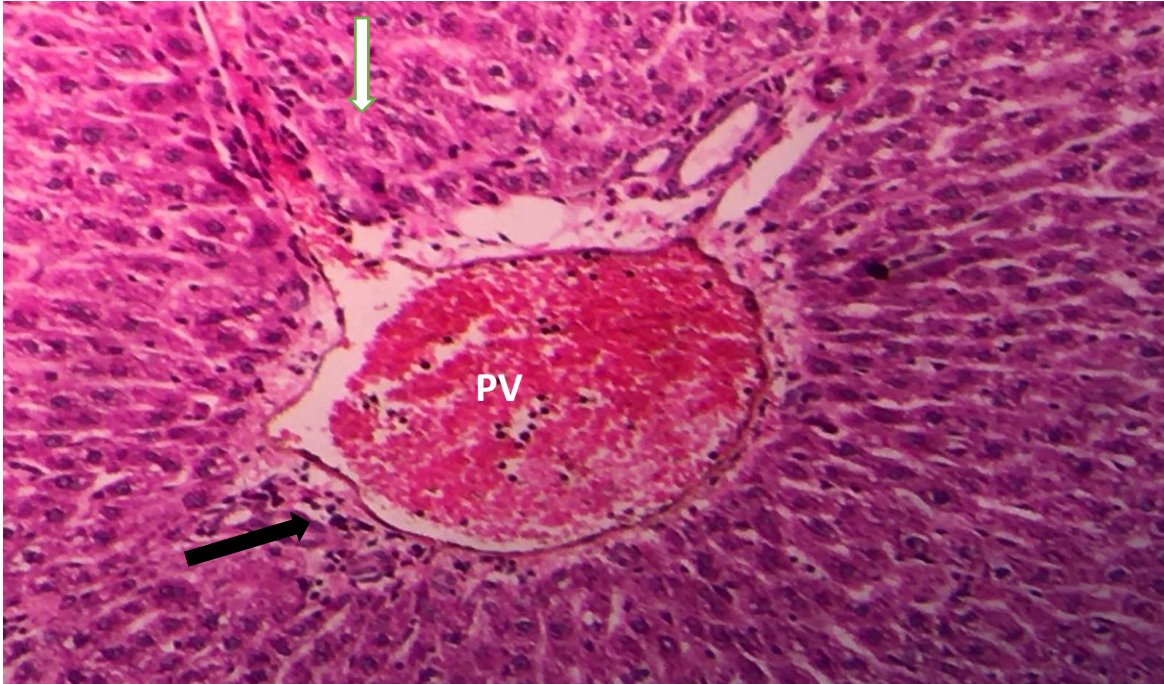


Figure 9 : Sections of group (3) showed congestion of portal vein (PV) with inflammatory cell infiltration around it (black arrow). necrotic hepatocytes around portal area (white

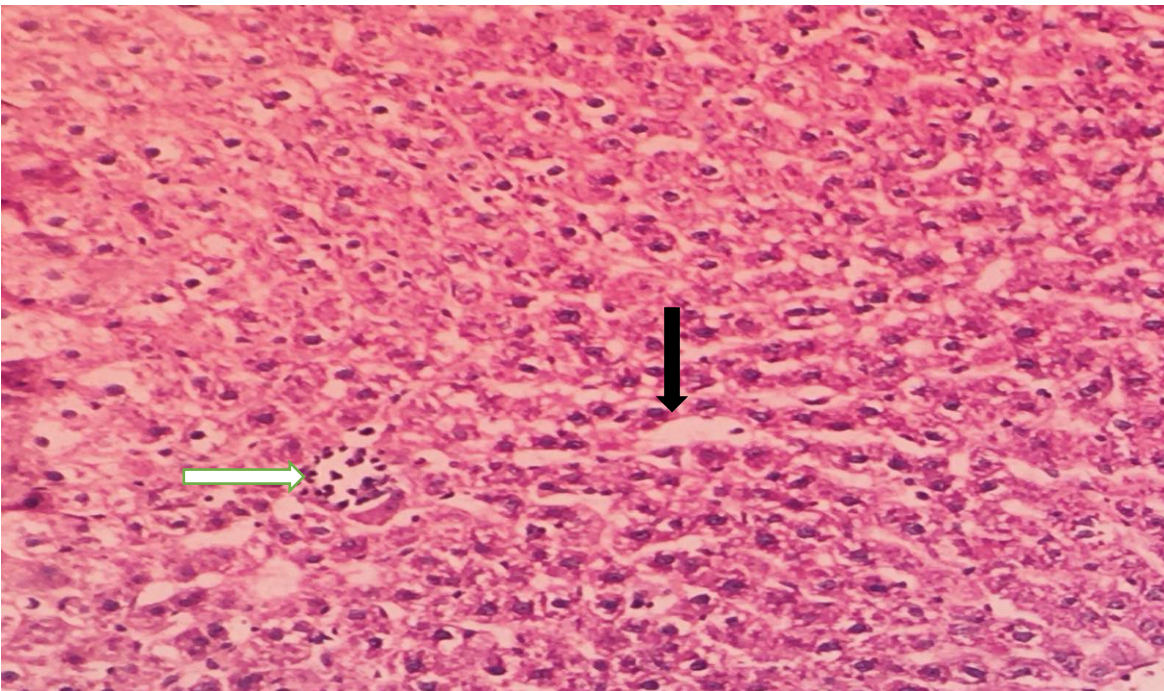


Figure 10: Sections of group (3) showed Sinusoidal dilatation (black arrow) with focal infiltration of inflammatory cells (white arrow).(H&E, 400X).

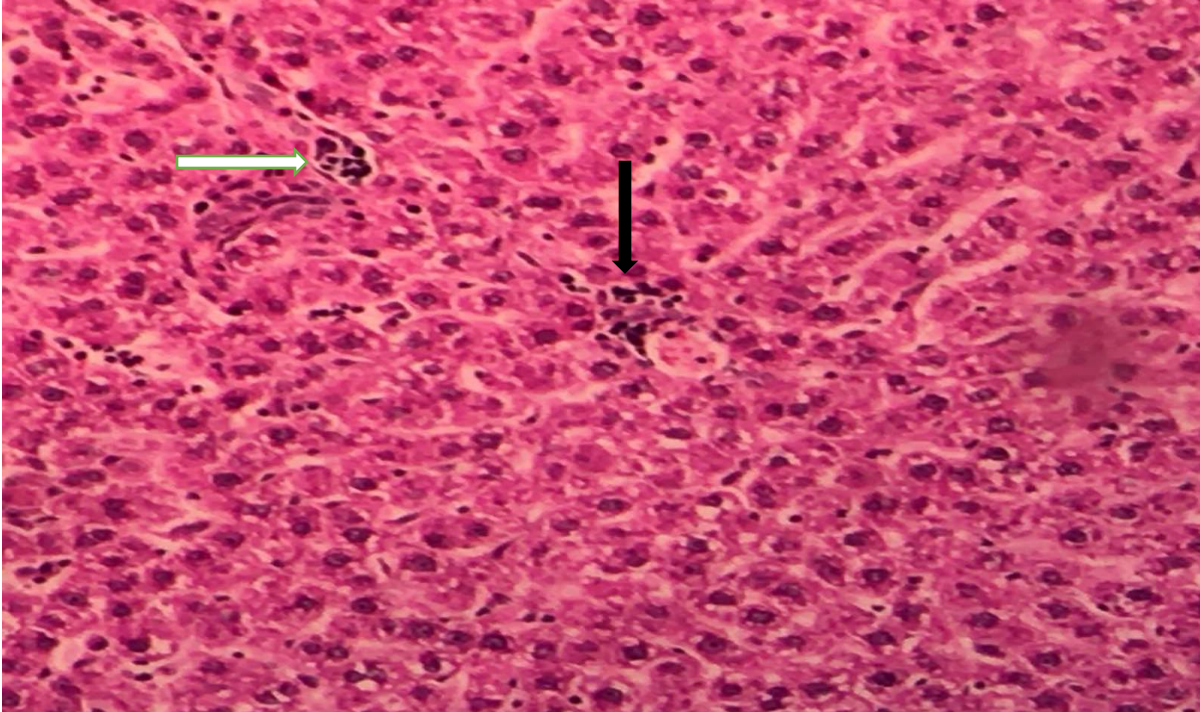


Figure 11: Sections of group (3) showed perivascular cuffing of inflammatory cells around central vein (black arrow) focal infiltration of inflammatory cells (white arrow). scattered inflammatory cells infiltration (arrow head). (H&E, 400X).

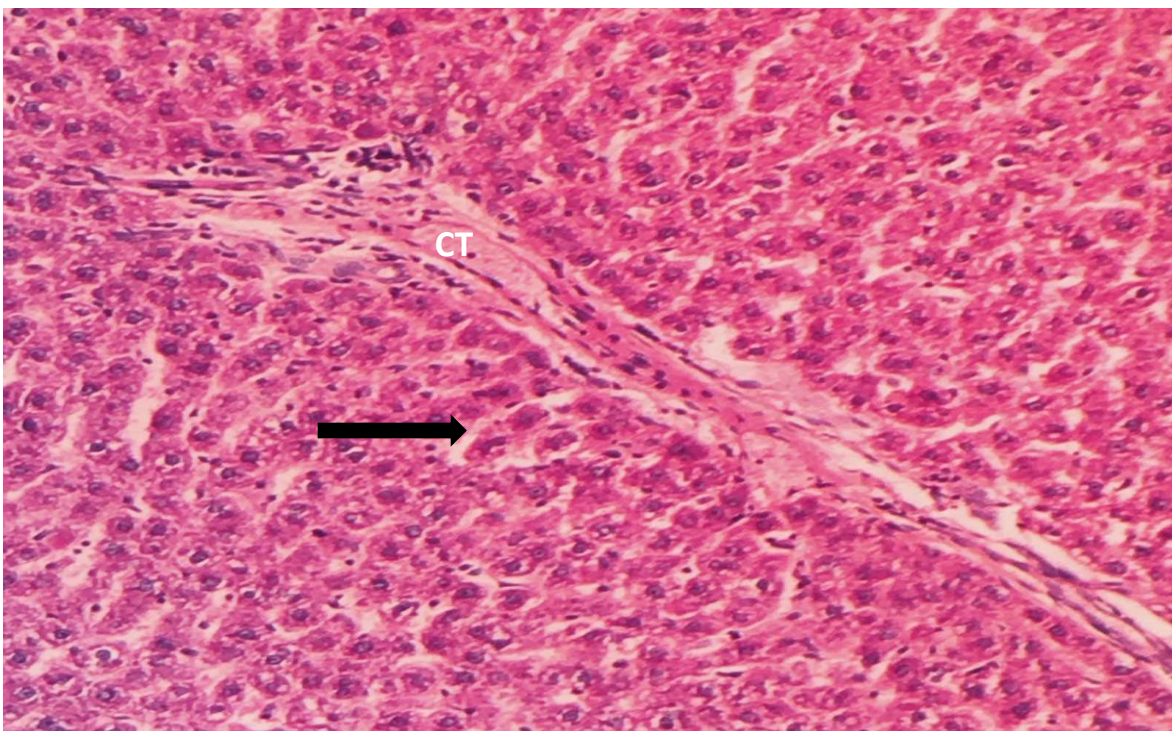


Figure 12: Sections of group (3) showed Deposition of eosinophilic material in the connective tissue (CT). Extensive vacuolar necrotic hepatocytes (black arrow). (H&E, 400X).

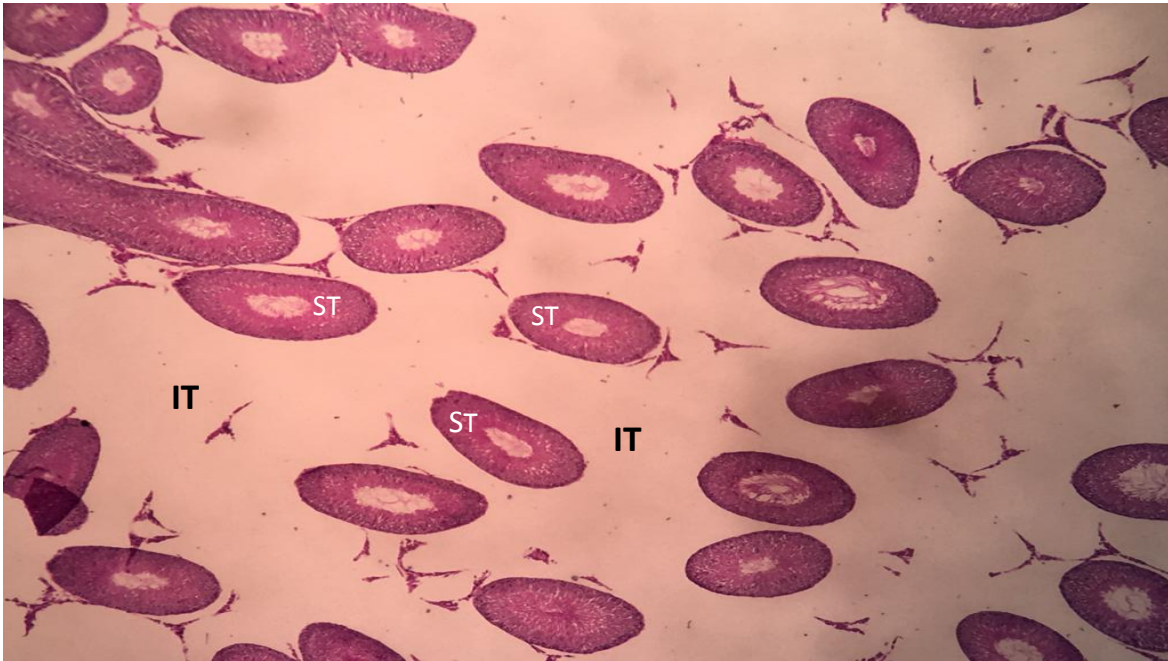


Figure 13: Sections of group (3) showed reduced number of seminiferous tubules (ST). interstitial tissue edema (IT). (H&E, 100X).

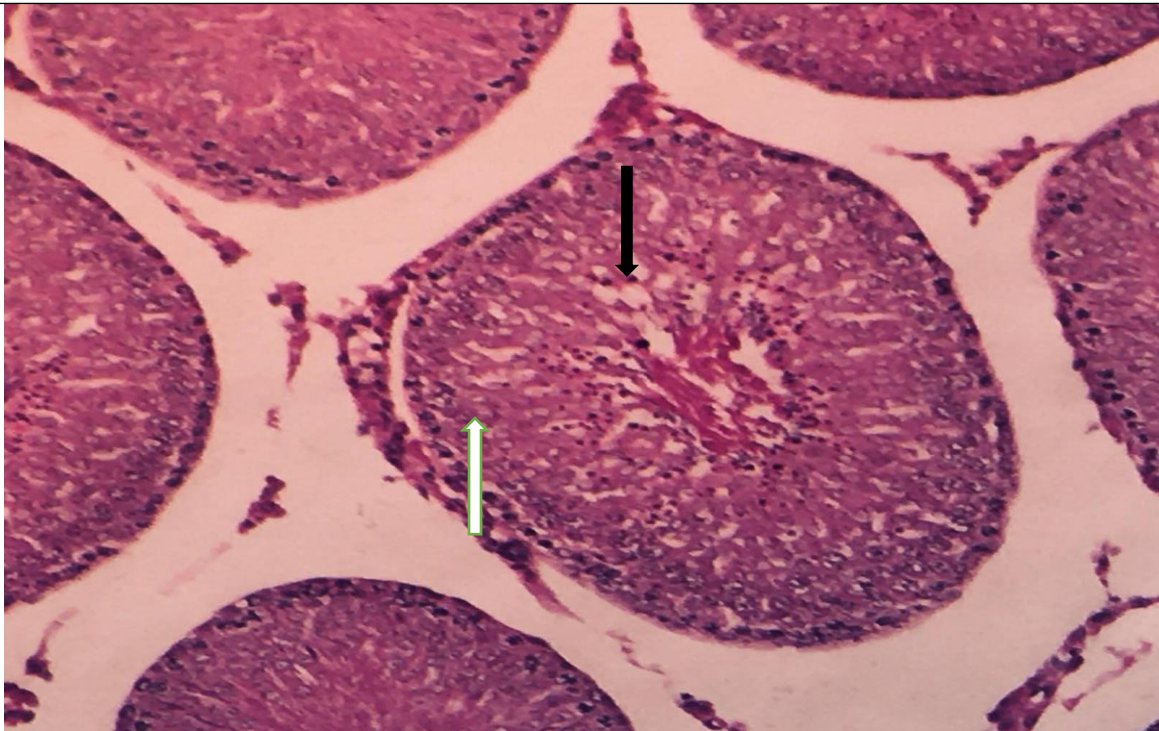

Figure 14: Sections of group (3) showed vacuolation of spermatocytes ((black arrow) and distortion of spermatocytes (white arrow). (H&E, 400X).

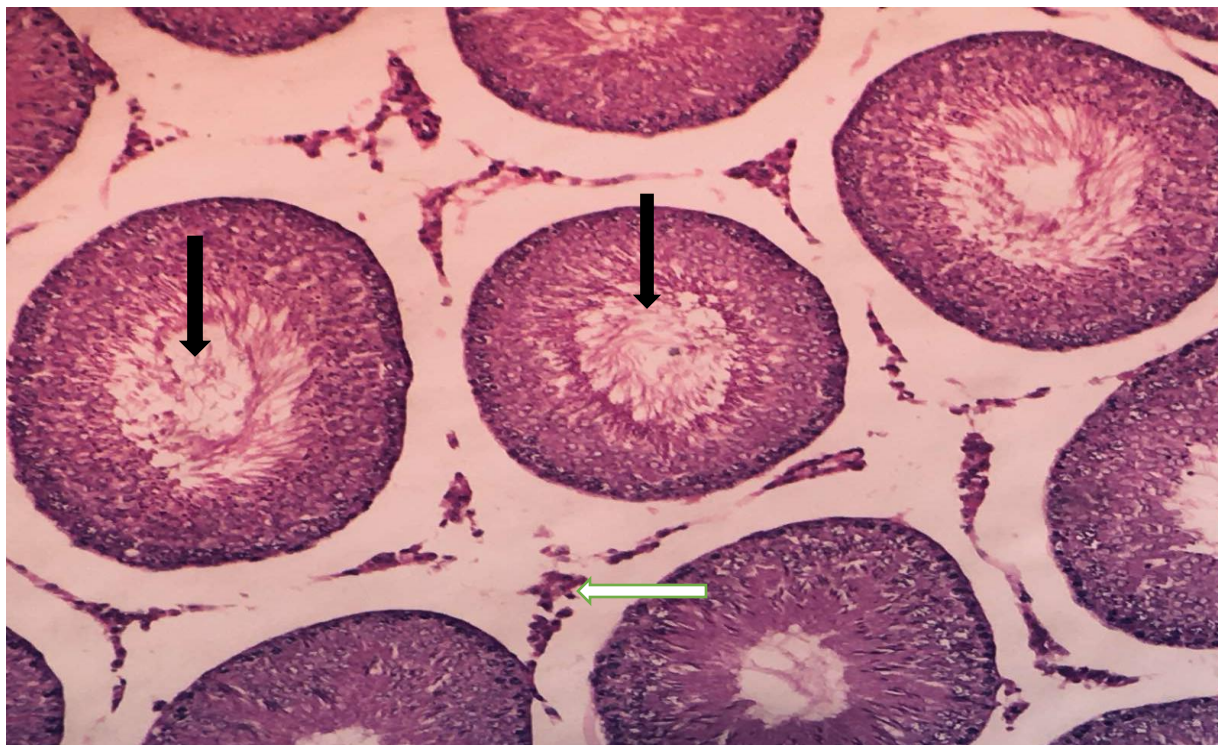


Figure 15: Sections of group (3) showed stenosis of lumen which is occupied by cellular debris without sperms (black arrows). Necrosis of Leydig cell (white arrow). (H&E, 100X).

Discussion

The current work presented that tamsulosin can lead to many histological changes in different treated groups. Group (2) which received tamsulosin for 1 week showed portal vein dilatation, ballooning degeneration and necrosis of some hepatocytes, with inflammatory cell aggregation were observed. These changes were more severe in group (3) which received tamsulosin for 4 weeks including extensive necrosis of hepatocytes. Histological slides of testis of group (2) showed that the tubules were less numerous with stenosis and empty lumen, degeneration and necrosis of germinal epithelium with vacuolation, and destructed Leydig cells. These changes were more severe in group (3).

Tamsulosin is easily bioactivated to different metabolites that encourage the liberation of reactive oxygen species (9) and peroxidation of cellular membrane of hepatocytes which associated with more production of malondialdehyde that considered as an indicator of oxidative stress causing alteration in the cytoskeleton proteins which finally ends with toxicity and tissue parenchymal damage (10, 11).

On 2015, a case report of an elderly man presented with acute drug induced liver

injury was recorded. The patient used tamsulosin for 15 days as treatment of lower urinary tract symptoms. (12). The most possible cause was due to production of toxic mediators by tamsulosin (13).

Al-Jassabi et al. (14) stated that tamsulosin activates liver tissue damage by enhancing the production of nitrous oxide which interferes with intracellular protein carbonyl which activates cellular damage.

The results of the study were in line with Olayinka et al. (15) study who reported the outcome of using both tamsulosin and dutasteride on rat's testis. they found that tamsulosin in dose of 3.4mg/kg for 14 days induce testicular damage.

Dikko et al. (16) studied the consequence of using a very low dose of tamsulosin (0.04mg/kg) on hepatic tissue. They found that no histological changes were observed.

Alpha blockers were widely used to alleviate lower urinary tract symptoms in males suffering from benign prostatic hyperplasia for their safety but still they can produce harmful effects on the testis (17).

In Some studies authors encourage switching tamsulosin from 0.2 mg/kg to 0.4 mg/kg according to the harshness of the symptoms without taking in consideration its effect on the testosterone hormone level and spermiogenesis (18, 19).

The findings of this study were in line with Kohestani et al. (20) who found that tamsulosin in a dose of 0.4 mg/kg body weight may inhibit androgenic hormone production and spermiogenesis.

Furthermore, Alwachi and Husain (21) studied the effect of lower doses of tamsulosin on testis in mice. They found that tamsulosin lead to stenosis of the seminiferous tubules, abnormal spermatocytes with necrosis. Interstitial edema and Leydig cells abnormality were also reported.

Conclusion

Tamsulosin can produce some histological effects on both liver and testis tissues when used for short duration (one week) while it can lead to harmful histological damage when it is given for long period (four weeks).

References

1. Oelke M, Baard J, Wijkstra H, de la Rosette JJ, Jonas U, Höfner K. Age and bladder outlet obstruction are independently associated with detrusor overactivity in patients with benign prostatic hyperplasia. *Eur Urol.* 2008; 54(2):419–26. DOI: 10.1016/j.eururo.2008.02.017.

2. Nunes RL, Manzano J, Truzzi JC, Bernardo WM. Treatment of benign prostatic hyperplasia. *Revista da Associação Médica Brasileira*. 2017; 63(2):95-99. DOI:10.1590/1806-9282.63.02.95.
3. Salinas GF, Rosette JM, Michel MC. Pharmacokinetics and Pharmacodynamics of Tamsulosin in its Modified-Release and Oral Controlled Absorption System Formulations. *Clinical Pharmacokinetics*. 2010; 49(3):177-88. DOI: 10.2165/11317580.
4. Patel R., Fiske J., Lepor H. Tamsulosin reduces the incidence of acute urinary retention following early removal of the urinary catheter after radical retropubic prostatectomy. *Urology* 2003; 62(2):287-91. DOI: 10.1016/s0090-4295(03)00333-9.
5. Leibacher NW, Da Silva MH. The Adverse Effects of Tamsulosin in Men with Benign Prostatic Hyperplasia, a Review of the Literature. *American Journal of Life Sciences* 7(4):68-74. DOI: 10.11648/j.ajls.20190704.11.
6. Flechtner-Mors M, Jenkinson CP, Biesalski A, Adler, G., and Ditschuneit, HH. 2004. Sympathetic Regulation of Glucose Uptake by the α 1 -Adrenoceptor in Human Obesity. *Obesity Research* 12 (4): 612–620. DOI: 10.1038/oby.2004.70.
7. Dikko M, Sarkingobir Y, Umar AI. Effect of Tamsulosin on Fasting Blood Glucose and Plasma Insulin Levels in Normal Wistar Rats. *ADSUJSR*. 2020; 8(2): 81 -84.
8. Dikko M, Bello Sh, Chika A, Aliyu S. Determination of Oral Glucose Tolerance (OGT) of Benign Prostatic Hyperplasia Patients Treated with Tamsulosin in Sokoto State, Nigeria. *Nigerian Journal of Pharmaceutical and Applied Science Research*. 2020; 9(2): 33-39.
9. Bouaïcha N, Maatouk I. Microcystin-LR and nodularin induce intracellular glutathione alteration, reactive oxygen species production and lipid peroxidation in primary cultured rat hepatocytes. *Toxicol Lett*. 2004; 148(1-2):53-63. DOI: 10.1016/j.toxlet.2003.12.005.
10. O'Donnell JT, Marks DH, Danese P, O'Donnell JJ. Drug-induced liver disease: primer for the primary care physician. *Dis Mon*. 2014; 60:55-104. DOI: [10.1016/j.disamonth.2013.11.002](https://doi.org/10.1016/j.disamonth.2013.11.002).
11. Pandit A, Sachdeva T, Bafna P. Drug-induced hepatotoxicity: A Review. *Journal of Applied Pharmaceutical Science*. 2012; 2(5):233-243. DOI: 10.7324/JAPS.2012.2541.
12. K. Berquet, A. Delezire, E. Polard, C Vigneau. Tamsulosin-induced acute liver injury: a case report. *Fundamental and Clinical Pharmacology*, Wiley. 2016; 30: 59-59.
13. Fremond L, Diebold MD, Thieffn G. Acute pseudoangiocholic hepatitis probably induced by tamsulosin. *Gastroenterol Clin Biol* 2006;30(10):1224-5. DOI: [10.1016/s0399-8320\(06\)73517-5](https://doi.org/10.1016/s0399-8320(06)73517-5).

14. Al-Jassabi S., Al-Omari A, Saad A , Azirun M. Tamsulosin-Induced Hepatotoxicity and Nephrotoxicity and Its Prevention by potato peel extract Extract. American-Eurasian Journal of Toxicological Sciences. 2011; 3 (2): 52-58. ISSN:2079-2050.
15. Olayinka ET , Adewole KE. Ameliorative effect of morin on dutasteride-tamsulosin-induced testicular oxidative stress in rat. J Complement Integr Med. 2020; 23;18(2):327-337. DOI: [10.1515/jcim-2019-0160](https://doi.org/10.1515/jcim-2019-0160).
16. Dikko M, Sarkingobir Y. Body Weight Determination and Histological Examination of Livers in Normal Rats Administered with Tamsulosin. J. Appl. Sci. Environ. Manage. 2020; 24(8): 1335-1340. DOI: <https://dx.doi.org/10.4314/jasem.v24i8.5>.
17. Koch K. Silodosin — a safer alpha-blocker targeting benign prostatic hyperplasia. South African Family Practice. 2015; 57(5): 291-292. DOI: 10.1080/20786190.2014.978099.
18. Yang PS, Chen CL, Hou CP, Lin YH, Tsui KH. An open label, prospective interventional study of the tolerability and efficacy of 0.4 mg oral tamsulosin oral controlled absorption system in men with lower urinary tract symptoms associated with benign prostatic hyperplasia who are unsatisfied with treatment with 0.2 mg tamsulosin. Clin Interv Aging 2018; 13: 235–242.
19. Roehrborn CG, Oyarzabal Perez I, Roos EP, Calomfirescu N, Brotherton B, Wang F, et al. Efficacy and safety of a fixed-dose combination of dutasteride and tamsulosin treatment compared with watchful waiting with initiation of tamsulosin therapy if symptoms do not improve, both provided with lifestyle advice, in the management of treatment-naïve men with moderately symptomatic benign prostatic hyperplasia: 2-year CONDUCT study results. BJU Int 2015; 116: 450–459. [doi:10.1111/bju.13033](https://doi.org/10.1111/bju.13033).
20. Kohestani Y, Kohestani B, Shirmohamadi Z, Faghani M. Effect of tamsulosin on testis histopathology and serum hormones in adult rats: Experimental study. Int J Reprod Biomed. 2020 ;18(7):531-538. doi: 10.18502/ijrm.v13i7.7370.
21. Alwachi SN, Husain DK. Tamsulosin hydrochloride (Flomax) effects on fertility of albino male mice. International Journal of Recent Scientific Research Research. 2014; 5 (2):326-331. ISSN: 0976-303.