

Original research article

A Prospective Study of Surgical Management of Comminuted Inter-trochanteric Fractures of Femur by using Cemented Bipolar Prosthesis in Elderly Patients

Dr. Chokka Ramesh Harish

¹ Assistant Professor, Dept. of Orthopaedics, Chalmeda Anand Rao Institute of Medical Sciences, Karimnagar, Telangana, India

Corresponding Author: Dr. Chokka Ramesh Harish.

Abstract

Introduction: The management of comminuted inter trochanteric fractures of femur in elderly patients is tricky as there is challenge of difficult anatomical reduction in osteoporotic bones, need for prolonged immobilization after surgery and more chances of screw cut out in poor quality bone. Prolonged immobilization will leads into complications like bed sores, chest infections , deep vein thrombosis, dependency and psycho social side effects , increasing the both morbidity and mortality. The aim of our study was to evaluate the functional outcome of cemented bipolar hemiarthroplasty in comminuted inter trochanteric fractures of femur in elderly patients using Harris Hip Score.

Materials and Methods: This is a Prospective study conducted from (March 2009 to June 2017) at Department of Orthopaedics, chalmeda Anand Rao Institute of Medical Sciences, Karimnagar Twenty elderly patients with age above sixty years having comminuted inter trochanteric fractures of femur treated by using cemented bipolar hemi arthroplasty were evaluated for functional outcome using Harris Hip Score.

Results : There were 12 female and 8 male patients with mean age of 68.82 years(60 -82)years treated by cemented bipolar hemiarthroplaty. Patients were followed up at 6 weeks, 3months , 6 month and 1 year. At one year follow up with help of Harris Hip Score 8 patients(40%) were graded as excellent, 10 patients(50%) as good and 2 patients (10%) as fair.

Conclusion: The procedure offered rapid mobilization , early return to pre injury level and gave a lasting solution to elderly patients with comminuted inter trochanteric fractures of femur.

Keywords: comminuted intertrochanteric fracture, cemented hemiarthroplasty, Harris Hip Score

Introduction

Injuries around the hip is a common problem in the elderly. There were an estimated 1.66 million hip fractures worldwide in 1990. This worldwide annual number is raising rapidly with an expected incidence of 6.26 million by the year 2050. An increase in these fractures is on rise due to increased life expectance of the people and osteoporosis. Intertrochanteric fractures make up 45% of all hip fractures ^[1] and are the major cause of death and disability in elderly.^[2]35-40% of these fractures are comminuted and unstable three and four part configurations with displacement of posteromedial cortex. The failure rates of these comminuted fractures fixed with sliding hip screws averages approximately 6-32%.^[1,3,4] In an effort to mobilize these patients more rapidly, permit early weight bearing and to avoid complications of recumbancy, hemiarthroplasty has been used to treat comminuted intertrochanteric fractures.^[4,5] Among intertrochanteric fractures 35% to 40% of

intertrochanteric fractures of hip are unstable ones which are the major cause of disability and death in the elderly^[6]. Displaced, unstable, severely comminuted intertrochanteric fractures are not easy to treat in elderly people with osteoporosis and complex intertrochanteric fracture. DHS does not allow for unrestricted weight bearing and failure rates between 5% to 12% have been reported^[7]. Proximal femoral nailing has shown better results in most cases of comminuted intertrochanteric fractures. However, the role of this nail in comminuted osteoporotic intertrochanteric fractures is still to be defined. To allow early post-operative weight bearing and to recumbancy, many surgeons have recommended and are doing primary prosthetic replacement for the treatment of these intertrochanteric fractures^[8]. The main goals for the treatment of these fractures in elderly patients are , to restore the pre-fracture activity status, to allow early full weight bearing and to avoid possible re-operation.^[9] Intertrochanteric fractures in elderly people are usually comminuted and unstable because of osteoporosis and indirect forces which include pull of iliopsoas muscle on the lesser trochanter and pull of the abductor muscle on the greater trochanter.^[10] The weak and porotic bone tolerates screws poorly so cut out is the major problem with internal fixation. Many a times patient spends a long time in bed, following standard internal fixation ,which complicates the recovery.¹¹ The treatment of comminuted intertrochanteric femur fracture in elderly patients has been a controversy and there is limited literature on prosthetic replacement of comminuted intertrochanteric fracture. So the purpose of this study is to evaluate the functional outcome of comminuted intertrochanteric fractures treated with cemented bipolar hemiarthroplasty.

Methodology

Data will be collected from patients presenting with comminuted intertrochanteric fractures admitted from (March 2009 to June 2017) at Department of Orthopaedics, Chalmeda Anand Rao Institute of Medical Sciences, Karimnagar for this study after obtaining their informed , valid written consent. Collection of data of patients presenting with comminuted intertrochanteric fractures are as follows. Collection of data of patients presenting with comminuted intertrochanteric fractures are as follows.

Inclusion criteria:

1. Patients with age group >60yrs of either sexes.
2. Elderly patients with unstable and comminuted intertrochanteric fractures

Exclusion Criteria

1. Any other fracture of bone in an ipsilateral limb
2. Intertrochanteric fracture with sub trochanteric extensions

Results

There were 12 female and 8 male patients with mean age of 68.82 years(60 -82)years treated by cemented bipolar hemiarthroplasty. Patients were followed up at 6 weeks, 3months , 6 month and 1 year. At one year follow up with help of Harris Hip Score 8 patients(40%) were graded as excellent, 10 patients(50%) as good and 2 patients (10%) as fair

TABLE 1: AGE DISTRIBUTION

Age in years	No of cases	% of patients
60-70	11	55%
70-80	7	35%
>80	2	10%

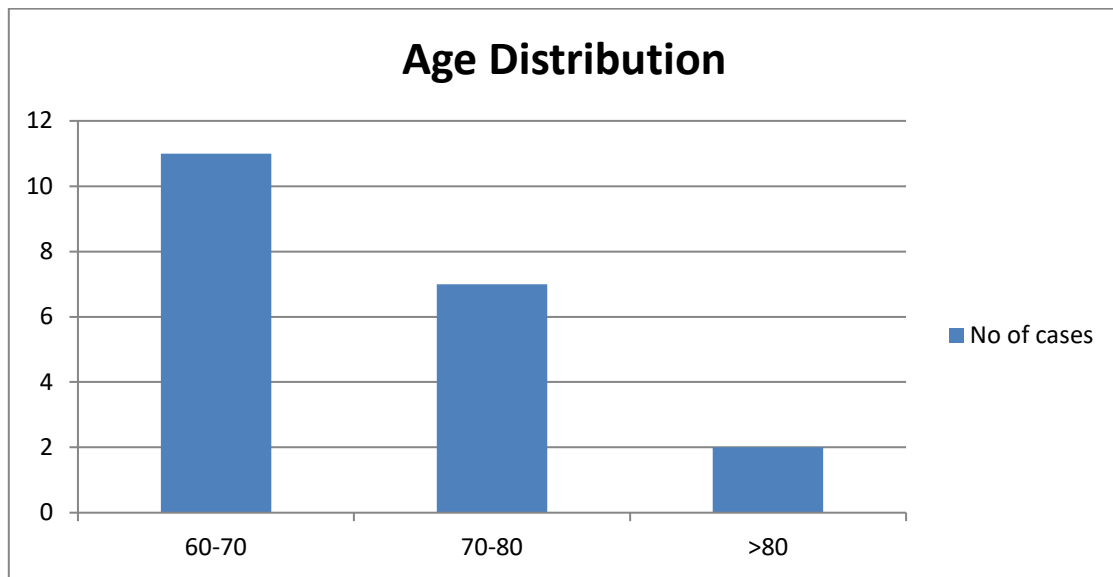


TABLE 2: SEX DISTRIBUTION

SEX	NO OF CASES	% OF PATIENTS
MALE	8	40%
FEMALE	12	60%

Graph 2: Sex Distribution

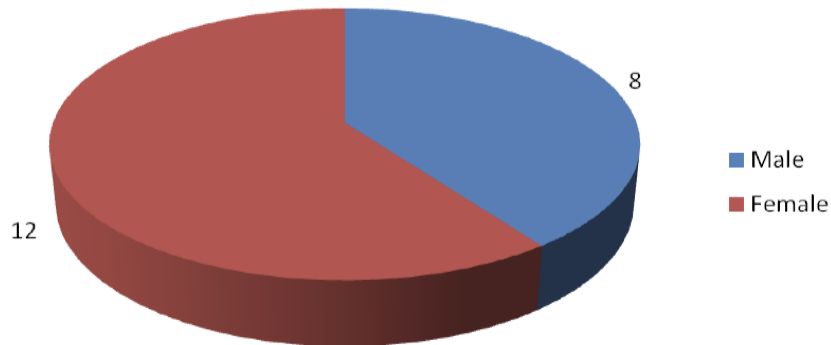


TABLE 3: SIDE OF INJURY

SIDE INVLOVED	NO OF CASES	% OF PATIENTS
RIGHT	12	60%
LEFT	8	40%

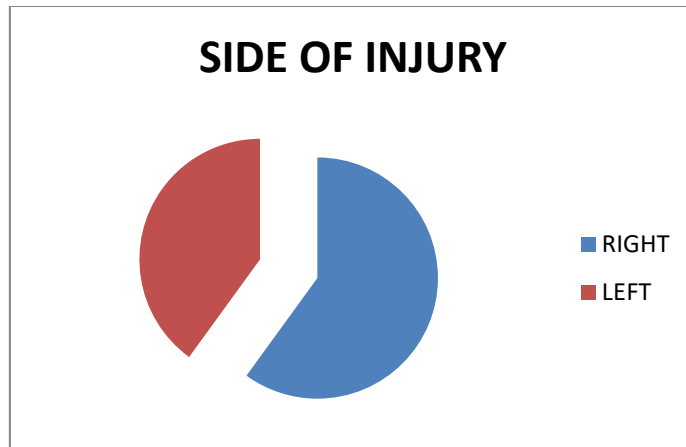


TABLE 4: TYPE OF FRACTURE

TYPE OF FRACTURE (AO/OTA)	NO OF CASES	% OF PATIENTS
A2.1	4	20%
A2.2	9	45%
A2.3	5	25%
A3.3	2	10%

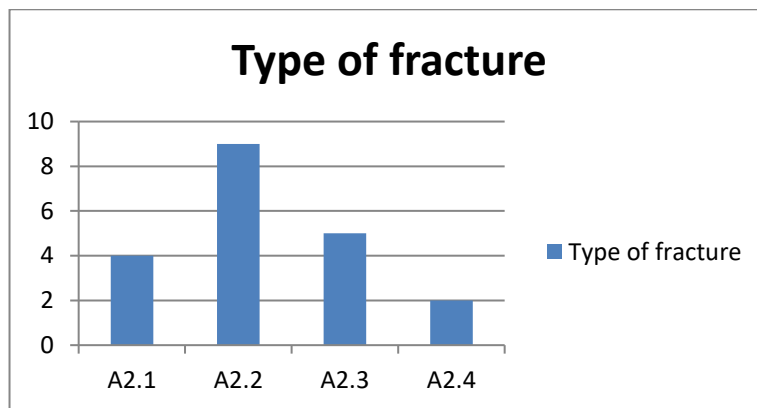


TABLE 5: Size of prosthesis

Size of the Prosthesis	No. of Patients	Percentage (%)
41mm	2	10
43mm	4	20
45mm	8	40
47mm	4	20
37mm	1	5
39mm	1	5

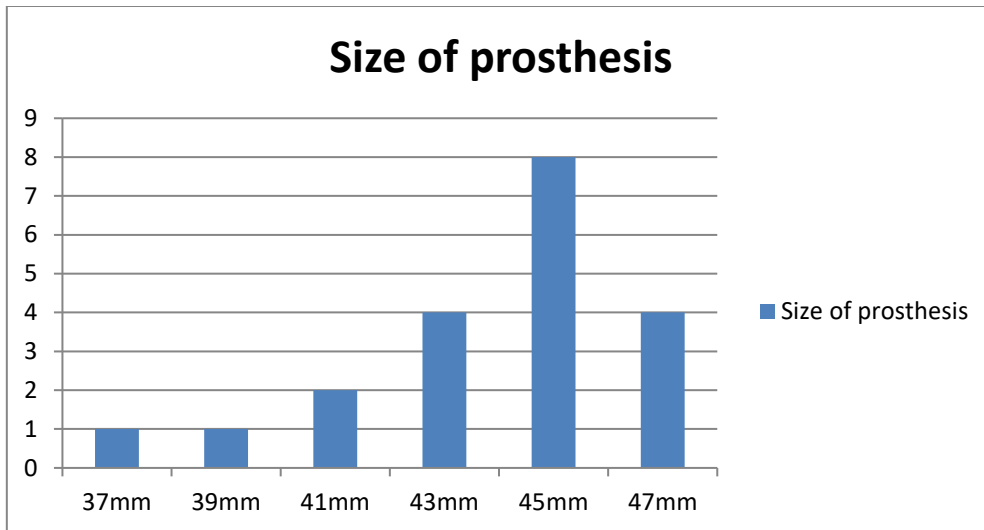


TABLE 6 :FOLLOW UP WITH HARRIS HIP SCORE

AVERAGE HARRIS HIP SCORE AT FOLLOWUP	SCORE
6 WEEKS	68
3 MONTHS	72
6 MONTHS	78
1 YEAR	86

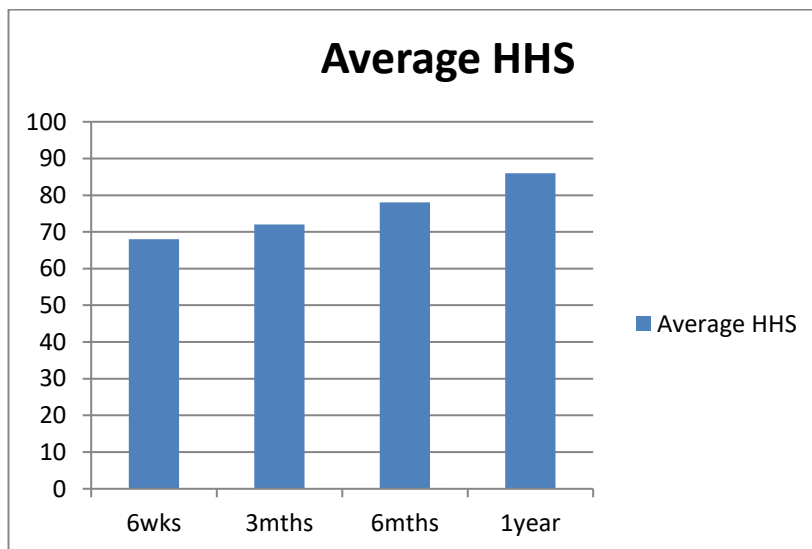


TABLE 7: FUNCTIONAL EVALUATION WITH HARRIS HIP SCORE

SCORE	No of cases	Percentage
Excellent (90-100)	8	40%
Good (80 -90)	10	50%
Fair (70-80)	2	10%
Poor (60-70)	0	0
Total	20	100

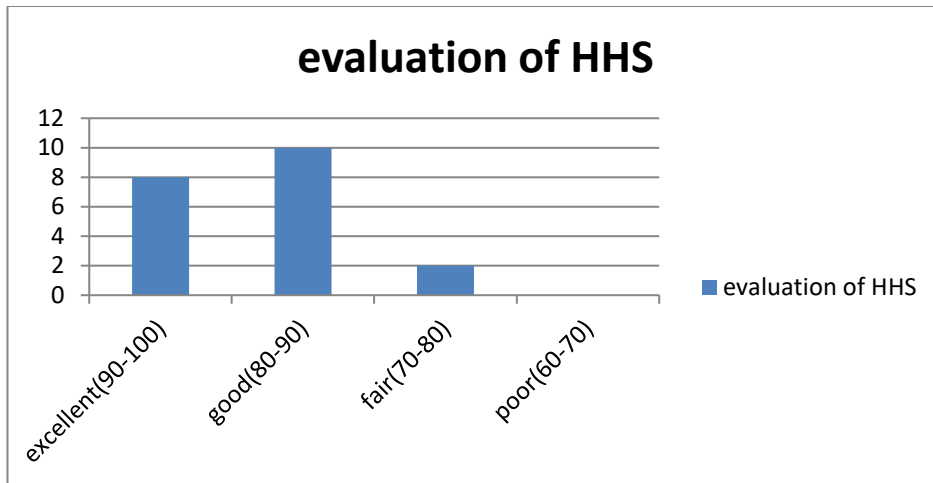


TABLE 8: POST OPERATIVE COMPLICATIONS

Complication	No of cases
Cardio vascular	0
Pulmonary complication	0
Superficial wound infection	2
Deep wound infection	0
Deep vein thrombosis	0
Pressure sores	0
Prosthetic/fixation failure	0

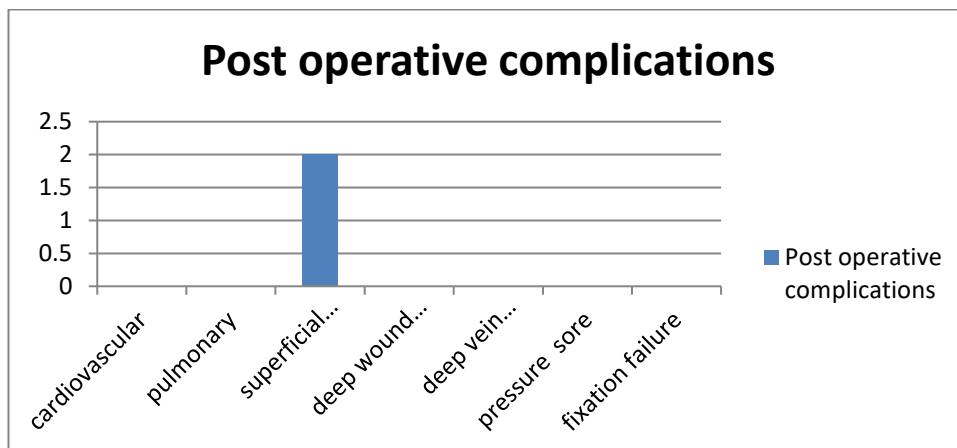
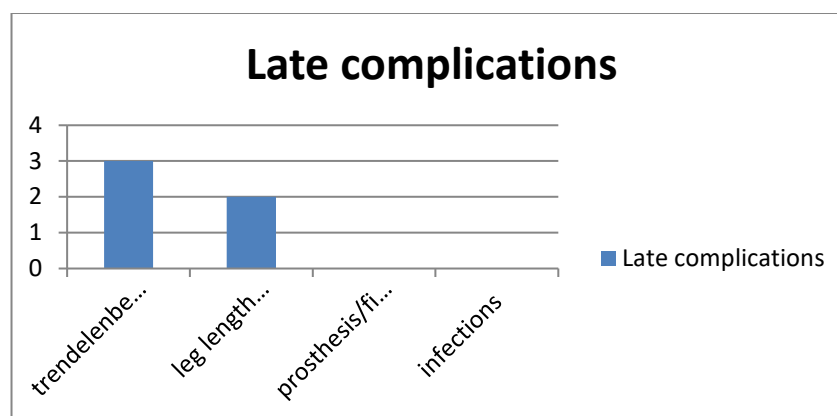


TABLE 9: LATE COMPLICATIONS

COMPLICATIONS	NO OF CASES
TRENDELENBURG gait	3
Leg length discrepancy (>1 cm)	2
Prosthesis /fixation failure	0
Infections	0



DISCUSSION

Fractures of intertrochanteric femur have been recognized as a major challenge by the Orthopaedic community, not solely for achieving fractures union, but for restoration of optimal function in the shortest possible time that to with minimal complications. The aim of management accordingly has drifted to achieving early mobilization, rapid rehabilitation and quick return of individuals to premorbid home and work environment as a functionally and psychologically independent unit. Most of patients in present study were from age group of 6th to 7th decade of life . This signifies the fact that patients from these age groups are involved in low energy trauma like domestic fall. ^{3,12} Conducted study on elderly patients (average age ,82.2 years) with unstable intertrochanteric hip fractures treated with a bipolar head- neck replacement. Seventeen patients had the prosthesis inserted as primary fracture management and three for salvage of failed internal fixation. The patients were ambulated with unrestricted weight bearing at an average of 5.5 days after the operation. They have taken the greater trochanter as a landmark for precise placement of the femoral head so as to achieve correct limb length and concluded that the bipolar design may permit conversion to a total hip arthroplasty without removal of the femoral component, and may reduce the risk of acetabular cartilage damage¹². ⁶Conducted prospective study on 41 patients (22 females and 19 males – all were 65 years old or above) who had bipolar arthroplasty for unstable intertrochanteric fractures. Modified lateral approach was used in all patients. Harris hip score (HHS) used for clinical evaluation .follow up period ranged from 12 to 24 months. During the last follow up, the harris hip score ranged from 93 to 51 with a mean value 78.19. four cases (9.76%) were excellent, 16 cases (39.02%) good , 16 cases (39.02%) fair and 5 cases (12.02%) poor. The complications in this study were one patient had infection , one had dislocation , one had stem subsidence , one had acetabular wear, one had intraoperative crack during insertion of femoral stem⁹.. In present study on 20 elderly patients with unstable intertrochanteric fractures treated with cemented bipolar hemiarthroplasty, out of which were males 8 and 12 were females. Out of them 8 had left hip fractured and 12 had right hip fractured. The average age of patients was 68.82 years¹³. Prospectively analysed the role of primary bipolar arthroplasty or total hip arthroplasty for the treatment of intertrochanteric fracture femur in elderly and concluded that although it may appear to be equally good results in both groups , in elderly patients ,however , the choice should fall for bipolar hemi-arthroplaty than for total hip replacement as there is more chance of dislocation in total hip replacement⁶. It should however be noted that a larger randomized trial , with higher number of patients , or multicentric trial can improve the interpretation of the results ¹⁴ . Conducted a prospective study on cemented bipolar hemiarthroplasty in unstable osteoporotic fractures of intertrochanteric femur in elderly patients and observed that primary hemiarthroplasty provides stable pain free mobile joint and is a better modality of treatment in unstable osteoporotic inter trochanteric fractures. Early mobilization is possible avoiding the problems of recumbency.¹⁵

CONCLUSION

Cemented bipolar hemi-arthroplasty is a technically challenging procedure which requires a reasonable learning curve. But a properly performed procedure is a viable option for unstable trochanteric fractures in very elderly osteoporotic patients. The procedure offered, faster mobilization, rapid return to preinjury level, improved the quality of life and gave a long term solution in elderly patients with intertrochanteric fractures of the femur. Bipolar hemiarthroplasty reduced the complications of prolonged immobilisation, prolonged rehabilitation, marked residual deformities and need for revision surgeries. In conclusion primary cemented bipolar hemiarthroplasty in comminuted intertrochanteric fractures in elderly patients provides painless stable joint allowing the patients to ambulate early in the post operative period, minimizing the complications associated with prolonged recumbency. Complications that occur as a part of proximal femur nail or plate fixation such as implant penetration into the joint space, Z effect, reverse Z effect, not able to achieve the anatomical reduction and fracture going into non union, all these are avoided by opting for the hemiarthroplasty in elderly patients. This study concludes that primarily the cemented bipolar hemiarthroplasty can be considered as one of the main treatment options in comminuted intertrochanteric fractures in elderly patients.

References

1. Kyle RF, Gustillo RB, Premer RF. Analysis of six hundred and twenty two intertrochanteric hip fractures. *J Bone JtSurg* 1979;61-A:216.
2. Zuckerman JD. Hip fractures. *N Engl J Med* 1996;334:1519.
3. Mariani Eon, Rand JA. Nonunion of intertrochanteric fractures of the femur following open reduction and internal fixation. *ClinOrthopRelat Res* 1987; 218:81.
4. Haentjens P et al. Treatment of unstable intertrochanteric and subtrochanteric fractures in elderly patients. *J Bone JtSurg* 1989;71-A:1214.
5. Harwin SF, Stern RT, Kulick RG. Primary Bateman – leinbach bipolar prosthetic replacement of the hip in the treatment of unstable intertrochanteric fractures in the elderly. *Orthopedics* 1990; 13: 1131.
6. GU Gui-shan, WANG Gang, SUN Da-hui, QIN Da-ming and ZHANG Wei. Cemented bipolar hemiarthroplasty with a novel circlage cable technique for unstable intertrochanteric hip fractures in senile patients. *Chin J Traumatol* 2008; 11(1): 13-17.
7. Rodop O, Kiral A, Kaplan H, Akmaz I. Primary bipolar hemiprosthesis for unstable intertrochanteric fractures. *IntOrthop* 2002; 26(4): 233-7.
8. Sanjay K Gupta, V.P.Pathania, Maneesh Sharma "Primary modular bipolar hemiarthroplasty for unstable osteoporotic intertrochanteric fractures in elderly" *Journal of evolution of medical and dental science* 2014; Vol3, issue 12, March 24; page 3148-3153, DOI:10.14260/jemds/2014/2258
9. Ahmed Elmorsy, Mahmoud saied. Primary bipolar arthroplasty in unstable intertrochanteric fractures in elderly. *Open journal of orthopaedics*, 2012, 2, 13-17
10. Jagadeesh Kumar Jayalapan, Parthasarathy Pandian, Unstable intertrochanteric fractures in elderly treated with cemented bipolar hemiarthroplasty. *Journal of evidence based medicine and healthcare*; volume 2, issue 26, June 29, 2015; page 3905-3913
11. Choudhari Pradeep, Agarwal Anuj, Gurjar Abhishek; Treatment of comminuted unstable intertrochanteric fracture in elderly patients with cemented bipolar prosthesis; *Indian Journal of Orthopaedics surgery* 2015; 1(4); 255-260
12. Green S, Moore T, Proano F. Bipolar prosthetic replacement for the management of unstable intertrochanteric fractures in elderly, *ClinOrthoRelat Res* 1987; 224; 169-177.

13. DrAtulPatil ,DrMuqtadeer Ansari, DrAdityaPathak, Dr A B Goregaonkar. Dr C J Thakker, Role of cemented bipolar hemiarthroplasty for comminuted intertrochanteric femur fracture in elderly osteoporotic patients through a modified transtrochanteric approach SION hospital modification. IOSR Journal of dental and medical sciences(iosr-jdms) e ISSN 2279-0853;p-ISSN 2279-0861.VOL 9 ISSUE 4 (SEP-OCT2013; PG 40-47.
14. Jaswinder pal singhwalia, Dheerajsansanwal, Sonamkaurwalia, Sargunsingh, Avinashchandergupta. Role of primary bipolar hemiarthroplasty or total hip arthroplasty for the treatment of intertrochanteric fracture femur in elderly. Journal of orthopaedicsvol 12 no 1201. Page 5-9
15. DrMilind Ingle, DrUlhas sonar, Dr M R Koichade, DrAvinashYelne, DrAshishRadke. Cemented bipolar hemiarthroplasty in unstable osteoporotic fractures of intertrochanteric neck femur in elderly patients : a prospective study. Indian journal of basic and applied medical research ; june 2014: vol 3, issue 3, p 85-94