

ORIGINAL RESEARCH

Outcome of communitied intra articular fractures of distal tibia treated with external fixator

**Rajkumar Indrasen Suryawanshi¹, Deepak Bhimraj Datrangle²,
Swapnil Bhaskarrao Mahale³**

¹Professor and HOD Department of Orthopaedics, MPGIMER, Maharashtra Post Graduate Institute of Medical Education and Research, MUHS, Nashik ,422001, Maharashtra, India.

²Associate Professor, Department of Orthopaedics, MPGIMER, Maharashtra Post Graduate Institute of Medical Education and Research, MUHS, Nashik 422001, Maharashtra, India.

³Senior Resident, Department of Orthopaedics, MPGIMER, Maharashtra Post Graduate Institute of Medical Education and Research, MUHS, Nashik 422001, Maharashtra, India.

ABSTRACT

Background: The tibial intra-articular fracture refers to soft tissues envelope and often known as pillion fracture. The goal of treatment involves healed, well-aligned, functional range of motion of ankle joint. To offer the treatment the approach of fracture reduction has been successful in treating the complex fracture.

Aim: The research paper aims to analyze the outcome of communitied intraarticular fractures of distal tibia treated with an external fixator.

Material and Methods: The current study is an observational study that is being conducted in....from..... For the study, the researcher has selected 30 people that involve 23 males and 7 females. The mean age of these participants was 53 years (range between 26-72 years). The patients were selected focusing on the inclusion and exclusion criteria.

Results: The clinical result of study involves the mean score of 81.5 points that range between 58-100. The first requirement of arthrodesis of the ankle and this patient scored 9 points for reduction quality. The clinical results have identified that the patient was facing the issues related to A5 valgus deformity that also occurred with diabetes. The consideration of results focusing on the approach of external treatment was found good and applied for the other clinical studies of the patients.

Conclusion: From the study, it has been carried out that that external fixator treatment for communitied intraarticular fractures of the distal tibia is beneficial and having a positive impact on the process of offering the required support to the patients.

Keyword: tibial intra-articular fracture, communitied intraarticular fractures,external fixator,outcome.

Corresponding Author: Dr. Rajkumar Indrasen Suryawanshi, Professor and HOD Department of Orthopaedics, MPGIMER, Maharashtra Post Graduate Institute of Medical Education and Research, MUHS, Nashik ,422001, Maharashtra, India.

Email: rajkumarsuryawanshi59@gmail.com

INTRODUCTION

The tibial intra-articular fracture refers to soft tissues envelope and often known as pillion fracture. In such case an anatomic realignment of involved articular fracture in conjunctions with stable fixation is crucial. The major cause of this type of injury involves low energy and rotational forces as well as the position of the foot movement. [1] This type of injury requires careful management of the soft tissues and appropriate system for reduction. The clinical assessment of the injury is essential for managing the issues and proper fixing of the bones.

The process of fixing such fracture is involving the various modalities like soft tissue dehiscence, reduction of articular fragmentation with stable fixation through external devices. The use of olive wires enables the multi-directional forces to apply for the reduction of the spiral fracture. In the treatment of fracture of the distal part of the tibia, care professional need to provide extra care as it involves a small group of fracture which cause difficulty in management and classification.

Tibia is the major weightbearing bone of the leg and open fractures are most common in this area of the body. [2] The treatment of distal tibia fracture often results in several complications including malunion, non-union and ankle surface. The operative treatment of the tibial fracture is caused by high energy trauma and early motion of the tissues. The goal of treatment involves healed, well-aligned, functional range of motion of ankle joint.

To offer the treatment the approach of fracture reduction has been successful in treating the complex fracture. The main objective of this technique is to apply stable plate fixation while maintaining the fracture biology and maintaining the soft tissue problem. In the current scenario, the trends towards using the locking plates are beneficial for managing the distal part of the tibia. [3] The locking plates have the biomechanical properties of internal and external fixation that provide the superior holding power and fixed angular holding.

In addition to this, the new techniques of treatment of such fracture involve the Minimally invasive percutaneous plate osteosynthesis which aims to minimal periosteal dissection and disruption of hematoma, stable anatomical fixation and early mobilization. These kinds of treatment techniques are having a significant impact on managing the highenergy fracture of the distal tibia. The research will provide the information related to the outcome of the intraarticular fracture of distal tibia treatment with an external fixator. [4]

This kind of injuries is challenging because of its subcutaneous location and precarious blood supply and proximity to the ankle joint. The proper analysis of injury and implementation of the treatment plan helps manage the issues and provide better care services to the patients. The initial radiography is required for determining the particular fracture pattern that could associate with the injury. The IM nailing has reported with higher rates of mal-union because nail cannot provide the tight fit at the distal fracture site and affect the process of offering the treatment. [5]

AIM AND OBJECTIVE

OBJECTIVES:

1. Study Clinical profile of tibial intra-articular fracture
2. Outcome of communited intra articular fractures of distal tibia treated with external fixator.

MATERIAL AND METHODS

Study design: A cross sectional study

Place of study - Tertiary health care centre

Study of group: Patients with open and closed fractures.

Sample size:30

Inclusion criteria:

1. Patients of age group 20 to 60 years.
2. Patients with open and closed fractures.

Exclusion criteria:

1. Patients with vascular injuries.
2. Patients with pre-existing deformity of tibia.
3. Patients with associated tarsal bone fractures.

Approval for the study:

Written approval from Institutional Ethics committee was obtained beforehand. Written approval of Medicine and Related department was obtained. After obtaining informed verbal consent from all patients with the definitive diagnosis of End-stage Renal Disease admitted to Medicine ward of tertiary care centre such cases were included in the study.

Sample Size: 26

Sampling technique: Convenient sampling technique used for data collection. All patients admitted in the orthopedic department of tertiary care center with tibial intra-articular fracture were included in the study.

Methods of Data Collection and Questionnaire-

Pre-designed and pretested questionnaire was used to record the necessary information. Questionnaires included general information, such as age, sex, religion, occupation, residential address, and date of admission, Medical history- chief complain, past history, general examination, systemic examination

Data on demographic profile of acute poison patient, investigation, personal history, medical past history, treatment modalities, and clinical outcome data collected from patients admitted in orthopedic ward. All the procedures and investigations conducted under direct guidance and supervision of pg guide.

Data entry and analysis:

The data were entered in Microsoft Excel and data analysis was done by using SPSS demo version no 21 for windows. The analysis was performed by using percentages in frequency tables and $p < 0.05$ was considered as level of significance using the Chi-square test

RESULTS AND OBSERVATIONS

For the current study, the researcher has used the observation and opinion method for analyzing the data collected from the different participants. The clinical outcome of the study involves the accuracy of reduction score mean points and external fixator.

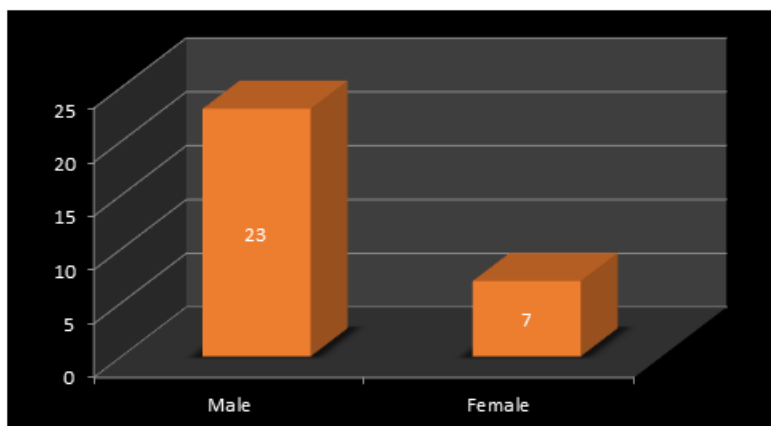


Figure 1: Distribution of cases according to sex

Majority of cases were Male 23 and 7 female

Table 1: Quality of reduction

Variable	Points	frequency
Anatomic	8 points	7 cases
Good	9-11 points	22 cases
Fair	12-15 points	1 case
Poor	<15 points	0

Table 2: Clinical rating

Variable	Points	frequency
Anatomic	>92	7 cases
Good	87-92	8 cases
Fair	65-86	3 cases
Poor	<65	1 case

There were no diagnose for deep venous thrombosis and superficial pin tract infection was presented in the identified cases. The infection at 3 pin sites from the distal tibia ring was encountered in two cases and replaced with the wire and screw. The clinical result of study involves the mean score of 81.5 points that range between 58-100. The first requirement of arthrodesis of the ankle and this patient scored 9 points for reduction quality. The development of stiff ankle with equines of the foot from interruption of physiotherapy has helped to maintain the high standards in the treatment.

The hospitals are following a myocardial infarction for analyzing the impact and recovery of the patients. However, the 34-year-old man with 43 C3 and the diaphyseal fracture was treated with the wire and plates to manage the issues. Moreover, the second poor result was 55 years old male who was addicted to smoke and it has affected the recovery process. The clinical results have identified that the patient was facing the issues related to A5 valgus deformity that also occurred with diabetes. The consideration of results focusing on the approach of external treatment was found good and applied for the other clinical studies of the patients.

DISCUSSION

For managing the intraarticular fractures of the distal tibia is having a significant impact on the body function of the individual. The study has identified issues and approaches of treatments to identify the impact of the external fixator. According to Beytemür et al., (2017), the open reduction and internal fixation (ORIF) has led to variable results for high energy distal tibia. [6]

The reduction is stable and having a direct impact on the approaches of treatment offered to the different age people. As per the finding, 74% of cases were good and less than 5% of people found with an infection that influences the healing. [7]

However, without complications of deep infection and consideration of articular restoration can be beneficial for gaining a favourable outcome for the patients. The external fixation is allowing the care professionals to manage the fracture in 10-14 days by fixing the soft tissues and periosteum. This kind of approach is helpful for the stable reduction and reported that 55% of patients have achieved good results by applying this technique.

However, Aurich, Koenig, and Hofmann, (2018) have stated that internal osteosynthesis of the tibia was performed in 56% cases and founded that greater infection rate. The lack of

external support and lack of prevention of the soft tissues is hurting the recovery process of an individual. [8]

The quality of reduction and clinical outcome of the fracture group is having a radiography therapy for managing the issues that are helping to improve the situation. For stable and healing of distal tibia, the patient needs to focus on the weight and physical activities. As per the views of Yoon et al., (2015), the B4 and B3 types of fracture patients are facing serious issues for improving the health. These kinds of fractures are treated with the only external fixator. [9]

The proper stabilization with rod and interior angulations that varying from 5 to 25 and can help provide effective care to the patients. Their rotational process for managing the external fixator is helpful for the natural position at the moment of impact. The low energy trauma and the fracture pattern is having a significant impact on the clinical treatment and management of the soft tissues and early fixation. This kind of treatment approach is useful for weight-bearing. However, the external fixator is having skin damage and secondary infection caused by the high energy trauma that influences the result of treatment and tibia shaft fracture.

The poor results of internal treatment and lack of satisfaction among the patient is influencing the demand for external fixator treatment. [10] The report has identified that the development of stiff ankle with equines of the foot from interruption of physiotherapy has helped to maintain the high standards in the treatment. The infection at 3 pin sites from the distal tibia ring was encountered in two cases and replaced with the wire and screw. In addition to this, joint surface resulting in forwarding dislocation and healing and setting the right position for increasing the stability.

CONCLUSION

From the study, it can be considered that external fixator treatment for communitied intraarticular fractures of the distal tibia is beneficial and having a positive impact on the process of offering the required support to the patients. The proper analysis of health conditions of individual and treatment helps manage the operations

REFERENCES

1. Sitnik A, Beletsky A, Schelkun S. Intra-articular fractures of the distal tibia. *EFORT Open Rev.* 2017;2(8):352–61. doi:10.1302/2058-5241.2.150047.
2. Pi ątkowski K, Piekarczyk P, Kwiatkowski K, Przybycien M, ́ Chwedczuk B. Comparison of different locking plate fixation methods in distal tibia fractures. *Int Orthop.* 2015;39(11):2245–51. doi:10.1007/s00264-015-2906-4.
3. Korobeinikov A, Popkov D. Use of external fixation for juxta-articular fractures in children. *Injury.* 2019;50:S87–S94. doi:10.1016/j.injury.2019.03.043.
4. Francesco P, Paolo S, Filippo C, Francesco C, Enrico V. When is indicated fibular fixation in extra-articular fractures of the distal tibia? *Acta Biomed.* 2018;89(4):558–63.
5. Prat-Fabregat S, Camacho-Carrasco P. Treatment strategy for tibial plateau fractures: an update. *EFORT Open Rev.* 2016;1(5):225–32. doi:10.1302/2058-5241.1.000031.
6. Beytemür O, Barı ę A, Albay C, Yüksel S, aglar S, Alagöz E. ˘ Comparison of intramedullary nailing and minimal invasive plate osteosynthesis in the treatment of simple intra-articular fractures of the distal tibia (AO-OTA type 43 C1-C2). *Acta Orthop Traumatol Turc.* 2017;51(1):12–6. doi:10.1016/j.aott.2016.07.010.
7. Lovisetti G, Agus MA, Pace F, Capitani D, Sala F. Management of distal tibial intra-articular fractures with circular external fixation. *Strategies Trauma Limb Reconstr.* 2009;4(1):1–6. doi:10.1007/s11751-009-0050-7.

8. Aurich M, Koenig V, Hofmann G. Comminuted intraarticular fractures of the tibial plateau lead to posttraumatic osteoarthritis of the knee: current treatment review. *Asian J Surg.* 2009;41(2):99–105.
9. Yoon RS, Bible J, Marcus MS, Donegan DJ, Bergmann KA, Siebler JC, et al. Outcomes following combined intramedullary nail and plate fixation for complex tibia fractures: A multi-centre study. *Injury.* 2015;46(6):1097–1101. doi:10.1016/j.injury.2015.03.019.
10. Shakti SP, Damodar P, Nikhil S. Supracutaneous plating: Use of locking compression plate as external fixator for intra-articular compound fractures. *Health Sci.* 2016;5(8):62–7.