

# CORONAVIRUS TRANSMISSION THROUGH OCULAR SECRETION: A REVIEW OF CORONAVIRUS ANDOCULAR MANIFESTATIONS

NugrahaWahyuCahyana

Department of Ophthalmology, Faculty Medicine, Jember University, Jember

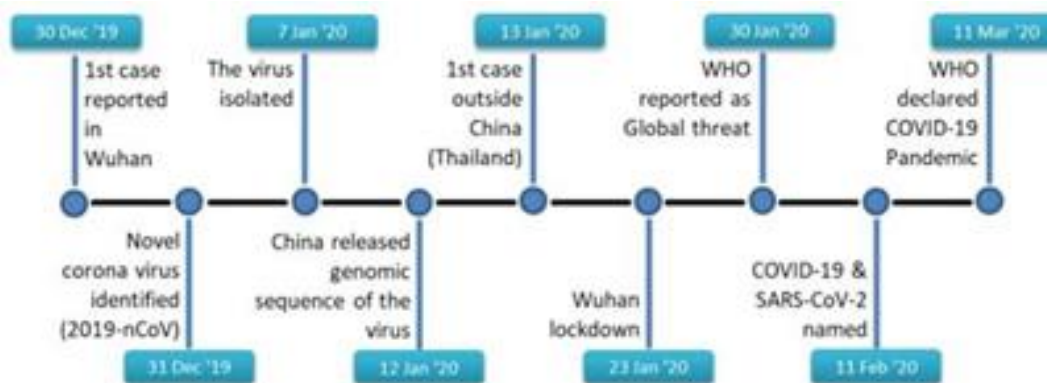**Abstract** -COVID-19 (Corona Virus Diseases-2019) is the newest global pandemic caused by SARS-CoV-2 (Severe Acute Respiratory Syndrome Coronavirus-2). This article aims to study the relationship between COVID-19 and the conjunctival swab test systemically. This article is based on several scientific reports related to conjunctival swab performed in COVID-19 patients from the PUBMED database, Google Scholar, Springer Link, Elsevier, medRxiv, bioRxiv, and Wiley Online Library. Keywords used are conjunctivitis, ocular, ophthalmic, COVID-19, SARS-CoV-2, 2019-nCoV, Coronavirus, Coronavirus-19, Coronavirus19, pathophysiology, mechanisms, tear, conjunctival swab, RT-PCR, and conjunctiva. Eight reports were reviewed in this article. Respiratory symptoms and ocular manifestation such as conjunctivitis with hyperemic eyes, conjunctival chemosis, epiphora, and other rare ocular manifestations were observed in COVID-19 patients. Ocular manifestation may present as a sole symptom, prodromal symptom, simultaneously appear with the systemic symptom, or as residual floaters. Various therapy was given according to the complaints. RT-PCR results from the conjunctival swab test may be positive and negative in COVID-19 patients with conjunctivitis. From this article, we hope to highlight the importance to take optimal prevention measures for medical staff despite the presence or absence of ocular clinical manifestation.

**Keywords:** COVID-19, ocular manifestation, conjunctival swab

## INTRODUCTION

COVID-19 (Corona Virus Disease-2019) is caused by the new variant of the SARS virus known as SARS COV-2 (Severe Acute Respiratory Syndrome- Coronavirus-2). It shows in Wuhan, Hubei Province for the first time in 2019.<sup>[1,2]</sup> On December 30th, 2019, dr. Li Wenliang, an Ophthalmologist was giving a warning to his colleagues about a SARS-like-symptom observed in Wuhan, allegedly related to the local market activities.<sup>[3]</sup> The mortality rates in this virus-related disease increased sharply around the world, that WHO declared this as a state of international public health emergency on January 30th, 2020, and as a global pandemic on March 11th, 2020 can be seen in Figure 1 respectively.<sup>[4,5]</sup> Until July 12th, 2020, the total confirmed case worldwide was 12.552.765, with 561.617 death. The chronological diagram of COVID-19.<sup>[6]</sup>

**Figure 1. The initial chronology of the appearance of COVID-19 until the status of a pandemic is declared by WHO<sup>[5]</sup>.**



SARS COV-2 is a family of beta-CoV, which is known to induce a systemic manifestation such as severe respiratory disorder in humans and mammals. This family virus type has already been involved in two previous pandemics, the SARS (*Severe Acute Respiratory Syndrome*) in 2003 and MERS (*Middle Eastern Respiratory Syndrome*) in 2012.<sup>[7-9]</sup> It has the largest single RNA strand with a diameter of less than 60-140 nm with around 30.000 nucleotides.<sup>[10,11]</sup> The main transmission route is through droplets and direct contacts, although the asymptomatic patient may also be able to transmit this virus.<sup>[12]</sup> This virus also is reported to stay active on the material surface, such as stainless steel and plastic materials for 72 hours, less than 24 hours on the carton, and less than 4 hours on copper material.<sup>[1]</sup>

Previously, HCoV-NL63, a type of Human Corona Virus (HCoV), was the only identified virus that was confirmed to induce eyes' infection especially conjunctivitis through an unknown mechanism.<sup>[13]</sup> There are no reports of eyes symptom both in SARS-CoV and MERS-CoV.<sup>[3]</sup> In the COVID-19 case, there are some reports about ocular manifestation through the conjunctiva transmissions confirmed with RT-PCR (*Reverse Transcriptase-Polymerase Chain Reaction*) swab test and various method of therapy were given.<sup>[14-16]</sup> The purpose of this review is to identify the information related to the COVID-19 ocular manifestation, therapy, the relationship with systemic manifestation, and the role of the conjunctiva swab PCR test to deliver a best clinical practice recommendation for this period time.

## METHODS

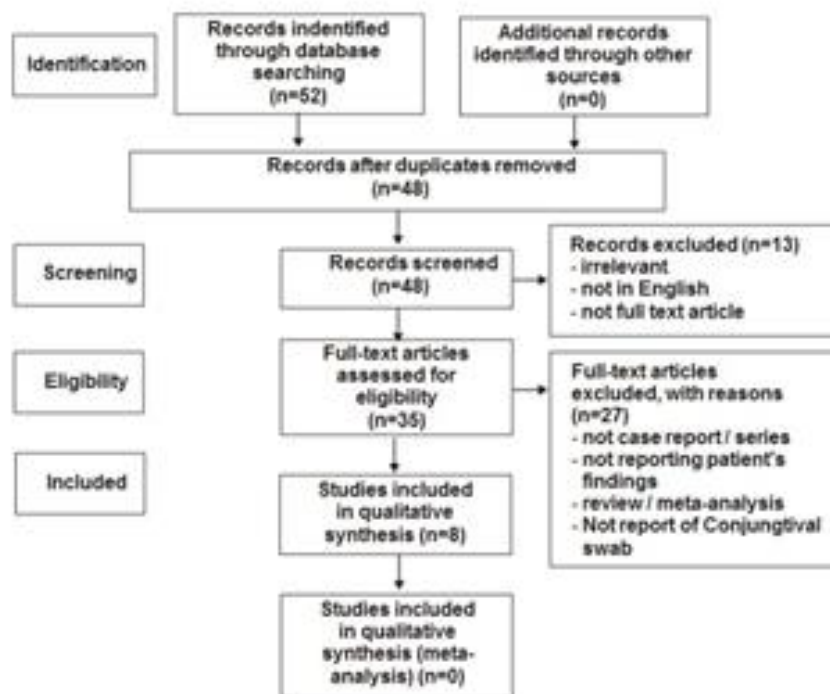
This review was conducted in July 2020 through several databases, which are PUBMED, Google Scholar, Springer Link, Elsevier, medRxiv, bioRxiv, and Wiley Online Library. The keywords used were conjunctivitis, ocular, ophthalmic, COVID-19, SARS-CoV- 2, 2019-nCoV, Coronavirus, Coronavirus-19, Coronavirus19, pathophysiology, mechanisms, tear, swab conjunctiva, PCR, and conjunctiva. The article will be selected purposely based on the clinical manifestation of SARS-COV-2 in the ocular, therapy, relationship with systemic manifestation, and the role of conjunctiva swab PCR test. It will be processed through qualitative review from several documents according to PRISMA recommendation. We chose the published article in English that reported the ocular manifestation in COVID-19 patients. Case report, case series, cohort study, and cross-sectional study were included in the article we chose. We excluded the review or meta-analysis article, non-full text article, article without the patient's clinical manifestation, and non-English article. Ethical clearance was not needed, and the result will be reported following the terms of *Preferred Information Elements for Systematic Testing and Meta-Analyses* (PRISMA).<sup>[17]</sup>

## RESULTS

From a systematic look out through a decided approach, we have collected 52 articles from the electronic database. After being filtered, 4 articles were excluded because of duplicate titles and abstracts; 13 articles were irrelevant, not in full-text format, and not in English; 23 articles were a review article or meta-analysis, and case report, case series, cohort studies, and cross-sectional. Only 8 articles fulfilled the requirement of this study, which consisted of 2 case reports, 2 case series, 2 cohort study, and 2 cross-

sectional studies about ocular manifestation in COVID-19 patients can be seen in Figure 2. Almost all articles mentioned ocular manifestation specifically or generally in COVID-19 patients, the relationship between ocular and systemic manifestation, the results of nasopharyngeal and conjunctiva swab, also the given therapy. All of this information was extracted and summarized in Table 1.

**Figure 2. PRISMA Systematic Review<sup>[17]</sup>**



In this review, there are several reports of ocular manifestation in COVID-19 patients. The majority reports conjunctivitis, with hyperemic conjunctiva, clear secretion, foreign object sensation, overflow of tears or epiphora, and conjunctival chemosis. The appearance was specifically pointed to viral conjunctivitis, moreover, a specific conjunctival follicle was spotted.<sup>[18,19]</sup> However, there are several unreported manifestations of hemorrhagic conjunctiva, such as petechiae, tarsal hemorrhage, and chemosis. In the same patient, the hallmark of severe adenovirus infection; pseudomembrane, sticky secretion around eyelashes, and superficial punctate keratitis were also spotted.<sup>[20]</sup> Hyperemic dry eyes, itchy eyes, even floaters symptoms were discovered after the treatment ended.<sup>[21,18]</sup> Cheema, *et al* reported the findings of herpetic keratoconjunctivitis with photophobia, edema palpebra, mucoid secret, conjunctiva injection, follicle, small pseudodendritic inside the inferior temporal cornea, and small subepithelial infiltration (0,2 mm) with epithelial damage superior to temporal limbic. These symptoms were developed into epidemic keratoconjunctivitis accompanied with ipsilateral lymphadenopathy, widening infiltrate, diffuse epithelial damage, and significant decrease vision (20/40), with pinhole correction change to 20/30.<sup>[19]</sup> Not all COVID-19 patients experienced ocular manifestations.<sup>[3,8]</sup> Scalinci, *et al.* dan Xia, *et al.*, reported that these ocular manifestations with symptoms were observed in the positive COVID-19 patient confirmed through nasopharyngeal swab test without other systemic manifestations, such as fever and acute respiratory disorder. Simply, these ocular manifestation is the single complaints of the patient.<sup>[14,21]</sup> Conjunctivitis may also be found as a prodromal symptom before systemic manifestation occurs.<sup>[2,5,20]</sup> These ocular symptoms may show up at the same time with mild systemic symptoms, such as fever, cough, and flu in several cases.<sup>[7,8]</sup> In another case, Navel, *et al.* dan Wu, *et al.* reported that the ocular manifestation showed up after the patient experienced moderate-severe acute respiratory syndrome with ventilator support.<sup>[15,18]</sup> One patient experienced floaters feeling after treatment ended.<sup>[6]</sup> Systemic manifestations reported in these reviews were fever, cough, sore throat, tonsil

enlargement, hemoptysis, sputum, rhinorrhea, nasal congestion, headache, fatigue, vomiting, stomachache, diarrhea, myalgia, arthralgia, rash, lymphadenopathy, pneumonia, acute respiratory syndrome, breathing difficulties, respiratory arrest, shock, kidney failure, multiple organ dysfunctions, rhabdomyolysis, even Disseminated Intravascular Coagulation (DIC).<sup>[10,11]</sup> The results of conjunctival swab RT-PCR examinations and their relationship to ocular manifestations in patients with COVID-19 vary widely. In some COVID-19 patients who were confirmed via nasopharyngeal swab test and complained of ocular symptoms when the conjunctival swab PCR examination showed results as in the belows:

**Table 1. : Ocular manifestations COVID-19 patients, ocular related to systemic manifestations, the results of nasopharyngeal swab and conjunctival swab test , and ocular therapy given.** <sup>[14, 15, 18, 19, 22-25]</sup>

Author	Article type	Title	Location	Population /Patient	Ocular Manifestations (Percentage)	Ocular Therapy	Relation with systemic manifestation	Nasofaring RT-PCR Swab	Conjunctiva RT-PCR Swab (Percentage)
Navel V,etal <sup>[18]</sup>	Case Report	Haemorrhagic Conjunctivitis with Pseudomembranous Related to SARS-CoV-2	France	63-year-old man who is positive for COVID-19	Day 17: Hyperemic conjunctiva and clear bilateral secretions (patient in ICU unit). Day 19: follicles, petechiae, tarsal bleeding, chemosis, pseudomembranes, sticky secretions around the lashes, and superficial punctate keratitis (patient in ICU unit)	Maintain eyelid hygiene , irrigation with saline and artificial tears. Azithromycin eye drops 2x / day for 3 days, dexametas at low doses and daily pseudomembranous debridement	Day 1: cough, flu myalgia, nausea and headache. Day 4: dispneu. Day 7: Transfer to ICU with a diagnosis of acute respiratory syndrome and pneumonia.	Swab test held on day 7 with a positive result (+).	Swab test held on day 17 and 20 but the results were negative 0%.
CheemaM,etal <sup>[19]</sup>	Case Report	Keratoconjunctivitis as The Initial Medical Presentation of The Novel Coronavirus Disease	Canada	29-year-old woman who tested positive for COVID-19	Day 1: unilateral mild conjunctivitis	Treated as keratitis conjunctivitis with valacyclovir 500 mg PO TID and	Day 1: patient also complained of rhinorrhea, cough, and nasal congestion. The patient denies the presence of fever the patient consumed	Swab test held on day 8 with a positive result (+).	Swab test held on day 6 with a negative result(-). 0%.

		2019 (COVID-19)				moxifloxacin	medicine containing antipyretic, so that the complaints of fever cannot be eliminated yet		
					Day 3: photophobia, palpebral edema, secretions. Mucoid secretion, small pseudodendritic in inferior temporal cornea, follicle, conjunctiva injection, and small subepithelial infiltrates (0.2 mm) with overlying epithelial damage in the superior temporal limbus. Vision Sharpness 20/20	1 drop of QID			
					Day 5: severe conjunctival injection, pain, ipsilateral preauricular lymphadenopathy, more subepithelial infiltrates with overlying epithelial damage. Vision Sharpness :20/20	Previous therapy was continued and diagnosed as epidemic keratoconjunctivitis			
					Day 6: decreased visual acuity 20/40 with pinhole to 20/30, ipsilateral and cervical preauricular lymphadenopathy, follicular conjunctivitis, conjunctival injection,	Valacyclovir was continued.			

					diffuse subepithelial infiltrates throughout the cornea with overlying epithelial damage				
Wu P, <i>et al.</i> <sup>[15]</sup>	<i>Case Series</i>	Characteristics of Ocular Findings of Patients With Coronavirus Disease 2019 (COVID-19) in Hubei Province, China	China	38 patients tested positive COVID-19	Twelve patients had ocular symptoms such as conjunctival hyperemia, chemosis, epiphora, and discharge 12/38 (31%).	Not reported	Based on PC-NCP guidelines: Ocular manifestations were found in 4 cases of moderate patients (fever and / or respiratory distress), 2 cases with severe degrees (symptoms and confirmation of CT-scan images), and 6 critical cases (severe dyspnea). with RR $\geq 30$ / min, SpO <sub>2</sub> $\leq 93\%$ , and PaO <sub>2</sub> / FiO <sub>2</sub> $\leq 300$ , respiratory failure / shock / multiple organ dysfunction. 1 patient developed epiphora as the first symptom of COVID-19	38 tested positive	2 of 12 Patients tested positive (+). 2/12 (16

Xia J, et al. <sup>[14]</sup>	<i>Cohort</i>	Evaluation of Ocular Symptoms and Tropism of SARS-Cov-2 in Patients Confirmed with COVID-19	China	30 patients tested positive COVID-19	1 Patient showed symptoms of viral conjunctivitis with conjunctival congestion and discharge. 1/30 (3.3%).	Not reported	The patient did not complain of fever or severe respiratory disorders	Swab test held 2 times within in the next 2 days and both tetsted positive results (+).	Swab test held 2 times within in the next 2 days and both tested positive results (+). 100%.
Hong N, et al <sup>[22]</sup>	<i>Cohort</i>	Evaluation of Ocular Symptoms and Tropism of SARS-Cov-2 in Patients Confirmed with COVID-19	China	56 patients tested positive COVID-19	15 patients had ocular manifestasion such as pain, discharge, dry eyes, itching, foreign substances, floaters, and hyperemia. 15/56 (27%).	Not reported	6 of these patients showed ocular manifestations as symptoms prodrome, 8 patients had concurrent systemic manifestations , and 1 patient complained of floaters after the treatment given.	56 tested positive (+)	1 of 15 tested positive (+). 1/15 (6,7%)
Zhang X, et al <sup>[23]</sup>	<i>Cross Sectional</i>	The Infection Evidence of SARS-COV-2 in Ocular Surface: A Single-Center Cross-Sectional Study	China	72 patients tested positive COVID-19	2 patients showed similar symptoms of hyperemic conjunctivitis, conjunctival congestion and fluid secretions. 2/72 (2.8%).	Gancyclovir drops	Both patients Shows ocular manifestation before systemic manifestation such as fever, cough and pneumonia	72 patients tested positive (+)	1 of 2 patients tested a positive (+) ½ (50%)
Güemes-villahoz, et al <sup>[24]</sup>	<i>Cross Sectional</i>	Detecting SARS-CoV-2 RNA in Conjunctival Secretions: Is It A Valuable	Spain	36 patients tested positive COVID-19	18 patients showed symptoms of conjunctivitis. reported 3 patients experiencing symptoms with bleeding	Not reported	One of systemic manifestation described was acute pneumonia. In patients with conjunctivals	36 patients tested positive (+)	Swab test on 18 patients presented with conjunctivitis 1 conjunctival positive

		Diagnostic Method of COVID-19			subconjunctiva, 2 patients had pterygium, 1 patient had red eyes associated with anti-glaucoma eye drops, 1 patient had hordeolum and 1 patient had pingueculitis that had previously occurred		swab test positive gained conjugtivitis had no complaints pneumonia		swab (5.6%), and on 18 non-conjunctivitis patients were also seen 1 conjunctival positive swab (5.6%).
Kumar K, et al <sup>[25]</sup>	Case series	Presence of Viral RNA of SARS-Cov-2 In Conjunctival Swab Specimens of COVID-19 Patients	India	45 Patients tested positive COVID-19	None of them shows manifestations ocular 0%.	Not reported	The systemic manifestations described include fever, cough, painful swallowing, and shortness of breath. 14 of them were asymptomatic	45 patients tested positive (+)	1 asymptomatic patient showed a positive result (+)

In other cases, patients with conjunctivitis were tested through conjunctiva swab and the result was COVID-19 positive.<sup>[14,17]</sup> A shocking revelation was an asymptomatic patient, ocular and systemic, showed COVID-19 positive result from conjunctiva swab.<sup>[8]</sup>

Several reports of conjunctivitis therapy in COVID-19 patients were reported, although quite many allegedly were not. Scalinci *et al.*, in their case reports, stated that the therapy given to conjunctivitis in COVID-19 was 4 times/day moxifloxacin eye drops for 5 days continuously.<sup>[21]</sup> Navel *et al.*, reported in a mild conjunctivitis case, the patient was instructed to keep the eyes area clean, irrigate with saline solution and artificial tears drop. Several days later, the symptoms worsen to hemorrhagic conjunctivitis with pseudomembrane, so the physicians prescribed azitromycin teardrops 2 times/day for three days, low dose dexamethasone, and daily debridement of pseudomembranes.<sup>[18]</sup> Valacyclovir 500 mg TID peroral and Moxifloxacin one drops QID was reported as a therapy for herpetic keratoconjunctivitis related to COVID-19 patient, with pseudodendritic infiltrate or expansion of infiltrate with preauricular lymphadenopathy in epidemic keratoconjunctivitis. Topical antibiotic and corticosteroid combination therapy for this case was also reported. Ofloxacin, tobramycin, gancyclovir teardrops, and artificial teardrops also were recorded as treatment of choice both in single conjunctivitis and conjunctivitis with dry eye.<sup>[19]</sup>

## DISCUSSION

We have found several studies regarding ocular manifestation in COVID-19 patients, although it's quite limited because of the rarity of ocular symptoms in the patient. Further reports and data were needed to understand more about ocular manifestation and the therapy in COVID-19 patients.



### **Ocular clinical manifestation in COVID-19 patient**

Several non-specific ocular manifestations in COVID-19 patients were already reported. The percentages varied, range from 0,8 – 50%. The most general ocular manifestation was hyperemic conjunctiva and the finding of the eye mucus. Other reported manifestations were viral conjunctivitis with the specific follicle, dry eye, hemorrhagic conjunctivitis with pseudomembrane, herpetic keratoconjunctivitis, epidemic keratoconjunctivitis, vision decrease, even floaters after treatment. The SARS-CoV2 transmissions suspected mainly originate from the conjunctiva. Firstly, the virus will attach its genetic material to the ACE2 receptor in the conjunctiva and cornea epithelial.<sup>[9,10]</sup> Secondly, the nasolacrimal duct acted as a connection to the upper respiratory tract so the infection to the host begins.<sup>[11]</sup> However, the researchers and specialists still have doubts about this theory. Several arguments were: the small amount of ACE2 receptor in the conjunctiva is smaller than in lungs and kidney.<sup>[11-14]</sup> The attachment between this receptor on conjunctiva epithelial with viral protein is weaker compared with the receptor in the lungs <sup>[12,15]</sup> lactoferrin and IgA secretory component in the tears may eliminate the virus, tears flushing also participate in leading the virus inside nasal cavity through the nasolacrimal duct.<sup>[11,12,16]</sup> Lange *et al.* reported that ACE2 was not transcribed in conjunctiva tissue, which means the replication of SARS-CoV-2 could happen in small occurrences.<sup>[17]</sup>

Although there was a lot of doubtful hypotheses regarding virus transmission through the conjunctiva, the writer agrees with WHO recommendation for medical staff to protect their eyes with goggle or face shield, prevent touching the eyes, nose, and mouth mucous membrane when on the work.<sup>[21]</sup>

### **Correlation between ocular and systemic manifestation in COVID-19 patient**

Various studies reported that ocular manifestation may present with or without systemic manifestation. It may appear without systemic symptom, as a prodromal symptom, simultaneously occur with a systemic symptom, when the moderate-severe acute respiratory syndrome took place, or even as a residual symptom after treatment was finished, known as floaters.<sup>[14,21]</sup> The viral invasion mechanism and the viral load were presumed related to affect those conditions. An experimental study with *rhesus macaque* monkey highlighted the importance of ocular conjunctiva's transmission route in SARS-CoV-2 infection. In this study, five rhesus monkeys were inoculated by  $1 \times 10^6$  TCID<sub>50</sub> from SARS-CoV-2 through several pathways, through conjunctiva (CJ group), intratracheal (IT group), and intragastric (IG group). The results showed highly viral load and the lungs were the most affected organ in IT groups. Mild interstitial pneumonia and viral load were observed in the CJ group through a conjunctival swab test one day after inoculation. Only in the IT group, the viral load was found in the rectum 1-7 days after inoculation, and the decreasing weight was also observed. However, in the IG group, the viral load was non-existent. In the CJ group, nasolacrimal viral load was higher and lungs lesion was more localized and milder compared to the IT group.<sup>[19]</sup> These findings may be proof of infection through ocular transmission in COVID-19 patients. Thus, medical workers should protect their eyes when interacting with the patient.

### **Relevancy between RT-PCR conjunctiva swab and ocular manifestation in COVID-19 patient**

In the COVID-19 patient confirmed through nasopharyngeal swab, there was still no clear percentage that the result of conjunctival swab will also the same. It may vary to 0-100% in all cases. The COVID-19 patient with complaints related to the eyes may show positive or negative results from the conjunctival swab test.<sup>[14,18,19]</sup> A cross-sectional study conducted by Güemes-villahoz, *et al.*, reported that 1 from 18 COVID-19 patients with systemic manifestation without conjunctivitis may show positive results from the conjunctival swab test (5,6%).<sup>[24]</sup> Kumar K, *et al.*, stated in their case series that asymptomatic COVID-19 patient (without systemic and ocular symptom) shows a positive result from conjunctival swab test.<sup>[15]</sup> To explain the whereabouts of this virus in conjunctiva secretion and tears, several suitable hypotheses were the direct virus inoculation through droplet transmission, virus migration through the nasolacrimal duct, or hematogenic infection on the lacrimal gland.<sup>[8]</sup> The sensitivity test of RT-PCR method for SARS-CoV-2 has not been reported optimally yet. The result was approximately 50-60% so there is a possibility of false-positive and false-negative in this test. Nevertheless, until this day, nasopharyngeal swabs still hold the gold standard as a confirmation of COVID-19 patients. The reason for the small virus amount in conjunctival swab may relate to the short period of early infection, and the sample collection can not be

performed at the correct time, or there is no SARS-CoV-2 in the patient's eyes respectively. The window period of virus transmission may be missed.<sup>[11]</sup> The RT-PCR method used in these studies may be not sensitive enough to detect SARS-CoV with a small amount of viral load. Xia *et al.* stated that the small number of collected tears and conjunctival secretion were insufficient to detect the virus through RT-PCR, which leads to negative results. The damage of genetic component and sample contamination also may be involved in a positive or false-negative result.<sup>[14]</sup> In this reviewed literature, the correct sample collection period also has not yet been mentioned. Serial examination or sample follow up were also not being performed, usually only one-time examination per sample. Only reports from Xia J, *et al.*, and Navel V, *et al.*, who performed twice RT-PCR method in conjunctival swab with time interlude three and two days respectively, and both results were positive.<sup>[14,18]</sup> Sample collection from trained personnel, such as ophthalmologists/optometrist is important. The conjunctival swab is expected to be performed as early as possible if the ocular symptom was found. Loon *et al.*, recommended the use of Shirmer filter paper, or capillary micropipette on inferior fornix palpebra to get good sample quantity and quality, as the other studies recommend so.<sup>[14]</sup>

### **Therapy of conjunctivitis given to COVID-19 patient**

Not all studies above explained about therapy given to the COVID-19 patient with eyes' symptoms. Generally, topical antiviral and antibiotic, corticosteroid, and artificial teardrops were given in COVID-19 patients.<sup>[18,19,21]</sup> There was one case that was given additional peroral antiviral.<sup>[19]</sup> These therapies were given in consideration to manifestation and level of severity. The topical antiviral given in the reviewed article was gancyclovir teardrops, while the topical antibiotics were moxifloxacin, azithromycin, ofloxacin, and tobramycin teardrops.<sup>[16,21]</sup> Meanwhile, the topical corticosteroid used was low dose dexamethasone.<sup>[18]</sup> Valacyclovir was also given per-orally.<sup>[19]</sup> There is still no further study about the most suitable therapy for conjunctivitis in COVID-19 patients. Although acyclovir, valacyclovir, cidofovir, and famciclovir were reported to be used safely in viral conjunctivitis, the effectivity in the COVID-19 patient is still unknown.<sup>[14]</sup> Povidone-iodine 1% teardrop also has been reported to be useful to treat adenoviral conjunctivitis, and a shows anti-SARS-CoV activity in vitro, although this treatment has not yet been given to the COVID-19 patient.<sup>[15]</sup>

### **CONCLUSION**

Scientific study related to ocular manifestation in COVID-19 patients is still limited, although it is understandable, for the rarity of cases and this pandemic situation. Ocular manifestation in COVID-19 patient may seem similar to viral conjunctivitis in general, or other manifestation. Ocular manifestation may be related to systemic manifestation as a prodromal symptom, simultaneously appear with the systemic symptom, occur when the moderate-severe acute respiratory syndrome begin, or as residual floaters after treatment ended. The asymptomatic eyes do not indicate the virus is absent, and vice versa. Several factors such as the small concentration of viral load, time choice of sample collection, and ineffective detection method. Further research and study are needed to understand the potential of conjunctiva transmission and suitable therapy regarding conjunctivitis in COVID-19 patients. Nonetheless, we emphasize the importance of eye protection for medical workers, despite the presence or absence of ocular manifestation.

### **ACKNOWLEDGEMENT**

The authors are grateful to the authorities of Department of Ophthalmology, Faculty Medicine, Jember University, Jember, East Java, Indonesia for able guidance and knowledge imparted to us.

### **CONFLICT OF INTEREST**

The authors are declare no conflict of interest.

### **REFERENCES**

1. WHO. Q&A on coronaviruses (Covid-19). Available from: <https://www.who.int/emergencies/disease/novel-coronavirus-2019/question-and-answers-hub/qadetail/q-a-coronaviruses> (Accessed 4 July 2020)

2. WHO. World Health Organization statement regarding cluster of pneumonia cases in Wuhan. China. 9 January 2020. Available from: <https://www.who.int/china/news/detail/09-01-2020-who-statement-regardingcluster-of-pneumonia-cases-in-wuhan-china> (Accessed 4 July 2020)
3. Li JO, Ting DSW, Chen Y, Lam DSC. Novel coronavirus disease 2019 (Covid-19). The importance of recognising possible early ocular manifestation and using protective eyewear. *BrJOphthalmol.* 2020; 104(3): 297-8. Available from: <http://dx.doi.org/10.1476/bjophthalmol-2020-325194>
4. WHO. World Health Organization Director General's opening remarks at the media briefing on Covid-19 11 March 2020; Available from: <https://www.who.int/dg/speeches/detail/who-director-general-s-opening-remarks-at-the-media-briefing-on-covid-1911-march-2020> (Accessed 4 July 2020)
5. WHO. World Health Organization Emergency Committee. Statement on the second meeting of the international health regulation (2005) emergency committee regarding the outbreak of novel coronavirus (COVID-19). Available from: [https://www.who.int/news-room/detail/30-01-2020-statemnet-on-the-second-meeting-of-the-international-health-regulation-\(2005\)-emergency-committee-regarding-the-outbreak-of-novelcoronavirus-\(2019-ncov\)](https://www.who.int/news-room/detail/30-01-2020-statemnet-on-the-second-meeting-of-the-international-health-regulation-(2005)-emergency-committee-regarding-the-outbreak-of-novelcoronavirus-(2019-ncov)) (Accessed 4 July 2020)
6. WHO. World Health Organization Coronavirus disease (Covid-19) Dashboard. Available from: [https://covid19.who.int/?gclid=Cj0KCQjw0YD4BRD2ARIsAHwmKVmPoujgOKnenDHRtSyG8zUzrgr138UWL0V8niZEmEUdD\\_cwQj1fwaApPaEALw\\_wcB](https://covid19.who.int/?gclid=Cj0KCQjw0YD4BRD2ARIsAHwmKVmPoujgOKnenDHRtSyG8zUzrgr138UWL0V8niZEmEUdD_cwQj1fwaApPaEALw_wcB) (Accessed 12 July 2020).
7. Huang C, Ren L, Wang Y, Zhao J, Li X, Hu Y et al. Clinical features of patients infected with 2019 novel coronavirus in Wuhan, China. *Lancet.* 2020. 396(10223):497-506. Available from:[https://doi.org/10.1016/S0140-6736\(20\)30183-5](https://doi.org/10.1016/S0140-6736(20)30183-5)
8. SeahI, and Agrawal R. Can the coronavirus disease 2019 (Covid-19) affect the eyes? A review of coronaviruses and ocular implications in human and animals. *OculimmunolInflamm.* 2020; 28(3): 391-5. Available from: <https://doi.org/10.1080/09273948.2020.1738501>
9. Li JO, Chen Y, Lam DSC, Ting DSW. Novel coronavirus disease 2019 (Covid-19): The impotance of recognicing possible early ocular manifestaion and using protective eye wear. *BrJOphthalmol.* 2020; 104(3):297-8. Available from: <https://dx.doi.org/10.1136/bjophthalmol-2020-315994>
10. Zhu N, Wang W, Zhang D et al. A novel coronavirus from patiens with pneumonia in china 2019; *Nengl J Med.* 2020. 328: 72733. DOI: 101056/NEJMoa2001017.
11. CDC, WHO Important coronavirusupdates for ophthalmologists. Available from: <http://www.ao.org/headline/alert-important-coronavirus-context> (Accesed 4 July 2020)
12. Lai CC, Shih TP, Ko WC, Tang HJ, Hsueh PR. Severe Acute Respiratory Syndrome Coronavirus 2 (SARS-CoV-2) and Coronavirus disease (COVID-19): The epidemic and the challenges. *Int J Antimicrob Agents.* 2020; 55(3): 105924. Doi: 10.1016/j.ijantimicag.2020.105924
13. Van der Hoek L, Pyrc K, Vermulen-Oost W, Berkhout RJ, Wolthers KC, et al. Identification of a new human coronavirus. *Nat Med.* 2004; 10(4): 368-78. DOI: 10.1038/nm1024
14. Xia J, Tong J, Liu M, Shen Y, Guo D. Evaluation of Coronavirus in tears and Conjuntival secretions of patients with SARS-CoV-2 Infection. *J Med Virol.* 2020; 92 (6): 589-94. DOI: 10.1002/jmv.25725
15. Wu P, Duan F, Luo C, Liu Q, Qu X, Liang L, et al. Charateristic of ocular findings of patients with Coronavirus Disease 2019 (COVID-19) in Hubei Province, China. *JAMA Ophthalmol.* 2020; 138(5): 5758. DOI: 10.1001/jamaophthalmol.2020.1291
16. WHO. Report of the WHO-China joint mission on Coronavirus Disease 2019 vol 2019. Available from: <https://www.who.int/docs/default-source/coronaviruse/who-china-joint-mission-on-covid-19-final-report.pdf> (Accessed 4 July 2020)
17. Moher D, Shamseer L, Clarke M, Ghersi D, Liberati A, Petticrew M, Shekelle P, Stewart LA,

PRISMA-P Group. Preferred Reporting Items for Systematic Review and Meta-Analysis Protocols (PRISMA-P) 2015 Statements, Syst Rev. 2015 Jan 1; 4:1

18. Navel V, Chiambaretta F, Dutheil F. Haemorrhagic conjunctivitis with pseudomembranous related to SARS-CoV-2. American J Ophthalmol. 2020; 19: 100735. Doi.org/10.1016/j.ajoc.2020.100735
19. Cheema M, Aghazadeh H, Nazarali S, Ting A, Hodges J, McFarlane A, *et al.* Keratoconjunctivitis as the initial medical presentations of the Novel Coronavirus Disease 2019 (COVID-19). Canadian Ophthalmol Society. 2020; S0008-41 (20) 30305-7 .doi.org/101016/j.cjo.2020.03.003
20. WHO. Timeline of WHO's response to Covid-19. Available from: <https://www.who.int/news-room/detail/29-06-2020-covidtimeline> (Accessed: 5 July 2020)
21. Scalinci SZ, Battagliola ET. Case report conjunctivitis can be the only presenting sign and symptom of COVID-19. ID Cases. 2020; 1-2. Doi.org/10.1016/j.idcr.2020.e00774
22. Hong N, Yu W, Xia J, Shen Y, Yap M, Han W. Evaluation of ocular symptoms and tropism of SARS-Cov-2 n patients confirmed with COVID-19. ActaOphthalmol. 2020; 10.1111/aos.14445. doi: 10.1111/aos.14445.
23. Zhang X, Chen X, Chen L, Deng C, Zou X, Liu W, *et al.* The infection evidence of SARS-COV-2 in ocular surface: A single-center cross-sectional study .MedRiv preprint. 2020. Doi/org/10.1101/20202.02.26.20027938
24. Guemes-Villaoz N, Burgos-Blasco B, Vilela AA, Arriola-Villabos P, Luna CMR, Sardina RC, *et al.* Detecting SARS-CoV-2 RNA in conjunctival secretions: is it valuable diagnostic methods of COVID-19? JMV. 2020;1-6. DOI: 10.1002/jmv.26219
25. Kumar K. Prakash, AA, Gangasagara SB, Rathod S, Ravi K, Rangajah A *et al.* Presence of Viral RNA of SARS-CoV-2 in conjunctival swab specimen of COVID-19 patient. Indian Journal Ophthalmol. 2020; 68(6): 1015-17. doi: 10.4103/ijo.org.IJO\_1287\_20.