

# Role of Diffusion-Weighted MR imaging in identifying residual malignant lesions of tongue and buccal mucosa in post radiotherapy status

<sup>1</sup>Dr.Panchami.P, <sup>2</sup>Dr. Aditi Nadamani, <sup>3</sup>Dr.Suresh A, <sup>4</sup>Dr.Devamani VKHCR

<sup>1</sup>Postgraduate, Department of Radiodiagnosis & Imaging, Vydehi Institute of Medical Science, Bangalore

<sup>2</sup>Assistant Professor, Department of Radiodiagnosis & Imaging, Vydehi Institute of Medical Science, Bangalore

<sup>3</sup>HOD & Professor, Department of Radiodiagnosis & Imaging, Vydehi Institute of Medical Science, Bangalore

<sup>4</sup>Postgraduate, Department of Radiodiagnosis & Imaging, Vydehi Institute of Medical Science, Bangalore

<sup>1</sup>panchu.1993@gmail.com

## ABSTRACT :

### Objectives:

- To assess the role of diffusion-weighted MR imaging in differentiating residual malignant lesions of tongue and buccal mucosa from post radiotherapy inflammatory changes in biopsy proven cases of carcinoma tongue and buccal mucosa.
- To assess the predictive validity of ADC values in differentiating residual malignant lesions of tongue and buccal mucosa from post radiotherapy inflammatory changes in biopsy proven cases of carcinoma tongue and buccal mucosa.
- To assess the diffusion weighed imaging (DWI) characteristics of malignant lesions of tongue and buccal mucosa.

### Methods :

- Study design: It is a retrospective observational study
- Study setting: Department of radiology of Vydehi Institute of Medical Sciences and Research Centre .
- Study population: Known cases of tongue and buccal malignancies, post radiotherapy and chemotherapy referred to the department of radiology to access for treatment response.
- Sample size: A total of 18 eligible subjects were included.
- The eligible patients underwent conventional MRI and DWI with b-values of 0 and 800 s mm<sup>-2</sup> . The apparent diffusion coefficient (ADC) maps were reconstructed and the ADC values of the lesions were calculated and compared between post radiotherapy inflammatory changes and residual lesions of the tongue and buccal mucosa.

### Results :

- The results of this study demonstrated that the mean ADC values of residual malignant lesions were significantly lower ( $p < 0.01$ ) than those of post radiotherapy inflammatory changes .
- The mean ADC values of the residual malignant tumours were  $(0.73 \pm 0.06) \times 10^{-3}$  and post radiotherapy inflammatory changes were  $1.74 \pm 0.06 \times 10^{-3}$

- Receiver operating characteristic analysis showed that when an ADC value  $<1.41 \times 10^{-3} \text{ mm}^2 \text{ s}^{-1}$  was used for predicting malignancy, the highest accuracy of 95 %, sensitivity of 92.6% and specificity of 97.3% were obtained.

**Conclusion:**

ADC is a promising non-invasive imaging approach in characterising tongue and buccal lesions in post radiotherapy patients of carcinoma tongue and buccal mucosa, as it can help differentiate residual malignant lesions from post radiotherapy inflammatory changes.

**Index Terms— Diffusion weighted MRI (DWI) , ADC , STIR****I. INTRODUCTION**

Diffusion-weighted imaging (DWI) is a form of MR imaging based upon measuring the random Brownian motion of water molecules within a voxel of tissue. Diffusion-weighted MR imaging can provide physiological information complementing morphological findings from conventional MRI<sup>[1]</sup>.

The extent of molecular diffusion can be quantified in terms of the apparent diffusion coefficient (ADC). The ADC values reflect the microstructure or pathophysiological state of a tissue and are inversely correlated with tissue cellularity. Decrease in the ADC is expected with increased intracellular tissue caused by either cell swelling or increased cellular density<sup>[1]</sup>.

DWI can be performed without the need for the administration of exogenous contrast medium, so it may be of use when contrast administration is contraindicated. It yields quantitative and qualitative information that reflects changes at the cellular level and indicates the integrity of cell membranes<sup>[2]</sup>.

Some studies reported the application of DWI with calculation of ADC in the differentiation between benign and malignant head and neck masses. They have found significant differences in apparent diffusion coefficient (ADC) values of benign and malignant lesions , with malignant lesions tending to have lower ADC values<sup>[2]</sup> . However , knowledge gap remains with regard to ADC values in residual lesions post treatment and its use in differentiating residual lesions from post radiation changes.

In this study we examined the ADC values and DWI characteristics using 1.5T field strength of residual malignant lesions of tongue and buccal mucosa . We compared the mean ADC values of residual malignant lesions and post radiation inflammatory changes , offering a useful threshold value for predicting recurrence.

**II. MATERIALS AND METHODS :**

Study design: It is a retrospective observational study

Study setting: Department of radiology , Vydehi Institute of Medical Sciences and Research centre , Bangalore.

Study population: Biopsy proven cases of tongue and buccal mucosa , post radiation referred to the department of Radiology for MRI to look for residual lesion.

Sample size: A total of 18 eligible patients were included.

Inclusion criteria: Both male and female patients referred to radiology department with tongue and buccal carcinoma , post radiotherapy .

Exclusion criteria :

Patients with tongue and buccal lesions which are not biopsy proven.

Biopsy proven cases of tongue and buccal carcinoma that haven't undergone radiotherapy.

Patients having non MRI compatible implants .

Method :

Imaging of head and neck performed using 1.5T Siemens healthcare scanner.

Diffusion sequences performed in addition to routine head and neck pulse sequences

DWI parameters defined at b values of 0 and 800 s/mm<sup>2</sup>

DWI sequence performed in axial plane using a standard head and neck coil.

T1,T2 and STIR sequence performed in axial and coronal planes using a standard head and neck coil.

All ROI evaluation was at the PACS workstation . ROI spared the peripheral 2mm of lesion and excluded cystic and necrotic portions of lesion as described by Srinivasan et al. Mean ADC values were calculated .

Mean ADC values of recurrent malignant lesions and post radiation inflammatory changes were compared using an unpaired t test with unequal variance . p value of less than 0.05 was considered statistically significant .

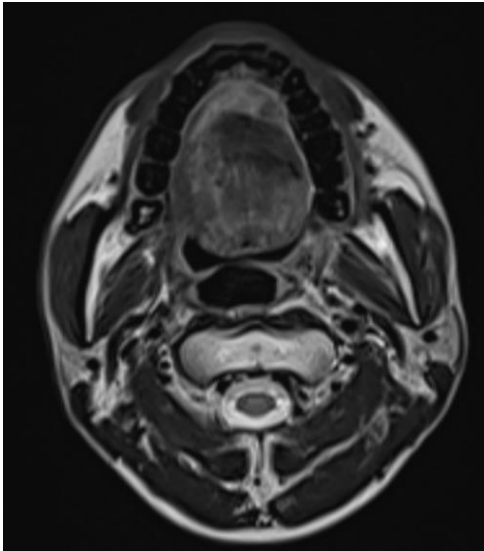
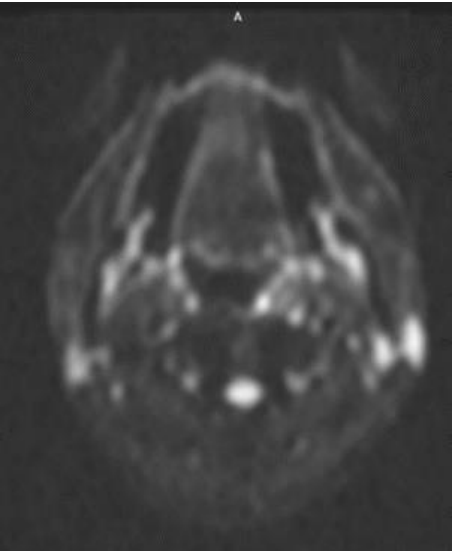
Additional ROC was performed to determine sensitivity, specificity , positive predictive value and negative predictive value .

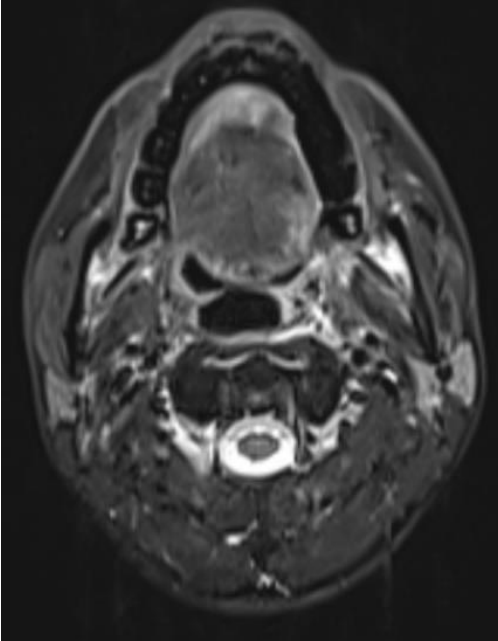
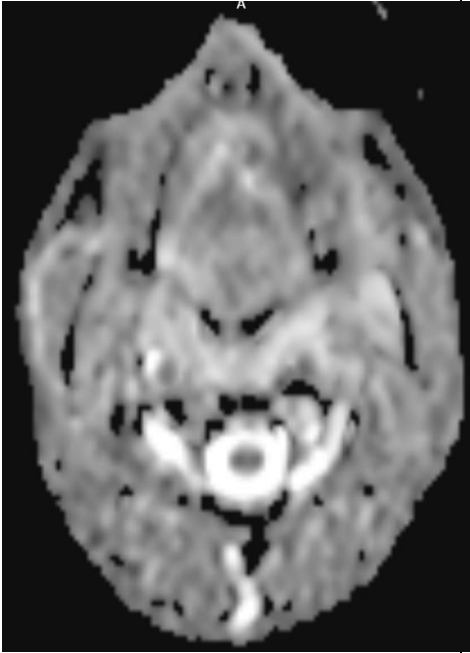
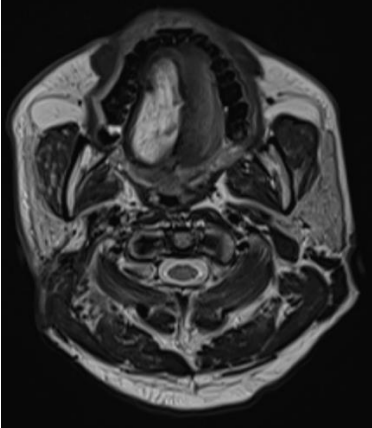
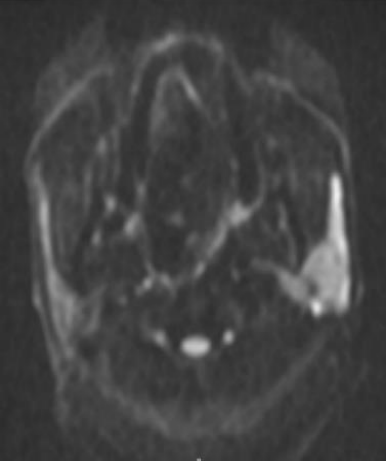
**III. OBSERVATIONS AND RESULTS:**

In our study 18 eligible patients were included , 6 patients showed only post radiation inflammatory changes with no recurrence and 12 patients showed recurrent malignant lesions.

Post inflammatory changes appeared hypointense( n=3 ) to isointense(n=3) on T1W and hyperintense on T2W and STIR , hyperintense on DWI and showed no signal drop on ADC. High ADC values were obtained from ADC map.

**TABLE 1: ILLUSTRATIVE CASES FROM THE STUDY:**

HISTORY	T2W & STIR	DWI	HISTOPATHOLOG Y
<p>CASE1 :</p> <p>K/c/o Carcinoma of tongue . Post CTRT</p>	 <p>Fig: 1: Ill-defined area of signal alteration appearing hyperintense on T2W involving the tip and right</p>	 <p>Fig:3 : DWI axial image shows restriction in the tip of the tongue with low mean ADC value of 0.8</p>	<p>Residual lesion</p>

	<p>lateral aspect of the anterior 2/3rd of the tongue.</p>  <p>Fig: 2: Ill-defined area of signal alteration appearing hyperintense on STIR involving the tip of the tongue.</p>	<p><math>\times 10^{-3} \text{ mm}^2 \text{ s}</math></p>  <p>Fig:4 : ADC map shows a focal signal drop in the tip of tongue with low mean ADC value of <math>0.8 \times 10^{-3} \text{ mm}^2 \text{ s}</math></p>	
<p>CASE2 : K/c/o Carcinoma tongue, s/p MRND &amp; RT</p>	 <p>Fig: 5: T2W axial image showing hyperintense area in the right lateral aspect of tongue.</p>	 <p>Fig: 7: DWI showing no restriction in the right lateral aspect of tongue . Left parotid gland shows high signal on</p>	<p>No recurrence in the right lateral aspect of tongue</p>

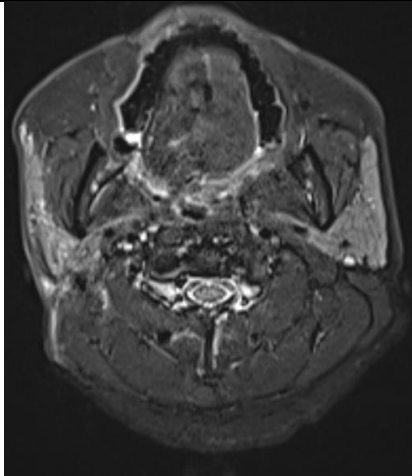


Fig: 6: STIR axial image showing focal hyperintensities in the right lateral aspect of tongue .

DWI and high ADC value of  $1.6 \times 10^{-3} \text{ mm}^2 \text{ s}$ - Suggestive of post radiation parotitis.

- **TABLE 2: COMPARISON OF T2 & STIR BETWEEN RECURRENT AND NON RECURRENT LESIONS (N=18)**

T2W & STIR	RECURRENT LESION(n=12)	INFLAMMATORY CHANGES(n=6)
Hyperintense	7(58%)	6(100%)
Isointense	5(42%)	-

- **TABLE 4: COMPARISON OF MEAN OF MEAN ADC VALUE BETWEEN RECURRENT AND NON RECURRENT LESIONS (N=18)**

PARAMETER	RECURRENT LESION(n=12)	INFLAMMATORY CHANGES(n=6)	P value
Mean ADC value	$0.73 \pm 0.06$	$1.74 \pm 0.06$	<0.01

**TABLE 5: THE ADC VALUES FOR BENIGN LESIONS**

Statistic	Value	95% CI
Sensitivity	100.00%	54.07% to 100.00%
Specificity	33.33%	13.34% to 59.01%
Positive Likelihood Ratio	1.50	1.08 to 2.08
Negative Likelihood Ratio	0.00	
Disease prevalence (*)	95.00%	
Positive Predictive Value (*)	96.61%	95.36% to 97.53%
Negative Predictive Value (*)	100.00%	
Accuracy (*)	96.67%	80.15% to 99.96%

Sensitivity is 100%. Specificity ratio is 33.33%. Positive likelihood ratio is 1.50 for ADC, Negative likelihood ratio is 0. 95% ,Positive predictive value here is 96.61%, Negative predictive value is also 100%. The accuracy for ADC is 96.67%.

**TABLE 6: THE ADC VALUES FOR BENIGN LESIONS:**

Statistic	Value	95% CI
Sensitivity	100.00%	73.54% to 100.00%
Specificity	66.67%	40.99% to 86.66%
Positive Likelihood Ratio	3.00	1.56 to 5.77
Negative Likelihood Ratio	0.00	
Disease prevalence (*)	95.00%	
Positive Predictive Value (*)	98.28%	96.74% to 99.10%
Negative Predictive Value (*)	100.00%	
Accuracy (*)	98.33%	85.46% to 100.00%

The ADC values for malignant lesions : Sensitivity is 100%. Specificity ratio is 66.67%. Positive likelihood ratio is 3.00 for ADC. Negative likelihood ratio is 0% ,Positive predictive value here is 98.28%. Negative predictive value is also 100%. The accuracy for ADC is 98.33%.

#### IV. DISCUSSION

- In the present study, the differentiation of malignant lesions from post radiation inflammatory changes was done using DWI-MRI Imaging. DWI technique is based on the "Brownian" motion of the water molecules in any sample. This movement is delayed in the biological tissues due to the presence of cell walls and other intracellular organelles. In benign tissues, the motion of the molecule is somewhat less impeded because of relatively less cellularity and the presence of a smaller nucleus. In contrast, malignant cells have densely packed nucleus that decreases the cytoplasmic space inside a cell. Therefore, this offers less free movement of the water molecules in malignant tissue compared to the benign ones<sup>[3]</sup>.

- In this present study among the total 18 cases, 12 cases were malignant cases whereas 6 cases were found to be benign lesions. The present study also evaluated the efficacy of T1-weighted ,T2-weighted and STIR MRI imaging. Along with the DWI MRI scanning the convention MRI scanning using T1-weighted , T2-weighted and STIR imaging was also done. ADC values were calculated and then the result of this study was correlated with the histopathological findings. This also demonstrates that the ADC value of the post inflammatory changes were higher compared to the malignant lesions, though both showed high signal on DWI.

- In a previous study by Srinivasan et al it was demonstrated that the ADC value between the malignant and benign lesions varies significantly among the patients with the head and neck cancers<sup>[4]</sup>.

- In another study by Cheng et al it was reported that the mean ADC value of the malignant tumors are significantly lower compared to the benign solid lesions. They have concluded that diffusion weighted imaging (DWI) is an important tool that can differentiate between the malignant and benign lesions significantly. In this study a ADC cut off value of

$<1.31 \times 10^{-3} \text{ mm}^2 \text{ s}^{-1}$  was shown to be significantly useful for differentiating between the benign and malignant lesions<sup>[5]</sup>.

- The matrix composition of tissue also can affect the diffusion of the water molecules and thus will affect the result of the DWI<sup>[6]</sup>. For example, fibrous tissues with extracellular collagen are known to restrict diffusion. In addition, b value also plays a significant role in DWI because of its diffusion-sensitizing effect from the gradients<sup>[7]</sup>.

- The mean ADC value reported in the present study is quite similar to the reported ADC value by the Razek et al group. This group has also reported a higher ADC value for benign lesions. The authors argued that the presence of higher concentration of hemorrhage, necrotic tissue and fibrous tissue in benign lesions might be responsible for this increased ADC value. On the other hand presence of hyperplastic nuclei is responsible for the lower ADC value of the malignant lesions<sup>[6]</sup>.

- In another study by Ai et al it was reported that malignant tumors have a lower ADC value compared to the benign lesions. This study showed similar findings to present study. The ADC threshold used in this study was  $<1.43 \times 10^{-3} \text{ mm}^2 \text{ s}^{-1}$ . However, Ai et al didn't include inflammatory lesions<sup>[2]</sup>.

- In a study by Delorme and Knopp it was reported that the ADC value of the malignant tissue could be dependent on many factors such as blood perfusion and extracellular space. Usually the malignant lesions do not have a complete basal membrane of blood vessel which in turn affects the ADC value of the lesions. In case of thyroid malignancy, the blood perfusion in the tissue increases which increases the value apparent diffusion coefficient however, because of less extracellular space the movement of the molecules gets restricted<sup>[9]</sup>.

- Further statistical analysis showed that ADC values can identify the benign lesions with a 100% sensitivity, 33.33% specificity, and 96.67% accuracy. On the other hand for malignant lesions the sensitivity is 100%, specificity is 66.67%, and accuracy is 98.33%.

- The main limitation of this study is that it was conducted on a small sample size and a larger cohort study is warranted to further evaluate the findings. In addition, it is always recommended to have a multiparametric MRI modality to be used in these patients as we have observed that ADC values of some of the benign and the malignant lesions overlapped.

- In conclusion, the present study showed that DWI-MRI can effectively differentiate between the malignant and benign tongue and buccal lesions. The histopathological finding also correlated well with the diffusion-weighted imaging result.

## V. REFERENCES:

1. Bammer R. Basic principles of diffusion-weighted imaging. *Eur J Radiol.* 2003;45(3):169-184.
2. Li S, Cheng J, Zhang Y, Zhang Z. Differentiation of benign and malignant lesions of the tongue by using diffusion-weighted MRI at 3.0 T. *Dentomaxillofac Radiol.* 2015;44(7):20140325.
3. Wang J, Takashima S, Takayama F, Kawakami S, Saito A, Matsushita T, et al. Head and Neck Lesions: Characterization with Diffusion-weighted Echo-planar MR Imaging. *Radiology.* 2001 Sep 1;220(3):621-30.
4. Srinivasan A, Dvorak R, Perni K, Rohrer S, Mukherji SK. Differentiation of Benign and Malignant Pathology in the Head and Neck Using 3T Apparent Diffusion Coefficient Values: Early Experience. *Am J Neuroradiol.* 2008 Jan;29(1):40-4.
5. Abdel Razek AAK, Soliman NY, Elkhamary S, Alsharaway MK, Tawfik A. Role of diffusion-weighted MR imaging in cervical lymphadenopathy. *Eur Radiol.* 2006 Jul;16(7):1468-77.

6. Ai S, Zhu W, Liu Y, Wang P, Yu Q, Dai K. Combined DCE- and DW-MRI in diagnosis of benign and malignant tumors of the tongue. *Front Biosci Landmark Ed.* 2013 Jun 1;18(3):1098–111.
7. Qayyum A. Diffusion-weighted imaging in the abdomen and pelvis: concepts and applications. *Radiogr Rev Publ Radiol Soc N Am Inc.* 2009 Oct;29(6):1797–810.
8. Thoeny HC, De Keyzer F, King AD. Diffusion-weighted MR Imaging in the Head and Neck. *Radiology.* 2012 Apr 1;263(1):19–32.
9. Delorme S, Knopp M. Non-invasive vascular imaging: assessing tumour vascularity. *Eur Radiol.* 1998;8(4):517–27.