

# Giant Benign Retroperitoneal Non-Pancreatic Pseudocyst in a Female: A Case Report & A Diagnostic Challenge

Vani Dutta Chawla, Anurag Saraswat, Fahad Tauheed, Purshotam Dass Gupta,  
Vikram Singh Chauhan

Department of General Surgery, SMS&R, Sharda Hospital, Greater Noida, Uttar Pradesh,  
India

## ABSTRACT

*Background Retroperitoneal cysts (RPCs) are uncommon with an estimated incidence of 1/5750 to 1/250,000. In this entity, non-pancreatic pseudocyst are the rarest with only handful of cases reported in literature, out of which all were found in males. Most of the time they are discovered incidentally and diagnosis depends in part histologically on absence of an epithelial lining to the cyst wall, and the patient's history represents the cornerstone for diagnosis prediction.*

*Case presentation A 27 year old, female patient presented to the Gynaecology out patient department with complaints of amenorrhea for 2 months & lower abdominal discomfort. On investigation, there was an incidental finding of a large multi-cystic lesion arising from the pelvis on transvaginal ultrasound scan. The patient was then referred to the General Surgery department for further management. Correlation of the clinical scenario, imaging and post-operative histopathological examination of the specimen, revealed Retroperitoneal Non-pancreatic Pseudocyst.*

*Conclusion RPC's are very rare, and probably remain quiescent, until attain considerable size. Usually, symptoms are non-specific and on examination there may be a palpable, freely mobile abdominal mass. Sometimes, subjected to one of its classical complications such as infection, rupture or haemorrhage enforcing the patient to seek urgent medical advice. In view of potential development of symptoms and complications, the treatment protocol lines with complete excision of the cyst in order to prevent any recurrence.*

*Keywords: retroperitoneal mass, pseudocyst, non-pancreatic pseudocyst, female patient.*

## BACKGROUND

RPC's are cysts originating within the fatty areolar tissue of the retroperitoneum without any communication to the adjacent structures. They are rare, with an incidence of 1 in 5750 to 1 in 250 000.<sup>1</sup> They are usually slow growing within the connective tissue and do not give rise to symptoms until they attain large size and compress over the adjacent structures developing compression symptoms. The pathogenesis of these cysts remains unclear.

The differential diagnosis of cystic lesions in the retroperitoneum is extensive and includes non-neoplastic cysts—such as pseudocyst, enteric duplication cyst, enteric cyst, mesothelial cyst, lymphocele and parasitic cyst—and neoplastic cysts—such as cystic lymphangioma, mucinous cystadenoma, epidermoid cyst, cystic teratoma, cystic mesothelioma and cystic degeneration of solid tumours.<sup>2</sup>

A retroperitoneal pseudocyst, on the contrary, is a fluid-filled cavity that is devoid of an epithelium lining and is lined by fibrous tissue. Here we describe a rare case of RPC which is non-pancreatic in origin, managed by open surgical approach.

### CASE PRESENTATION

A 24 year old female patient came to Department of Obstetrics and Gynaecology with complaints of amenorrhea from 2 months & lower abdomen pain which was insidious in onset, episodic in nature, mild in intensity, dull aching type of pain. No other significant positive history was obtained. Patient had no comorbidities and no previous surgical history. On abdominal examination, there was no palpable lump. Fullness in left lateral wall of vagina was observed on per vaginal examination. Digital rectal examination revealed no abnormality.

On further evaluation, there was an incidental finding of a large multi-septate cystic lesion with internal echoes arising from the pelvis on transvaginal ultrasound scan. Contrast enhanced - Magnetic Resonance imaging (MRI) of the whole abdomen & pelvis was advised to the patient and referred to Department of General Surgery.

With speculation of suspected mass abdomen, patient was admitted for further evaluation after following necessary COVID protocols.

Past medical history revealed that patient took some over the counter Medical Termination of Pregnancy (MTP) pill outside hospital in view of Urinary pregnancy Test (UPT) positive status & was admitted there subsequently for passing clots, ten days before the abdominal discomfort started. Patient was advised to get all routine blood investigations and tumour marker CA-125 was sent.

Ultrasound abdomen showed that there is evidence of abdomino-pelvic multiseptated cystic lesion seemed to be arising from the left adnexa, measuring 18.67 x 8.50 cm, superiorly seen abutting the inferior pole of left kidney with low level of internal echoes within.

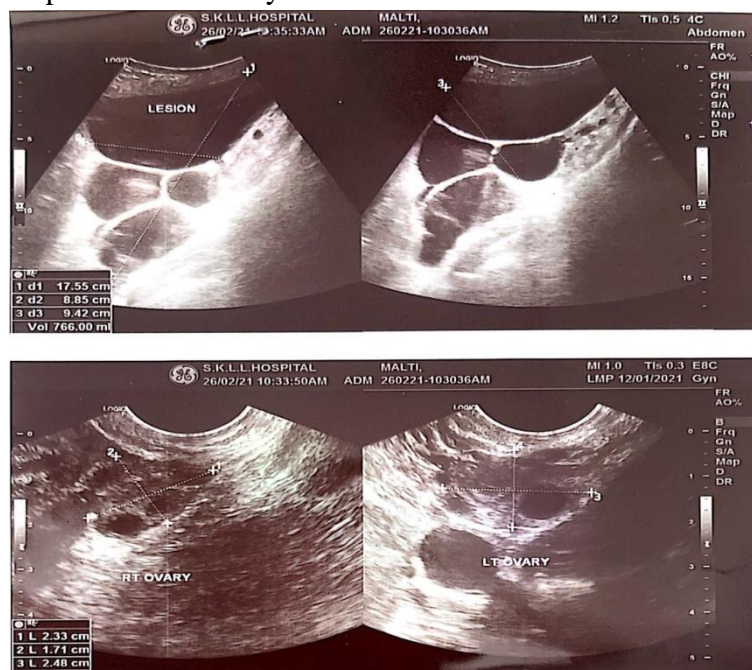


Figure 1:Ultrasound transvaginal scan showing a large lesion with multiple septations and internal echoes.

Magnetic resonance imaging(MRI) pelvis revealed that 11 x 10 x 17.5 cm (TR x AP x CC) sized multilobulated cystic mass, with enhancing septa involving both extra peritoneal compartments in left hemipelvis& hemiabdomen. The mass was insinuating posterior to left psoas muscle fibres along with quadratics lumborum muscle and posterior paraspinial muscle fibres. Possibility of Veno-lymphatic malformation was given likely than a mesenteric or retroperitoneal cyst.

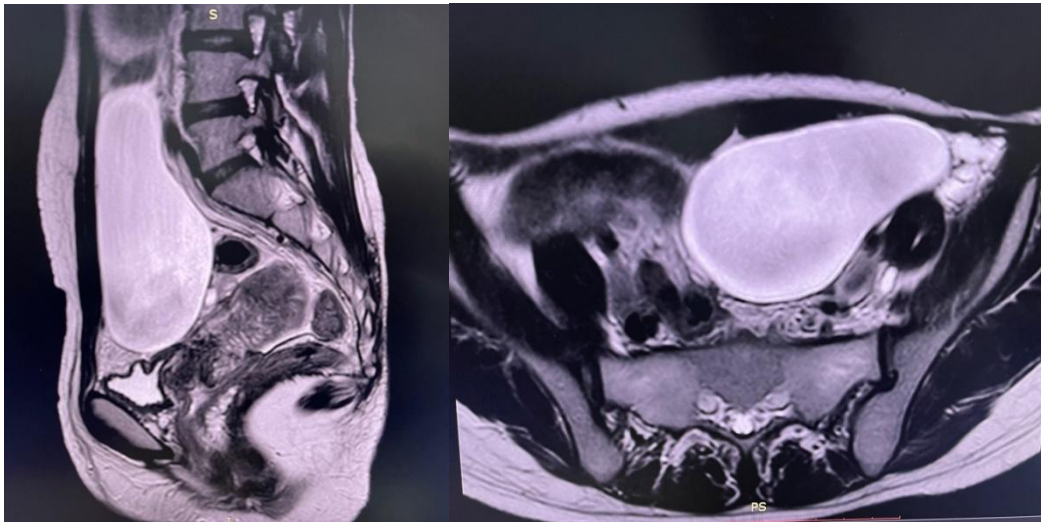


Figure 2:Magnetic resonance imaging(MRI) pelvis showing 11 x 10 x 17.5 cm (TR x AP x CC) sized multilobulated cystic mass, with enhancing septa

Based on the history, clinical presentation, ultrasonography and MRI findings, the decision was made for exploration and proceed after written consent was signed.

### Per-Op:

Patient was taken for elective surgery under general anaesthesia. The parietal peritoneum was densely adhered to the cyst wall, flimsy adhesions were present between the ovary, fallopian tube and the cyst. Meticulous dissection was done to separate the cyst from surrounding structures, taking great care not to injure the adjoining ureter, ovary and fallopian tube. Cyst was excised in toto by exploratory laparotomy via left paramedian approach. Pelvic drain was kept on the right side. Abdomen closed and antiseptic dressing was done. Specimen was submitted for histopathological examination.

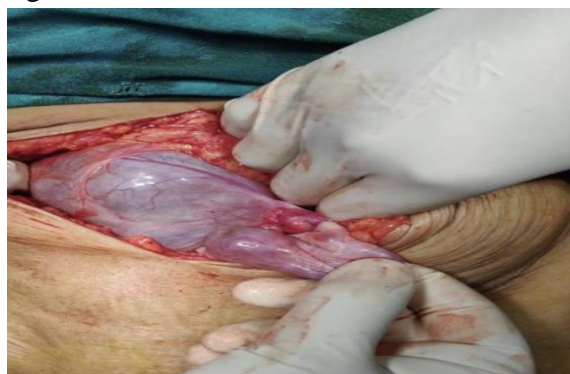

Figure 3: Intraoperative image showing retroperitoneal cyst: fluid filled sac in close relation to the left ovary & fallopian tubes.

**Post-Op:**

Post-operative period was uneventful. Patient was allowed liquids orally, the evening following surgery. Right pelvic drain was removed on 3<sup>rd</sup> post operative day. Patient was discharged with sutures in situ and alternate day dressing with antibiotics advised.

**Histopathology Report:**

Specimen of the cyst was sent for histopathology. Specimen showed cyst wall made up of thick fibro- connective tissue with no lining epithelium. Focal areas of perivascular mixed inflammatory infiltrate noted. No evidence of granuloma or malignancy noted.

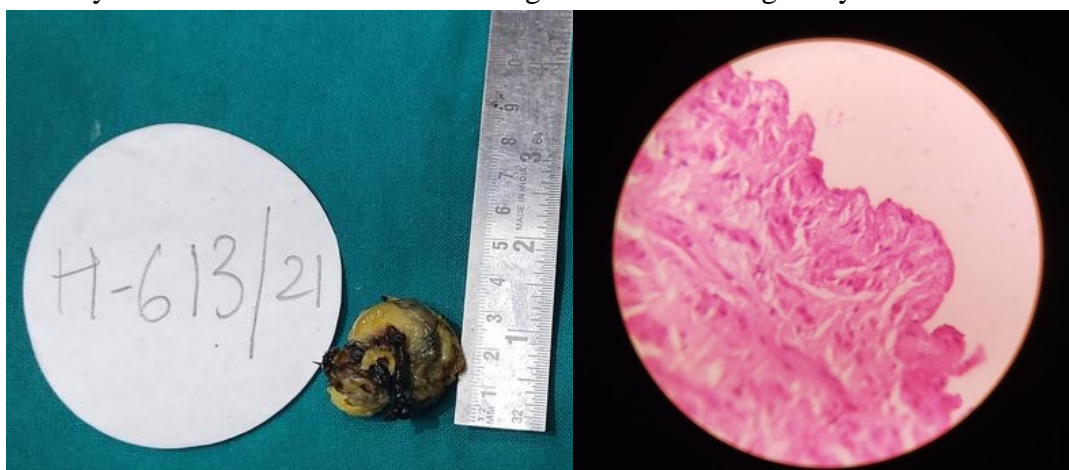


Figure 4: (a) Excised cyst wall (b) High power view showing absence of lining epithelium

**Follow up:**

Patient was followed up for a period of 6 months at 2 months interval. No evidence of post-operative complications and recurrence which was confirmed by imaging.

**DISCUSSION**

Retroperitoneal cysts were described by Handfield in 1929, as cysts that arise in the fatty tissue in the retroperitoneum which have no connection to adult anatomical structure except the areolar tissue.<sup>3</sup>

Yang et al. classified these cysts into neoplastic and non- neoplastic lesions. cystic lymphangioma, cystic teratoma, mesothelioma, Mullerian cyst, epidermoid cyst, tailgut cyst, bronchogenic cyst, pseudomyxoma retroperitonea, cystic change in solid neoplasms, and perianal mucinous carcinoma. Non-neoplastic lesions include pancreatic pseudocyst, non- pancreatic pseudocyst, hematoma, lymphocele, and urinoma.<sup>4</sup>

Based on embryologic origin and histological differentiation, RPCs are classified into (a): Urogenital; (b): Meso-colic; (c): Cysts arising in cell inclusions; (d): Traumatic; (e): Parasitic and (f): Lymphatic. Only those cysts that lie in the retroperitoneum without connection with any adult anatomical structure, except by areolar tissue, are included in this group of cysts.<sup>2-4</sup>

Although RPCs are classified generally as retroperitoneal cysts, one should consider that they lack a true epithelium and are, therefore, considered a separate entity. Pseudocysts commonly occur as a result of an acute attack of pancreatitis. Non-pancreatic RPC, on the other hand, is infrequent and has an unknown aetiology.

Pseudocysts are usually unilocular or multilocular, fluid-filled cysts with thick walls. Long-standing cysts can get calcified and give the classical appearance of an egg shell.<sup>5</sup> There are no pathognomonic signs and characteristic symptoms for non-pancreatic RPC. Most of them attain large size before becoming symptomatic usually by compressing on adjacent structures. Patients usually present with vague abdominal pain, distension, referred pain to legs, lower limb oedema, weight loss, and fever. Occasionally, patients have a sudden onset of abdominal pain which occurs due to infection or haemorrhage within the non-pancreatic RPC itself.<sup>5,6</sup>

On histopathology, the cyst wall contains fibrous tissue without an epithelial lining. Surgical excision is the mainstay of the treatment of the pseudocyst. The cyst has to be excised in toto in order to prevent any recurrence owing to residual cyst wall. The cyst has to be meticulously dissected from the adherent bowel and retroperitoneal structures. In case of large cysts, the fluid can be aspirated and then the dissection continued.<sup>7</sup>

The treatment of RPC is surgery as there is a risk of infection, rupture and malignant change. Surgical options include marsupialization, drainage and cyst excision. Surgical excision can be performed trans-abdominally or retroperitoneally.<sup>8,9</sup>

Present case was managed with exploratory laparotomy via left paramedian approach. Due to the risk of recurrence associated with residual cyst wall, complete excision is recommended and was done in this case.

## CONCLUSION

Non pancreatic pseudocyst are exceedingly rare in occurrence, with no reported cases in females. The aetiology of NPP's still remain unclear. They are usually asymptomatic, till they attain a large size and produce compressive symptoms.

Care has to be taken during dissection of the large pseudocysts as there is possibility of inadvertent injury to the vital structures like duodenum, ureter and major vessels, thereby adding to the morbidity. The cyst wall has to be excised in toto in order to prevent any recurrence.

A laparoscopic excision can be considered if expertise is available as it is quite useful in working in narrow space and is associated with less post-op pain, early recovery and shorter hospital stay. Local recurrence rates in case of total excision are low.

## REFERENCES

1. Guile M, Fagan M, Simopolous A, Ellerkmann M. Retroperitoneal Cyst of Mullerian Origin: A case report and review of the literature. *J of Pelvic Medicine and Surgery*. 2007;13:149–152.
2. Stoupis C, Ros PR, Abbitt PL, Burton SS, Gauger. Bubbles in the belly: imaging of cystic mesenteric or omental masses. *J Radiographics*. 1994 Jul; 14(4):729-37.
3. Handfield-Jones RM. Retroperitoneal cysts: their pathology, diagnosis and treatment. *Br J Surg*. 1924;12:119–134.
4. Yang DM, Jung DH, Kim H, Kang JH, Kim SH, Kim JH, Hwang HY. Retroperitoneal cystic masses: CT, clinical, and pathologic findings and literature review. *Radiographics*. 2004 Sep-Oct; 24(5):1353-65.

5. Prabhu R, Rodrigues G, Sarma YS, Benakatti R. Non- pancreatic retroperitoneal pseudocyst: a benign disease with non-specific symptoms. *BMJ Case Rep.* 2013 Jul 2; 2013.
6. Alzaraa A, Mousa H, Dickens P,J, Benhamida A. <https://www.ncbi.nlm.nih.gov/pmc/articles/PMC2262907/> *J Med Case Rep.* 2008;2:43.
7. Burkett JS, Pickleman J. The rationale for surgical treatment of mesenteric and retroperitoneal cysts. *Am Surg.* 1994 Jun; 60(6):432-5.
8. Alzaraa A, Mousa H, Dickens P, Allen J, Benhamida A. Idiopathic benign retroperitoneal cyst: a case report. *J Med Case Rep.* 2008 Feb 8;2: 43.
9. Allen H, Meng X, Xu C. Laparoscopic excision of simple giant retroperitoneal pseudocyst: case report. *Wu Z, Huang Int J Clin Exp Med.* 2016;9:16856–59.