

COMPARATIVE ANALYSIS OF THE USE OF TOTAL AND BIPOLAR HIP ARTHROPLASTY IN FRACTURES OF THE PROXIMAL FEMUR IN ELDERLY PEOPLE

Republican Specialized Scientific Practical Medical Center of Traumatology and Orthopedics
of the Ministry of Health of the Republic of Uzbekistan

Tashkent city

Alimov Aziz Pulatovich,

Doctor of Medical Sciences, Head of the Department, Traumatologist-Orthopedist of the
Department of Adult Traumatology, State Institution "RSNPMCTO"

Sapaev Ziyat Egamberdievich,

Traumatology's-orthopedist of the Department of Adult Traumatology, State Institution
"RSNPMTSTO"

Shukurov Esondavlat Minziyevich,

Traumatology's-orthopedist of the Department of Adult Traumatology, State Institution
"RSNPMCTO"

Masharipov Kadambay,

Urgench branch of the Tashkent Medical Academy Candidate of Medical Sciences (Senior
Lecturer)

Kamalov Bakhtiyor Khayitovich,

Traumatology's-orthopedist of the Department of Adult Traumatology, State Institution
"RSRSPMCT"

Akbarkhonov Zhavakhir Zhamoliddinovich,

Traumatology's-orthopedist of the Department of Adult Traumatology, State Institution
"RSNPMTSTO"

Kadyrov Raufkhon Rakhmonovich,

Traumatology's-orthopedist of the Department of Adult Traumatology, State Institution
"RSNPMTSTO"

Medical institution: State Institution "Republican Specialized Scientific and Practical Medical
Center of Traumatology and Orthopedics"

Address: 100047, st. Makhtumkuli, 78, Tashkent, Uzbekistan

Email address(es): niito-uz@yandex.r

Corresponding author: Sapaev Ziyat Egamberdievich

As is known, for fractures of the femoral neck over the age of 60, the operation of choice is hip arthroplasty. It should be noted that after surgical treatment the number of complications and unsatisfactory functional results remains very high and reaches 30%. All patients in the preoperative period underwent Multiline computed tomography and X-ray densitometry studies. All 67 patients underwent hip arthroplasty. For comparison, patients were divided into 2 groups with this injury using total and bipolar arthroplasty in this age aspect. Total arthroplasty was performed in 32 patients, bipolar arthroplasty in 35 patients. End prosthetics for fractures of the proximal femur in elderly patients is the most optimal method of surgical treatment in terms of the fastest restoration of the support ability and function of the lower limb in this category of patients. The use of femoral components with a bipolar head MERIL (India) in old age helps to reduce the volume and duration of surgery in patients with concomitant somatic diseases.

Key words: hip fracture, arthroplasty, X ray, densitometry, femoral componen

INTRODUCTION

As is known, for fractures of the femoral neck over the age of 60, the operation of choice is hip arthroplasty. The use of osteosynthesis in basal, pertrochanteric and intertrochanteric fractures in this age group does not always allow achieving the desired result from the operation, which is associated with low bone mineral density, the presence of diabetes mellitus, the development of complications (hypostatic pneumonia, bedsores, etc.) [3,4,20,26].

In a young patient, and historically in all patients, osteosynthesis was considered the gold standard for fractures of the proximal femur, regardless of the nature of the fracture, but common complications that have arisen in old age with fractures of the proximal femur, including the pseudarthrosis, improperly fused fractures and aseptic necrosis of the femoral head has led surgeons to perform arthroplasty, and the number of such interventions is growing. [6,7,22,24,25,27,28-30]

It should be noted that after surgical treatment the number of complications and unsatisfactory functional results remains very high and reaches 30%. Reoperations after osteosynthesis in KPOFB are largely associated with errors in the choice of the treatment method, violation of the method of implantation of metal structures and the operation technique, and with improper postoperative management of the patient. [8,9,12,15,17,18,19,31].

Consequently, when choosing surgical tactics, it seems very important to be guided not only by the nature of the fracture itself and the presence of the individual's capabilities for osseointegration after osteosynthesis against the background of osteoporosis, degenerative-dystrophic diseases of the joint and metabolic syndrome. [6,7,9,27,30].

Although stable fixation of the fracture can allow the fracture to heal and return to normal function in these patients, we must be aware of the significant risks associated with attempting fracture fixation in these patients with poor bone quality. There are several evolving techniques and materials that can assist in this endeavor, although it is important to keep in mind that for some types of fractures, total arthroplasty of the joints may more quickly return these patients to their pre-traumatic level of functioning. [1]

In general, the results of treatment with osteosynthesis of the proximal femur in posttraumatic arthrosis are worse than in primary indications. It is not possible to fix the fracture of the femoral neck, as a rule, is the result of a significant displacement of bone fragments, poor bone quality, the patient's age, or inadequate fixation technique. [26]

Long-term randomized controlled trial and meta-analysis involving nearly 1200 patients. Revealed favorable outcomes in the treatment of fractures of the proximal femur, which were treated with arthroplasty in elderly patients [4].

MATERIAL AND RESEARCH METHODS

In the Department of Adult Traumatology of the RSSPO of the MH of the RUZ Clinic of the Ministry of Health of the Republic of Uzbekistan, patients aged 65 years and older with fractures of the proximal femur, depending on the state of bone mineral density, the presence of degenerative changes in the hip joint and metabolic syndrome, in 67 patients were used the arthroplasty system. Of the 67 patients, the vast majority were 55 women and twelve men, aged 65 to 86 years (mean age 78 years). We observed a basal fracture of the

femoral neck in 17 patients, a pertrochanteric fracture of the femur - 39, an intertrochanteric fracture - 10, a fracture of the upper third of the diaphysis - 1 (rheumatoid coxarthrosis on the side of the fracture). In 59 patients with fractures of the proximal femur according to the AO / ATO classification, they were unstable.

All patients in the preoperative period underwent Multislice computed tomography and X-ray densitometric studies. Multislice computed tomography made it possible to determine the nature of the fracture, the choice of the femoral component of the endoprosthesis. X-ray densitometry determined the indicators of bone mineral density; at low levels (osteoporosis, osteopenia with a risk of fracture of more than 20%), osteosynthesis was excluded and the choice was in favor of hip arthroplasty.

The systemic assessment of bone mineral density was carried out by the method of dual-energy X-ray absorptiometry (DEXA) on the DMS Group "Stratus" apparatus (France, 2011) according to the standard program on the proximal femur. Digital radiography of the knee joints was performed using standard ROI (regions of interest, R1-5) points in frontal and lateral projections before surgery.

Based on the recommendations of the WHO experts [WHO, 1994], osteoporosis and osteopenia in dual-energy X-ray densitometry were verified by the densitometric indicator - T-criterion, where, the value of standard deviations of the T-criterion up to - 0.1 is the norm; the value of standard deviations of the T-criterion from - 1.0 to - 2.5 - osteopenia; the value of standard deviations of the T-criterion is 2.5 and below - osteoporosis.

Another indicator of densitometry T-score is higher or equal - 1.0 "there is an effect", if lower - 1.0 "there is no effect". The patients observed by us had densitometric indices within the limits of osteopenia and osteoporosis.

For basal fractures of the femoral neck, standard designs of the femoral component of the total hip joint endoprosthesis were used; for transtrochanteric and intertrochanteric fractures of the femur, the Wagner stem of the Zimmer revision system endoprosthesis was used with the use of cerclage and, in some cases, for stable fixation, transfragmental vinasseous osteosynthesis was performed. The technical holes on the Zweimuller stem (Zimmer alloclassic) made it possible to fix the fragments of the greater trochanter with a lavsan or to carry out a wire suture, depending on the nature of the fracture fragments. In 3 patients with severe osteoporosis, a cement version of the hip joint endoprosthesis with a revision femoral component was used. In patients with severe clinical manifestations of concomitant somatic diseases, a bipolar arthroplasty system was used in order to reduce the trauma and the time of surgery.

On the third or next day after the operation, the patients were allowed to move with the help of improvised support (most often a walker) without loading the operated lower limb and to carry out active movements in the adjacent joints.

Earlier, the clinic used the Wagner, Zweimuller total arthroplasty system from Zimmer (USA), these were tapered legs with distal fixation, additionally cerclage and transfragmentary screws were used. In the postoperative observation of zo patients after endoprosthetics with these systems, we noted an increase in the duration of surgery, blood loss and aggravation of the general somatic condition due to the presence of concomitant diseases, especially in patients over 70 years of age. Further, in patients who underwent arthroplasty with the use of the Wagner femoral revision system in complicated cases of inflammation, performing the second stage of arthroplasty after infection presented large technical and material costs for both the patient and the doctor. In this regard, in order to

minimize surgical intervention in patients with fractures of the proximal femur in old age, it was customary to use bipolar arthroplasty systems from MERIL (India). Therefore, for comparison, patients were divided into 2 groups with this injury using total and bipolar arthroplasty in this age aspect. Total arthroplasty was performed in 32 patients, bipolar arthroplasty in 35 patients.

RESULTS AND DISCUSSION

The results of the performed surgical treatment were assessed using the Harris hip joint scale. According to this scale, with total arthroplasty using Zimmer systems (USA),

Endoprosthesis type Evaluation criteria	Total endoprosthesis	Bipolar endoprosthesis
Duration of surgery	av 87 minutes	av 54 minutes
blood loss	av 300 ml.	av 210 ml.
Early rehabilitation (load on n / a)	7 days	2-3 days
Harris is a good result	9	16
- satisfactory	21	19
- unsatisfactory	2	-

good results were obtained in 9 patients, satisfactory in 21 cases.

Two patients developed bedsores of the coccyx-sacral region with limited movement and support in the lower limb. The use of bipolar arthroplasty of the MERIL company (India) in patients with fractures of the proximal femur in old age, the values on the Harris rating scale were better, so out of 35 patients good results were obtained in 16 cases, satisfactory 19, we did not observe unsatisfactory results (Table No. 1).

Table # 1.

As a criterion for evaluating the effectiveness of the performed surgical treatment, we also included the duration of the intervention, blood loss, and the beginning of the load on the operated limb. The duration of surgery for total arthroplasty varied from a minimum value of 75 minutes to a maximum of 95 minutes, the average indicator in 32 patients was 87 minutes, when using bipolar arthroplasty, the operation took significantly less time, minimum 45 minutes to a maximum of 75 minutes, on average 54 minutes in 35 patients. These blood loss also confirm a low loss in the group of patients who underwent bipolar arthroplasty. It follows from this that the use of total arthroplasty with a revision component significantly increases the time of surgery, as well as, accordingly, blood loss and worsens the results of surgical treatment. In addition, early rehabilitation of patients after total arthroplasty began at a later time after surgery, when, as with bipolar arthroplasty, it is possible, depending on the general condition of the patient, to carry out early rehabilitation with a load on the operated limb on the first day, which is very important for the activity of the muscles of the lower limb in prevention of thrombus formation in this old age.

In the form of illustrations, we give examples of cases of surgical intervention with favorable outcomes.

Patient M.K., 82 years old. Was admitted to the department on an emergency basis with a diagnosis of Closed per trochanteric fracture of the right femoral neck with displacement of bone fragments. concomitant diseases: IHD exertional angina FC III st. After

preoperative preparation, the patient underwent an operation of end prosthetics of the right hip joint with a Zimmer end prosthesis and a Wagner femoral component with cerclage and screw fixation. The postoperative course is smooth, the wound healed initially, the patient was discharged on the 14th day after surgery (Fig. 1, 2, 3).

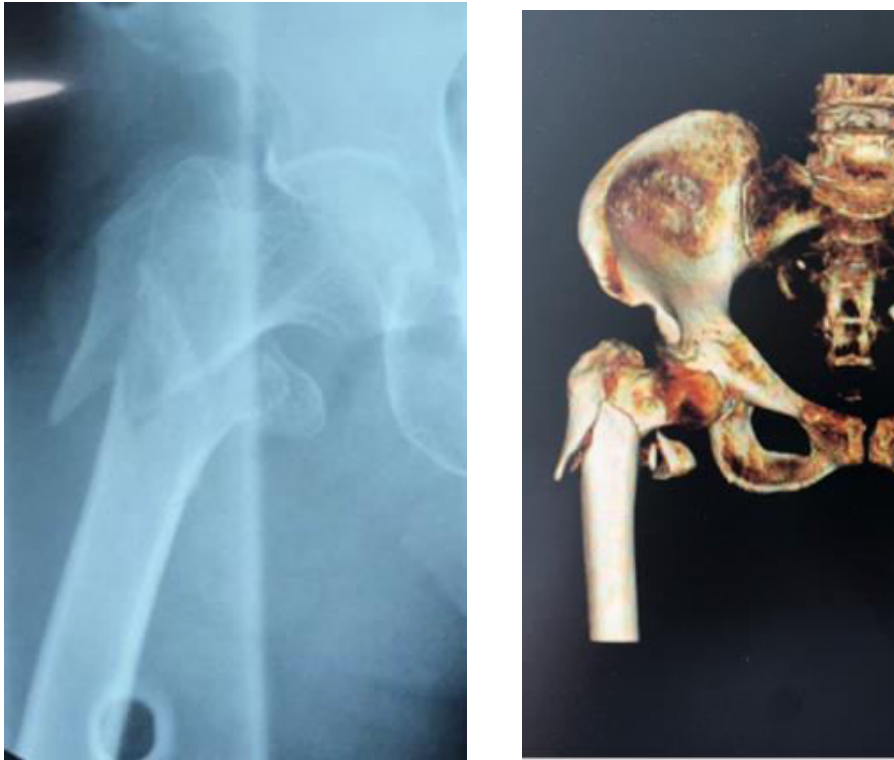

Fig 1. X-ray and MCT of patient M.K 82 before surgery.

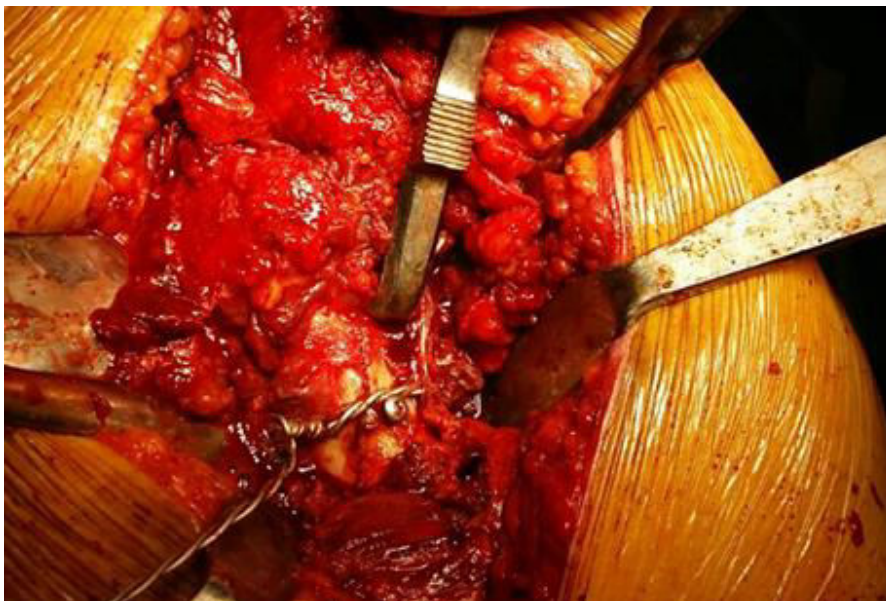

Fig 2. Fixation of bone fragments.

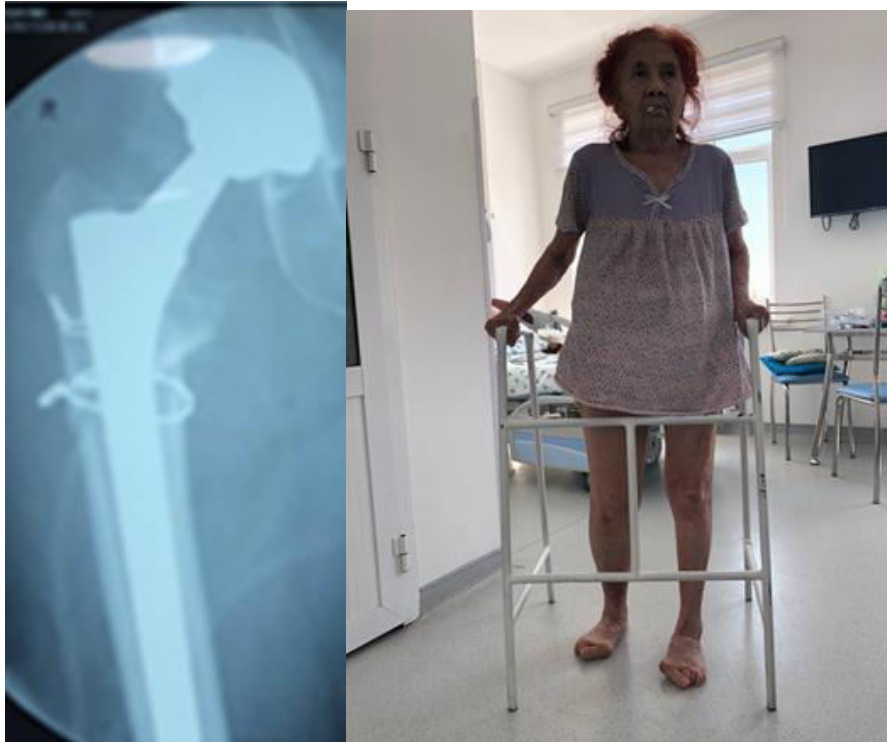

Fig 3. Radiograph and view of the patient M.K 82 after the surgery.

Patient A.O is 70 years old. The department was admitted with complaints of pain in the right hip joint and limitation of movement. From the anamnesis, having received an injury 3 months before treatment, she was treated conservatively in a derogation plaster cast at the place of residence. The patient was examined, the diagnosis was made: Slowly malformed per trochanteric fracture of the right femur with a detachment of the lesser trochanter. concomitant diseases of ischemic heart disease exertional angina FC III st, type 2 diabetes mellitus. After preoperative preparation, the patient underwent an operation of the right hip arthroplasty with the Meril end prosthesis with a bipolar head. The postoperative course is smooth, the wound healed initially, the patient was discharged on the 12th day after surgery (Fig. 4.5).

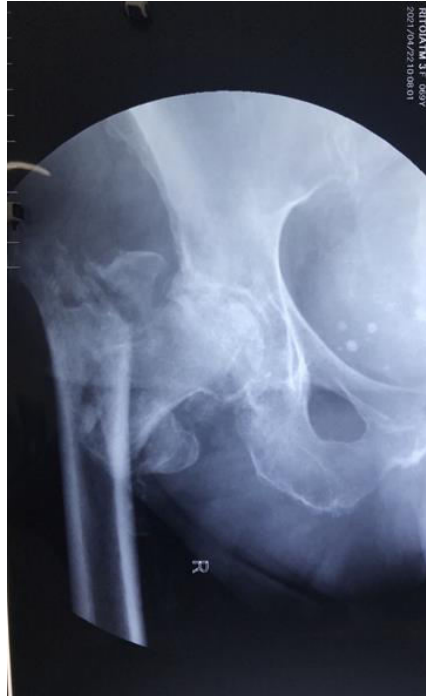

Fig 4. Radiograph of patient A.O 70 years old before surgery.

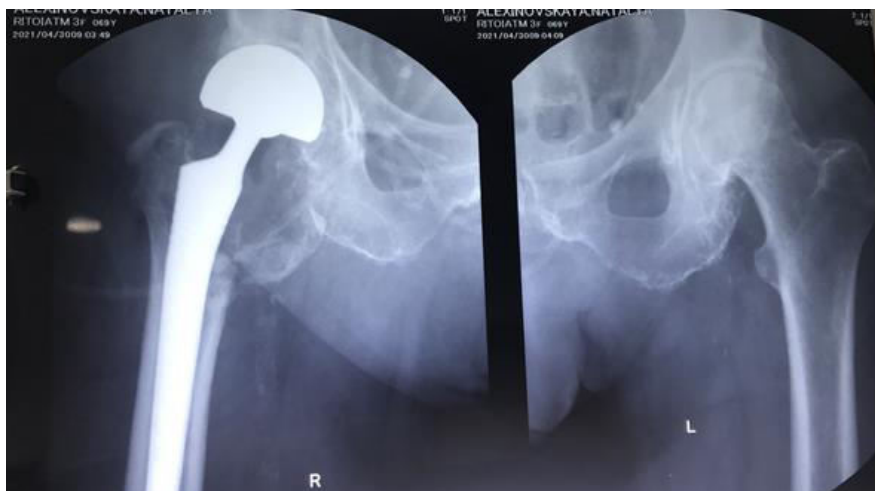

Fig 5. Radiograph of patient A.O 70 years after surgery.

Patient M., 81 years old. The department was admitted with complaints of pain in the right hip joint and limitation of movement. From the anamnesis she received an injury the day before treatment. The patient was examined and diagnosed with a closed pertrochanteric fracture of the right femur with a detachment of the lesser trochanter. Concomitant diseases of coronary artery disease exertional angina FC III grade, diabetes mellitus, insulin-dependent. After preoperative preparation, the patient underwent an operation of the right hip arthroplasty with the Meril end prosthesis with a bipolar head. The postoperative course is smooth, the wound healed initially, the patient was discharged on the 12th day after surgery (Fig. 6.7).

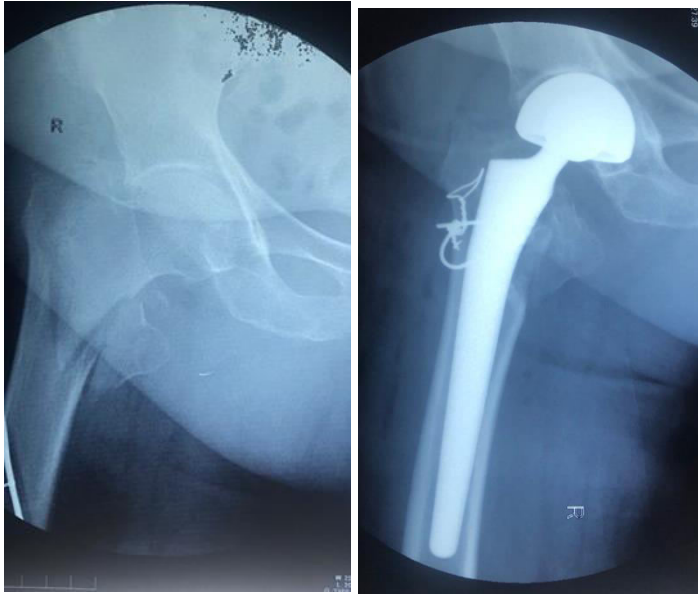


Figure 6.7 Radiograph of patient M.K 81 before and after surgery.

CONCLUSIONS

Endoprosthetics for fractures of the proximal femur in elderly patients is the most optimal method of surgical treatment in terms of the fastest restoration of the support ability and function of the lower limb in this category of patients.

The system of femoral components of the Wagner (Zimmer) hip endoprosthesis allows stable fixation of bone fragments with cerclage and screws, but it takes more time and increases blood loss, which affects the outcomes of surgery.

The use of femoral components with a bipolar head MERIL (India) in old age helps to reduce the volume and duration of surgery in patients with concomitant somatic diseases.

REFERENCES :

1. Arthroplasty for the Treatment of Fractures in the Older Patient Joseph Borrelli Jr., Jeffrey O.(2018)
2. Augat P, Goldhahn J. Osteoporotic fracture fixation –a biomechanical perspective. *Injury*. 2016;47:S1–2. [https://doi.org/10.1016/S0020-1383\(16\)47001-4](https://doi.org/10.1016/S0020-1383(16)47001-4).
3. Bercik MJ, Miller AG, Muffly M, et al. Conversion total hip arthroplasty: A reason not to use cephalomedullary nails. *J Arthroplasty*. 2012;27(8 suppl):117–121.
4. Bhandari M, Devereaux PJ, Swiontkowski M, et al. Internal fixation compared with arthroplasty for displaced fractures of the femoral neck. *J Bone Joint Surg Am*. 2003;85(9):1673–1681.
5. Bjørnerem Å. The clinical contribution of cortical porosity to fragility fractures. *Bonekey Rep*. 2016;5:1– 5. <https://doi.org/10.1038/bonekey.2016.77>.
6. Bogunovic L, Cherney SM, Rothermich MA, Gardner MJ. Biomechanical considerations for surgical stabilization of osteoporotic fractures. *Orthop Clin North Am*. 2013;44:183–200. <https://doi.org/10.1016/j.ocl.2013.01.006>.
7. Chammout G, Mukka S, Carlsson T, et al. Total hip replacement versus open reduction and internal fixation of displaced femoral neck fractures. A randomized long-term follow-up study. *J Bone Joint Surg Am*. 2012;94(21):1921–1928.

8. Cornell CN, Ayalon O. Evidence for success with locking plates for fragility fractures. *HSS J.* 2011;7:164–9. <https://doi.org/10.1007/s11420-010-9194-8>
9. D'Arrigo C, Perugia D, Carcangiu A, et al. Hip arthroplasty for failed treatment of proximal femoral fractures. *Int Orthop.* 2010;34(7):939–942.
10. Féron JM, Mauprivez R. Fracture repair: general aspects and influence of osteoporosis and anti-osteoporosis treatment. *Injury.* 2016;47:S10–4. [https://doi.org/10.1016/S0020-1383\(16\)30003-1](https://doi.org/10.1016/S0020-1383(16)30003-1).
11. Gardner MJ, Collinge C. Management principles of osteoporotic fractures. *Injury.* 2016;47:S33–5. [https://doi.org/10.1016/S0020-1383\(16\)47006-3](https://doi.org/10.1016/S0020-1383(16)47006-3).
12. Giannoudis P, Tzioupis C, Almalki T, Buckley R. Fracture healing in osteoporotic fractures: is it really different?. A basic science perspective. *Injury.* 2007;38:0–9. <https://doi.org/10.1016/j.injury.2007.02.014>.
13. Goldhahn J, Suhm N, Goldhahn S, et al. Influence of osteoporosis on fracture fixation – a systematic literature review. *Osteoporos Int.* 2008;19:761–72. <https://doi.org/10.1007/s00198-007-0515-9>.
14. Haidukewych GJ, Ricci W. Locked plating in orthopaedic trauma: a clinical update. *J Am Acad Orthop Surg.* 2008;16:347–55. Cornell CN. Internal fracture fixation in patients with osteoporosis. *J Am Acad Orthop Surg.* 2003;11:109–19
15. Haidukewych J, Berry DJ. Hip arthroplasty for salvage of failed treatment of intertrochanteric hip fractures. *J Bone Joint Surg Am.* 2003;85(5):899–904.
16. Kammerlander C, Erhart S, Doshi H, et al. Principles of osteoporotic fracture treatment. *Best Pract Res Clin Rheumatol.* 2013;27:757–69. <https://doi.org/10.1016/j.berh.2014.02.005>.
17. Laffosse JM, Molinier F, Tricoire JL, et al. Cementless modular hip arthroplasty as a salvage operation for failed internal fixation of trochanteric fractures in elderly patients. *Acta Orthop Belg.* 2007;73(6):729–736.
18. Laffosse JM, Molinier F, Tricoire JL, et al. Cementless modular hip arthroplasty as a salvage operation for failed internal fixation of trochanteric fractures in elderly patients. *Acta Orthop Belg.* 2007;73(6):729–736.
19. MacLeod AR, Simpson AHRW, Pankaj P. Reasons why dynamic compression plates are inferior to locking plates in osteoporotic bone: a finite element explanation. *Comput Methods Biomech Biomed Engin.* 2015;18:1818–25. <https://doi.org/10.1080/10255842.2014.974580>.
20. Osterhoff G, Morgan EF, Shefelbine SJ, et al. Bone mechanical properties and changes with osteoporosis. *Injury.* 2016;47:S11–20. [https://doi.org/10.1016/S0020-1383\(16\)47003-8](https://doi.org/10.1016/S0020-1383(16)47003-8).
21. Parker J, Handoll HH. Replacement arthroplasty versus internal fixation for extracapsular hip fractures in adults. *Cochrane Database Syst Rev.* 2006;2:CD000086.
22. Pesántez RF, Olarte CM, Salavarieta J. Evaluation and treatment of nonunions in the osteoporotic patient. *Curr Geriatr Rep.* 2014;3:128–34. <https://doi.org/10.1007/s13670-014-0083-8>.
23. Silva MJ. Biomechanics of osteoporotic fractures. *Injury.* 2007;38:69–76. <https://doi.org/10.1016/j.injury.2007.08.014>.
24. Stoffelen D, Haentjens P, Reynders P, et al. Hip arthroplasty for failed internal fixation of intertrochanteric and subtrochanteric fractures in the elderly patient. *Acta Orthop Belg.* 1994;60(suppl 1):135–139.
25. Tarantino U, Saturnino L, Scialdoni A, et al. Fracture healing in elderly patients: new challenges for antiosteoporotic drugs. *Aging Clin Exp Res.* 2013;25:105–8. <https://doi.org/10.1007/s40520-013-0096-8>.

26. The Adult Hip, Hip arthroplasty surgery John J. Callaghan, MD Aaron G. Rosenberg, MD Harry E. Rubash, MD Craig J. Della Valle, MD Paul E. Beaulé, MD John C. Clohisy, MD (2017)
27. Tinubu J, Scalea TM. Management of fractures in a geriatric surgical patient. *Surg Clin North Am.* 2015;95:115–28. <https://doi.org/10.1016/j.suc.2014.09.017>.
28. Tscherne Unfallchirurgie Norbert P. Haas • Christian Krettek (2012)
29. Von Rüden C, Augat P. Failure of fracture fixation in osteoporotic bone. *Injury.* 2016;47:S3–S10. [https://doi.org/10.1016/S0020-1383\(16\)47002-](https://doi.org/10.1016/S0020-1383(16)47002-)
30. Yaacobi E, Sanchez D, Maniar H, Horwitz DS. Surgical treatment of osteoporotic fractures: an update on the principles of management. *Injury.* 2017. <https://doi.org/10.1016/j.injury.2017.08.036>.
31. Zhang B, Chiu KY, Wang M. Hip arthroplasty for failed internal fixation of intertrochanteric fractures. *JArthroplasty.* 2004;19(3):329–333.