

# Effects Of Tyrosine Kinase Inhibitors (Nilotinib) On Male Mice Infertility

Khaleed J Khaleel<sup>1</sup>, Mohanad Mahdi Al-Hindawi<sup>2</sup>, Lieth Husein alwan<sup>3</sup>, Alaa Abbas Fadhel<sup>4</sup>

<sup>1,2,3</sup>*Iraqi Center for cancer and medical genetics research// Al-Mustansiriyah University,  
Iraq.*

<sup>4</sup>*Al- Mussaib Technical College / Al-Furat Al-Awsat Technical University, 51009, Babylon,  
Iraq.*

*E-mail* <sup>1</sup>*Khaleeliccmgr@uomustansiriyah.edu.iq*

## **ABSTRACT**

*Nilotinib (Tasigna™) a tyrosine kinase inhibitor is used in the treatment of chronic myelogenous leukemia and other tumor entities, this study aims to investigate nilotinib effects on fertility in male albino mice three groups each with 7 male albino mice selected, one control group, and two groups administered with 80mg/kg and 120mg/kg respectively for 3 months and serum levels of testosterone, FSH, and LH were measured by ELISA kits and statistically analyzed. Histological sections from testes prepared and stained with H&E stain and evaluated histopathologically. Statistically significant reduction in the mean of serum testosterone and FSH were seen in treated groups compared with the control group with no significant differences regarding LH concentration; variable histological changes noted in comparison with the control group ranging from mild changes in most cases with more severe atrophic changes in 1 case from the group(2) and 2 cases in a group (3). Our results showed statistically significant changes in testosterone and FSH levels in mice administered with nilotinib with variable deleterious histopathological changes*

## **1. INTRODUCTION**

Nilotinib is an orally administered aminopyrimidine-derivative inhibitor of BCR-ABL kinase described in 2005 by Weisberg E. *et al*(1). The drug was designed to overcome resistance to imatinib and is many times more potent than imatinib with additional inhibitory action against other tyrosine kinases including c-kit and platelet-derived growth factor receptor (PDGFR) (2)

Drugs used for treating cancers often but not always have variable effects on fertility, pregnancy, and children's health and development; tyrosine kinase inhibitors including the second generation nilotinib are being used increasingly with success and safety for about 20 years since imatinib FDA approval in 2001. Because the targeted molecules of these drugs which derive the carcinogenesis in several tumor entities are also important for normal cell functions, testing for any possible deleterious effects on male fertility is necessary especially for the young patients

c-kit receptor and its ligand SCF (stem cell factor) play important role in spermatogonial cell proliferation and differentiation and hence inhibition of these molecules may have a negative effect on spermatogenesis (3)(4)

PDGF is another target for tyrosine kinase inhibitors and this inhibition is responsible for some of the undesirable effects related to fertility and embryo development, for instance, PDGF signaling is important for Leydig cell function and survival (5) and PDGF receptor

beta is important for gonocytes (spermatogonia precursors) proliferation and migration during neonatal development (6)

Despite all these potential effects of tyrosine kinase inhibitors on the integrity of male fertility, in addition to other deleterious effects on folliculogenesis and increase atretic follicles with the use of these inhibitors(7) reports of successful pregnancies in patients on treatments are recorded(8)

To the best of our knowledge studies about nilotinib effects on reproductive health in mice are few and even fewer on humans and this study will further help to understand these effects which will assist stratifying and estimating risk in humans especially young patients or patients during puberty

## 2. MATERIALS AND METHODS

The current study was included (21) male mice (Albino, BALBOAS/c). They were taken from the experimental animal house of Iraqi center for cancer and medical genetics research, Mustansiriyah University (Baghdad, Iraq). The age of the involved mice was 30 days and their weight ranged from 19 to 21 grams. They were never entered in any research before.

The mice are kept in custom cages made for mice under standard environment with temperature ranged (22± 1c). The animals were supplied by fabricated pellets made for small animals. Also, fresh tap water was provided daily, and mice were divided into three groups including group (1) normal control group (7 mice without treatment), group (2) was treated with 1.6 mg of nilotinib for each mouse (80 MG / kg)(7 mice), group (3) was treated with 2.4 mg of nilotinib for each mouse (120/MG / kg )(7 mice).

Nilotinib ( Tasigna , Novartis Pharma , Basel , Switzerland) dissolved into sterile distilled water after well homogeneous solution. The dissolved drug was given to each male mouse orally by mice gavage (stomach tube) for five days per week for three months at doses described before. At the end of the three months blood were collected from the heart of each mouse of the three groups and hormonal assay was performed for testosterone (T), follicular stimulating hormone (FSH), and luteinizing hormone (LH), Using ELISA kits and the results were obtained. by micro plate reader Awernace (US).

Furthermore, Testicular tissues were fixed in 10% (w/v) neutral-buffered formalin and embedded in paraffin after adequate dehydration and clearing. From each paraffin block single 5Mm thick section was prepared and stained with hematoxylin and eosin (H&E). This study obtained the ethical approval by local ethical committee at (1. 04.2018). Statistical analysis were performed using SPSS Ver. 23 (IBM, Armonk, NY, USA) windows 7 operating system.

## 3. RESULTS

### *Hormonal biochemical assay:*

The three hormones were assessed, this include T, FSH, and LH, The result of T hormone was showed that group (2) (80mg/kg) with (6.78 ± 0.84) was significantly lower than that of the control group (8.01 ± 0.96) with p-value of 0.032, (Table 1, 2). Also, the T hormone in group (3) (120mg/ kg) demonstrates significant lower level than control group( 4.75 ± 1.66, 8.01 ± 0.96) respectively P-value of 0.01.

While the outcomes of LH hormone group indicated that there is non-significant differences between groups (2) and group (3) and the control group.

However, FSH hormone results revealed that group (2) is significantly lower than the control group (3.92 ± 2.81 , 7.98 ± 2.88 ) respectively with (p value of 0.026). Moreover, our data

identified a significant difference between group (3) and control group with P Value of 0.001. ( $2.46 \pm 1.80$ ,  $7.98 \pm 2.88$ ) respectively. (Table 2)

Table 1: Comparison between control group and group receiving 80 mg / kg nilotinib

| Parameters   | Control (group 1) | 80mg/kg (group 2) | P -value |
|--------------|-------------------|-------------------|----------|
| FSH          | $7.98 \pm 2.88$   | $3.92 \pm 2.81$   | 0.026    |
| LH           | $2.83 \pm 1.21$   | $2.69 \pm 0.99$   | Ns       |
| Testosterone | $8.01 \pm 0.96$   | $6.78 \pm 0.84$   | 0.032    |

$P \leq 0.05$  significant, Ns: non-significant

Table 2: Comparison between control group and group receiving 120 mg/kg nilotinib

| Parameters   | Control (group 1) | 120mg/kg (group 3) | P -value |
|--------------|-------------------|--------------------|----------|
| FSH          | $7.98 \pm 2.88$   | $2.46 \pm 1.80$    | 0.01     |
| PCV          | $2.83 \pm 1.21$   | $2.44 \pm 0.52$    | Ns       |
| Testosterone | $8.01 \pm 0.96$   | $4.75 \pm 1.66$    | 0.01     |

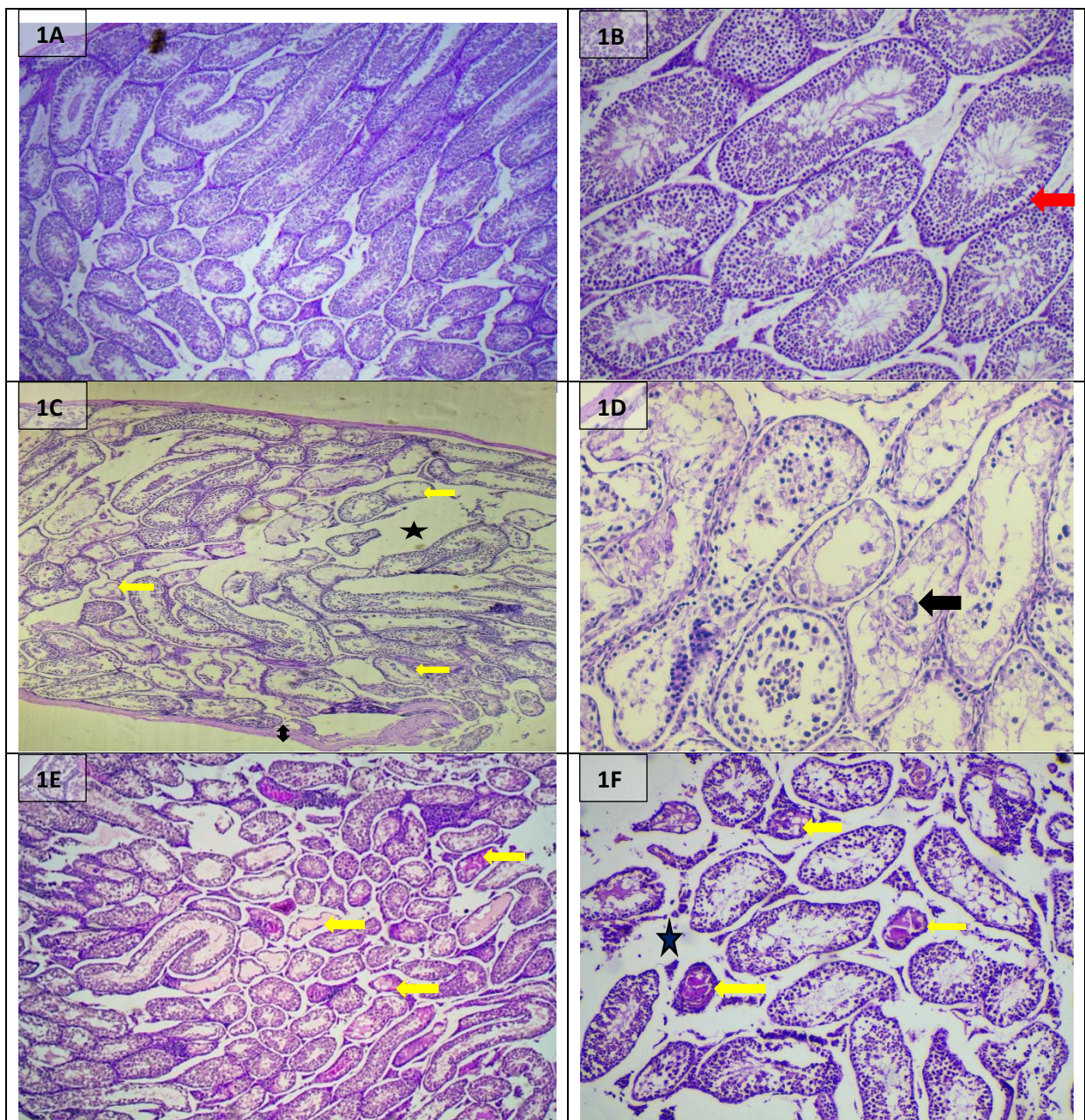
$P \leq 0.05$  significant, Ns: non-significant

#### *Histopathological evaluation*

Examination of the testicular histological sections from the control group showed thin tunica albuginea with compacted rounded to oval or elongated seminiferous tubules with little interstitial tissue in between composed of scattered to small clusters of leydig cells with intact active spermatogenesis being founded in each examined tubule with no evident abnormalities in either germ cells or sertoli cells or in their maturation pattern, however tubules lying just adjacent to tunica albuginea showed features of processing artifacts and was identifiable in each case of this group in addition to rare vacuolation and spacing scattered in remaining tubules and in one case very few tubules with reduced diameters also observed as shown in *Figure 1a and 1b*

Compared to the control group, Sections from the second group of mice treated with 80mg/kg per day of Nilotinib showed mostly subtle to mild histomorphological changes with active spermatogenesis being identifiable in nearly all examined tubules, however significant pathological changes seen in only one case with multifocal reduced and disrupted spermatogenesis; most of this group testicular sections showed unremarkable non-thickened tunica albuginea, although objective measurements of the tunica was not attempted, unremarkable interstium to focally slight increase in interstitial space with no remarkable changes in the interstitial components including leydig cells viability or numbers; scattered seminiferous tubules were seen to show vacuolation/spacing in their germinal epithelium of macrovacoular type(**Figure 1c**), or occasional separation of germinal epithelium from underlying basement membranes with undulation, rare tubules with luminal sloughing were also seen with intact spermatogenesis(from spermatogonia to elongated spermatids and sperms) in nearly all tubules despite the above aforementioned morphological changes; in the single affected case significant changes noted summarized by increase distancing between adjacent tubules with expansion of interstitial spaces, variability in tubular sizes with foci in which adjacent tubules seen to be distorted with either small diameters and moderate to marked hypocellularity leaving in some tubules the mere presence of sertoli cells which were either intact or detached undergoing necrosis and with accumulation of eosinophilic luminal secretions( **Figure 1d**)

Regarding the third group of mice which were given 120mg/kg/day of nilotinib, a spectrum of changes noted when compared with the control group and these changes were either subtle in 3 cases to more obvious in 2 cases to more significant in 2 other cases. In 3 cases from this group occasional to few tubules showed vacuolation/spaces or focal separation in germinal epithelium, spermatogenesis was ordered and active in all examined tubules; in two more cases of this group few scattered seminiferous tubules showed features of atrophy with small diameters and hypocellularity of moderate to severe type some accumulating eosinophilic luminal secretions, in addition to vacuolation/separation and sloughing of tubular epithelium scattered across testicular sections; finally in the two more significantly affected cases multifocal a atrophy of seminiferous tubules was noted with moderate to severe reduction in spermatogenesis accompanied by degenerated/necrotic germ cells and sloughed multinucleated cells, in addition frequent vacuolation and sloughing were observed with focal increase in interstitial spaces but no significant changes in the amount of connective tissue or leydig cells (**Figure 1e**)



**Figure (1):** Effect of nilotinib on testicular histology; 1A and 1B: low and intermediate power view of testicular sections from control group showing intact active spermatogenesis with occasional focal separation of germinal epithelium (red arrow); 1C and 1D: low and high power view of testicular section from second group case receiving 80mg/kg, showing frequent atrophic tubules (yellow arrows in 1C) with reduced to absent spermatogenesis leaving only degenerated sertoli cells with desquamated multinucleated cell (black arrow) with thickened tunica albuginea (black up down arrow); 1E and 1F: low and high power view from the group receiving (120mg/kg) showing atrophied tubules some filled with eosinophilic secretions (yellow arrows) with widened interstitial space (asterix)

#### 4. DISCUSSION

Tyrosine kinase inhibitors (TKIs) are among the most successful targeted anti-cancer treatments that revolutionized therapy in various tumors; since the approval of Imatinib mesylate in 2001 for the treatment of chronic myeloid leukemia (CML), an ever increasing numbers of patients were brought into disease control with near normal life expectancy; newer generations of tyrosine kinase inhibitors were developed and still emerging to overcome resistance or tolerance to Imatinib or for treating tumors with other constitutively activated tyrosine kinases than BCL-ABL seen in CML; because of the success of the various TKIs in treating those neoplastic growths and the increasing survival, issues of maintaining fertility and ability to conceive continued to rise since these are chronic treatments and they are speculated to interfere with several functions of the developing gonads, germ cells, sperms, leydig cells and growing embryos; (9) data from various animal and human studies showed conflicting results regarding TKIs effects on male fertility with imatinib being the most widely studied. Tyrosine kinase inhibitors were shown in several papers to adversely affect the biochemical and endocrine profile of experimental animals and patients on treatment; a decrease in intratesticular testosterone and a rise in intratesticular LDH was noted after Imatinib treatment for variable periods in Swiss albino mice, the level of intratesticular testosterone is thought to play an important role in regulating spermatogenesis and this reduction in the hormone level is presumed to be the result of C-kit and PDGFR inhibition by the drug which have adverse effect on the process of leydig cell differentiation (10). Imatinib mesylate was also found to result in significant lowering of serum testosterone with elevation of both LH and FSH in Wistar rats in dose dependent way (11), yet in another study on human CML patients treated with different TKIs the levels of testosterone, LH and FSH were all decreased after 4 months of treatment besides reduction in sperm parameters and these effects were less pronounced with Dasatinib than Imatinib and Nilotinib (12) Regarding morphological effects of TKIs on testicular histology, several studies showed deleterious effects of various TKIs on developing gonads in immature animals which returned to normal as animals aged (13) (6), other studies on both animals and humans showed reduction of testicles and epididymis weights with reduced motile sperm percentage at even less than the maximum clinical dose based on body surface area in one study (14); however other studies did not find significant effects on either spermatogenesis or folliculogenesis in mice received treatment dose of Imatinib (150mg/kg) (15) Nilotinib is a second generation inhibitor of tyrosine kinases first time used in treatment in 2006, it inhibits BCR-ABL same way Imatinib does besides inhibiting other TKs like c-kit, platelet derived growth factor receptors among others, which as mentioned above play important roles in both folliculogenesis (7) and spermatogenesis (16), however case reports from human patients receiving nilotinib showed successful healthy deliveries (17)

These conflicting results about nilotinib effects on fertility necessitates further work to stratify risk, and to our knowledge such studies are still very limited in both pre-clinical and clinical settings

in correlation with these studies, our current work which study the effects of Nilotinib on both the endocrine profile and testicles histology of mice receiving two different doses of nilotinib 80mg/kg/day and 120mg/kg/day for 3 months duration in comparison with control group showed significant reduction of serum testosterone and FSH concentrations in the blood samples taken at the end of experiment from both treated groups in comparison with the control group with no significant difference regarding LH levels.

the histopathological assessment of testicular sections in both groups showed variable changes ranging from very mild subtle changes in the form of slight increases in interstitial tissue, vacuolation and separation of germinal epithelium to more severe effects in only single case out of 7 at 80mg/kg/day dose with reduced spermatogenesis in several tubules leaving focally only sertoli cells, however in the third group with higher dose more obvious changes appear in most of the group cases still with non-uniformity with 3 cases affected mildly with no significant effect on spermatogenesis activity and 2 cases more obvious changes seen including atrophy of several scattered seminiferous tubules while in 2 further cases more significant changes noted with multifocal atrophy and degeneration of seminiferous tubules alongside other frequent changes like increased interstitial spaces, vacuolation and separation of germinal epithelium

To the contrary of our results a study from Turkey(18,19), found no effects on spermatogenesis in their experimental mice but they used lower dose than we used at 20mg/kg/day and for 2 months duration instead of 3 months in our study, however another study utilizing Imatinib effects of spermatogenesis in Wistar Rats found a profound dose dependent effects on spermatogenesis;(11) such conflicting data regarding gonadotoxic effects of TKIs on spermatogenesis in animal models should of course require further investigation in humans to reach final conclusion about their possible effects on patients future fertility

## 5. CONCLUSION:

Nilotinib administration to albino mice showed significant reduction in serum testosterone and FSH levels with no significant effects on LH concentration in addition to variable dose dependent pathological changes in testicular histology which necessitates further work on both animal models and humans to stratify risk

## REFERENCES

- [1] Weisberg E, Manley PW, Breitenstein W, Brügger J, Cowan-Jacob SW, Ray A, et al. Characterization of AMN107, a selective inhibitor of native and mutant Bcr-Abl. *Cancer Cell*. 2005 Feb;7(2):129–41.
- [2] 2. National Center for Biotechnology Information. COMPOUND SUMMARY Nilotinib [Internet]. 2020 [cited 2020 Aug 28]. Available from: <https://pubchem.ncbi.nlm.nih.gov/compound/Nilotinib>
- [3] 3. Ohta H, Yomogida K, Dohmae K, Nishimune Y. Regulation of proliferation and differentiation in spermatogonial stem cells: the role of c-kit and its ligand SCF. *Development*. 2000 May;127(10):2125–31.
- [4] 4. Yoshinaga K, Nishikawa S, Ogawa M, Hayashi S, Kunisada T, Fujimoto T, et al. Role of c-kit in mouse spermatogenesis: identification of spermatogonia as a specific site of c-kit expression and function. *Development*. 1991 Oct;113(2):689–99.

- [5] Gnessi L, Basciani S, Mariani S, Arizzi M, Spera G, Wang C, et al. Leydig cell loss and spermatogenic arrest in platelet-derived growth factor (PDGF)-A-deficient mice. *J Cell Biol.* 2000 May;149(5):1019–26.
- [6] Basciani S, De Luca G, Dolci S, Brama M, Arizzi M, Mariani S, et al. Platelet-derived growth factor receptor beta-subtype regulates proliferation and migration of gonocytes. *Endocrinology.* 2008 Dec;149(12):6226–35.
- [7] Nilsson EE, Detzel C, Skinner MK. Platelet-derived growth factor modulates the primordial to primary follicle transition. *Reproduction.* 2006 Jun;131(6):1007–15.
- [8] Hensley ML, Ford JM. Imatinib treatment: specific issues related to safety, fertility, and pregnancy. *Semin Hematol.* 2003 Apr;40(2 Suppl 2):21–5.
- [9] Ramstein JJ, Tsai KK, Smith JF. Tyrosine Kinase Inhibitors and Male Reproductive Health. *Clin Pharmacol Ther.* 2017 Nov;102(5):754–6.
- [10] Prasad AM, Ramnarayan K, Nalini K, Bairy KL. Effect of imatinib on the biochemical parameters of the reproductive function in male Swiss albino mice. *Indian J Pharmacol.* 2011 Jul;43(4):389–92.
- [11] Yaghmaei P, Parivar K, Gharibi A, Sc M, Nabiuni M. The Biological Effects of Imatinib on Male Fertility of Wistar Rats. *Int J Fertil Steril.* 2009;3.
- [12] Yassin MA, Soliman AT, Elawa AS, El-Ayoubi HR, Desanctis V. Effects of Tyrosine Kinase Inhibitors On Spermatogenesis and Pituitary Gonadal Axis in Males with Chronic Myeloid Leukemia. *Blood [Internet].* 2012 Nov 16;120(21):1688. Available from: <https://doi.org/10.1182/blood.V120.21.1688.1688>
- [13] Nurmio M, Toppari J, Zaman F, Andersson A-M, Paranko J, Söder O, et al. Inhibition of tyrosine kinases PDGFR and C-Kit by imatinib mesylate interferes with postnatal testicular development in the rat. *Int J Androl.* 2007 Aug;30(4):366–76; discussion 376.
- [14] [https://www.novartis.us/sites/www.novartis.us/files/gleevec\\_tabs.pdf](https://www.novartis.us/sites/www.novartis.us/files/gleevec_tabs.pdf) [Internet]. [cited 2020 Aug 7]. Available from: [https://www.novartis.us/sites/www.novartis.us/files/gleevec\\_tabs.pdf](https://www.novartis.us/sites/www.novartis.us/files/gleevec_tabs.pdf)
- [15] Schultheis B, Nijmeijer BA, Yin H, Gosden RG, Melo J V. Imatinib mesylate at therapeutic doses has no impact on folliculogenesis or spermatogenesis in a leukaemic mouse model. *Leuk Res [Internet].* 2012;36(3):271–4. Available from: <http://www.sciencedirect.com/science/article/pii/S0145212611004681>
- [16] Mauduit C, Hamamah S, Benahmed M. Stem cell factor/c-kit system in spermatogenesis. *Hum Reprod Update.* 1999;5(5):535–45.
- [17] Conchon M, Sanabani SS, Bendit I, Santos FM, Serpa M, Dorliac-Llacer PE. Two successful pregnancies in a woman with chronic myeloid leukemia exposed to nilotinib during the first trimester of her second pregnancy: case study. *J Hematol Oncol.* 2009 Oct;2:42.
- [18] . Fadhel, A. A., & Yousif, A. K. (2019). Correlation of Glycated Hemoglobin ( Hba1c ) and Serum Uric Acid in Type-2 Diabetic Patients. *Indian Journal of Public Health Research & Development, 10(5).* <https://doi.org/10.5958/0976-5506.2019.01167.7>.
- [19] Cengiz Seval G, Özkavukçu S, Seval M, Aylı M. Gonadotoxic Effects of Nilotinib in Chronic Myeloid Leukemia Treatment Dose in a Mouse Model. *Turkish J Haematol Off J Turkish Soc Haematol.* 2017 Jun;34(2):137–42.