

Neurocysticercosis In A 10 Year Old Male: Case Report

AUTHORS

1) Dr. Anjali Kher

*Prof and HOD Dept. of Pediatrics
DattaMeghe Medical College, ShalinitaiMeghe Hospital and
Research Centre Nagpur-441110*

2) Dr. Swarnika barde

*Junior Resident, Dept of Pediatrics
Jawaharlal Nehru Medical College, Datta Meghe Institute of Medical Sciences
(DMIMS) Sawangi (Meghe) Wardha -442001*

3) Dr. Rohini Gulhane

*Assistant Professor Dept. of Pediatrics
DattaMeghe Medical College, ShalinitaiMeghe Hospital and Research Centre, Hingana,
Nagpur-441110*

Corresponding Author

Dr. Swarnika barde

Junior Resident, Dept of Pediatrics

Phone no.7350466114, E-mail Id:swarnikabarde@gmail.com

ABSTRACT

NEUROCYSTICERCOSIS: *Taenia solium*, also known as the pork tapeworm, causes 2 different infections in children. Infection with cystic form is termed cysticercosis, and involvement of central nervous system (CNS) is termed neurocysticercosis. We report a case of 10 year old male child with abnormal limb movement with upward rolling of eyes. History of repeated consumption of noodles from roadside food eateries. MRI BRAIN s/o- well defined rounded cystic lesion containing tiny scolex in it as well adjacent another rounded lesion showing hypo intense rim on T2W seen in left parietal region with mild perilesional edema seen in left temporo-parietal region s/o- granulomatous lesion. Patient was admitted for monitoring. No further complications were noted.

CONCLUSION Children can acquire tapeworm by ingestion of undercooked pork containing the Larval cyst. In the intestines the cyst converts into the tapeworm form. Children are also susceptible to infection by the eggs shed by tapeworm carriers.

KEYWORDS: Neurocysticercosis, *Teniasolium*, Pork tapeworm, Central Nervous System, Scolex.

INTRODUCTION

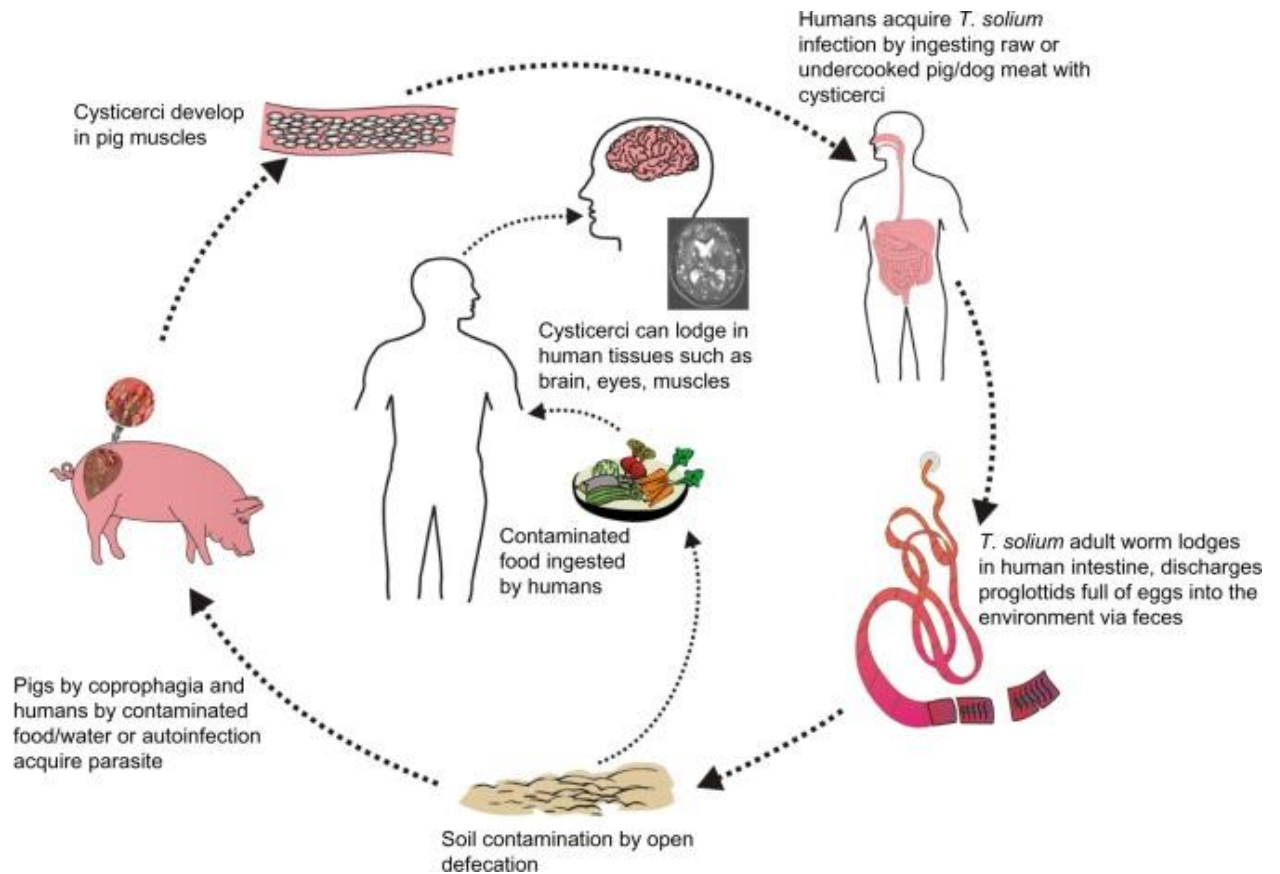
Neurocysticercosis (NCC) is an acquired nervous system infection caused by a *Taenia solium* encysted larvae. It is the most severe helminth infection of the nervous system in humans, a significant cause of tropical epilepsy and the most frequent cause of focal seizures in children in North Indian⁽¹⁾. The World Health Organization has described solium teniasis-cysticercosis as parasitic 'Neglected Tropical Diseases' endemic in Southeast Asia⁽¹⁾. While primarily a disease of the developing world, due to the immigrant population from endemic areas and growing international travel it is also seen in many developed countries⁽²⁾. NCC has pleomorphic manifestations in children depending on the location, number and viability of the cysts, and the

response of the host and care remain poorly understood and present challenges to clinical practice⁽²⁾. NCC is endemic, particularly in Latin America, the Indian subcontinent, the Southeast Asian region and sub-Saharan Africa⁽³⁾. Increasing globalization and travel has increased the incidence of NCC in many non-endemic countries like the United States, UK and Australia⁽⁴⁾. NCC is causing more than 5 million cases of preventable epilepsy worldwide among the symptomatic population⁽⁵⁾. NCC should be suspected clinically in any normally developing child with sudden-onset seizures, headache, vomiting, or focal motor deficits where there is no other underlying neurological disorder⁽⁶⁾. In a recent systematic analysis, the pooled estimate of the proportion of NCCs among people with epilepsy was as high as 29 percent in Latin America, Sub-Saharan Africa and Southeast Asia⁽⁷⁾. A meta-analysis of the relationship between cysticercosis and epilepsy in Africa found a substantial overall association with a specific odds ratio (OR) of 3.4 among patients with active epilepsy in North India, 25 per cent of cases tested positive for antibodies to *T. solium*⁽⁸⁾. In rural Northwest India the point prevalence of 4.5 per 1,000 population was noted. NCC accounted for > 50 per cent of cases in hospital-based series from India among children with partial seizures⁽⁹⁾. In Indian subcontinent, the commonest CT finding is a single, small (<20mm), low density lesion with ring or disc enhancement termed as a Single Enhancing Computed Tomographic (SSECTL) representing a degenerating cyst with associated mild to moderate perilesional edema and bright, hyperdense, eccentric scolex pathognomonic for NCC⁽¹⁰⁾.

CASE REPORT

A 10 years old male child brought to casualty by parents with complaint of abnormal limb movements with rolling of eyes with one episode of vomiting. Patient was afebrile with pulse rate of 90/minute with regular rhythm, blood pressure of 140/80 mm hg and oxygen saturation of 100 % on O₂ with head circumference of 51 cm, no evidence of pallor, icterus and cyanosis. Central nervous system examination suggestive of Eye response-4, Motor response-6, Verbal response-4 with no signs of meningitis, abnormal movements, hypotonia and exaggerated DTR. Cardiovascular system examination indicative of normal heart sound with no added murmur. Per abdomen examination indicative of soft non tender with no organomegaly. Respiratory system examination indicative of equal bilateral air entry. Routine investigation showed HB-12.5 gm%, WBC: 8300, Platelet count: 3.52 Lacs, Sr.calcium:9.59 mg%, Sr.potassium:4.4 meq/l, Sr.sodium:135 meq/l. Patient was started on Tab.Junior lanzol, Tab.Albendazole, Tab.Prednisolone, Tab.Leviteracetam. No evidence of similar episode, was hemodynamically stable, was accepting oral diet, hence was discharged with Tab.Junior Lanzol for three weeks, Tab.Albendazole for 1 month, syrup Leviteracetam continues till prescribe to discontinue and tab prednisolone in tapering dose for 15 days.

DISCUSSION



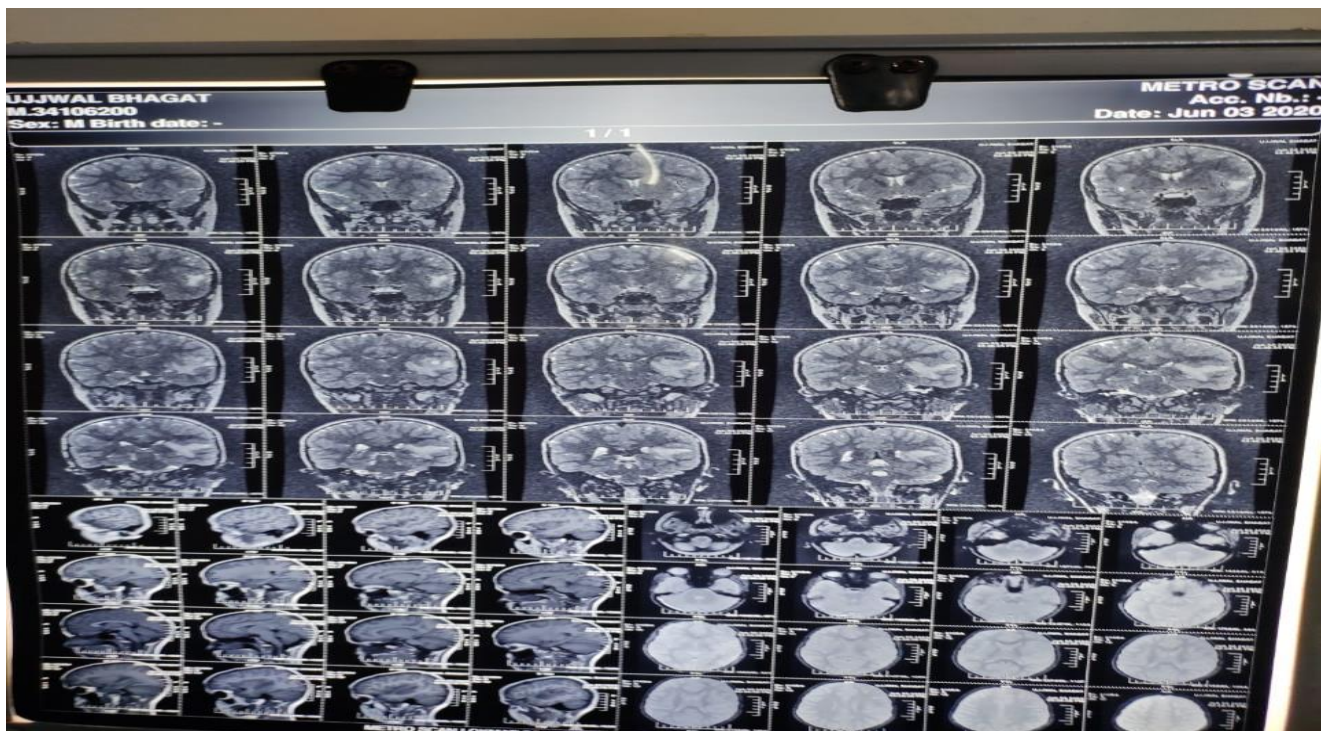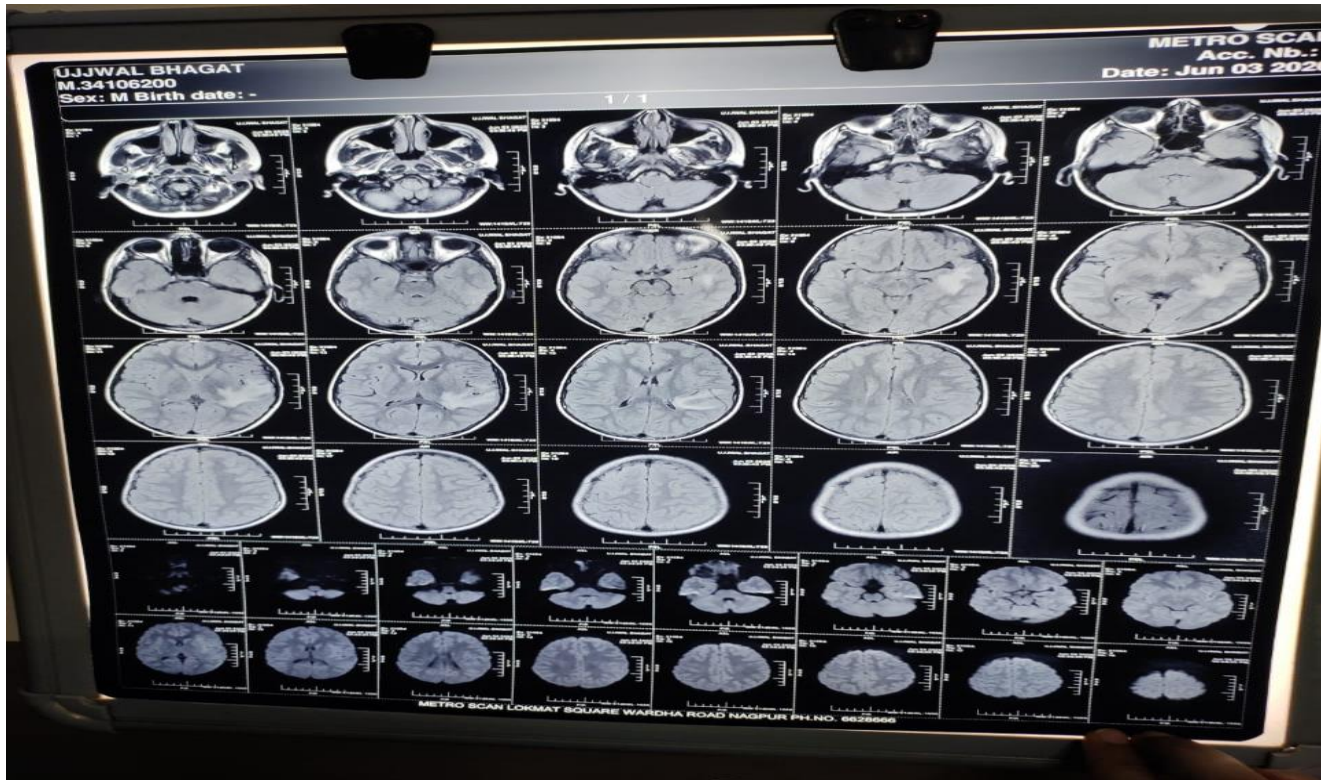
CLASSICAL PRESENTATION-

IDEAL TREATMENT- The initial management focuses on symptomatic treatment for seizures and or / hydrocephalus. Seizures can be controlled using standard antiepilepsy drugs which are tapered and stopped.

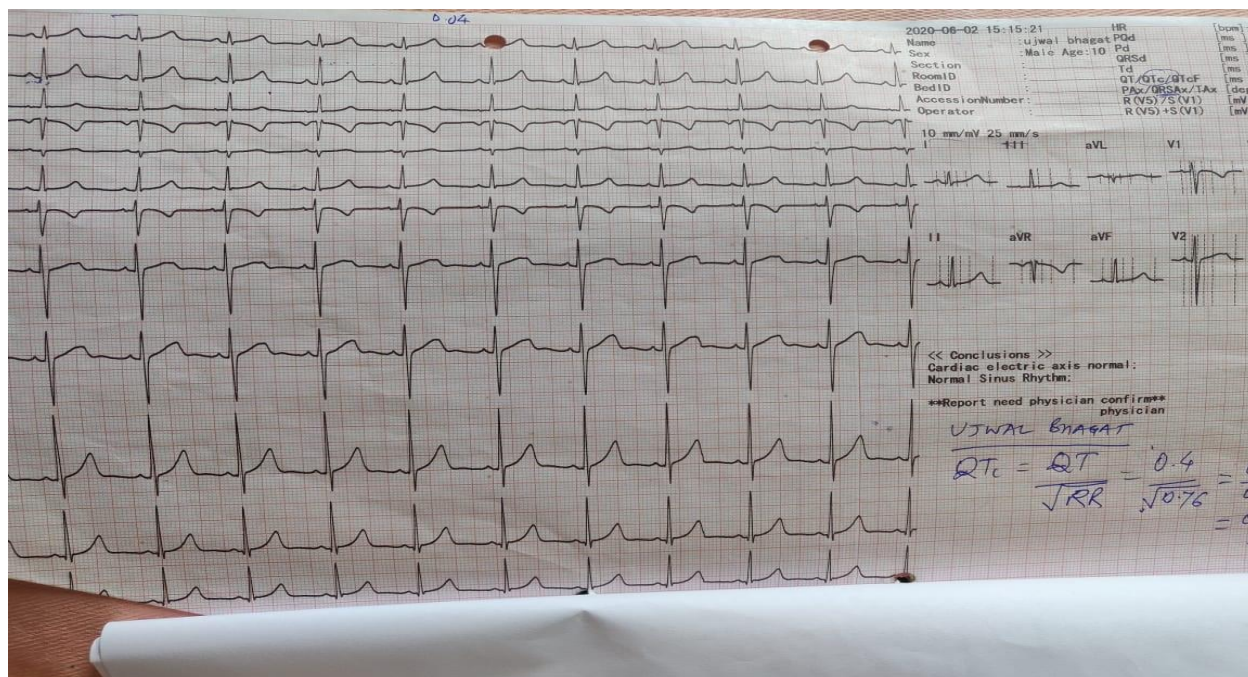
ROLE OF CYSTICIDAL DRUGS- Efficacy of antihelminthic drug in live, vesicular, and active parenchymal cysticercosis has been established, Albendazole (15mg/kg/day), taken along with fatty meals to improve absorption for 4 weeks administered within 3 months of onset of seizures was associated with a significantly increased and faster disappearance of lesions after 1 month. Praziquantel (50-100 mg/kg) for 28 days can be used with albendazole or as an alternative to it. Side effects of praziquantel include abdominal pain, dizziness, headache, and allergic reactions in rare cases. Cimetidine can be used in conjunction with praziquantel to blunt the first pass metabolism. Patients should be medicated with prednisone {1-2mg/kg/day} or oral dexamethasone (0.15 mg/kg/day) beginning before the first dose of antiparasitic drugs and continuing for at least 2 weeks.

CHOICE OF EPILEPTIC DRUG- It is recommended to initiate monotherapy with first-line drug and monitor for side effects as treating any case of seizures with an organic focus.

MRI FINDINGS OF PATIENTS:



ECG FINDINGS OF PATIENT:



Few of the related evidences are available from GBD study⁽¹¹⁻¹³⁾. Other related studies are available⁽¹⁴⁻¹⁶⁾. Similar Rare cases were reported by Goyal et al.⁽¹⁷⁾, Jain et. al.⁽¹⁸⁾, Iratwaret. al⁽¹⁹⁾. Kuntal et al reported on clinical profile and predictor of adverse outcome in children with acute encephalitis syndrome⁽²⁰⁻²²⁾.

CONCLUSION

Children can acquire tapeworm by ingestion of undercooked pork containing the Larval cyst. In the intestines the cyst converts into the tapeworm form. Children are also susceptible to infection by the eggs shed by tapeworm carriers.

REFERENCES

1. EpilepsyCoTDotILA Relationship between epilepsy and tropical diseases. *Epilepsia*. 1994;35:89–93. [PubMed] [Google Scholar]
2. Singhi P, Ray M, Singhi S, Khandelwal N. Clinical spectrum of 500 children with neurocysticercosis and response to albendazole therapy. *J Child Neurol*. 2000;15:207–213. [PubMed] [Google Scholar]
3. WHO . Accelerating Work to Overcome the Global Impact of Neglected Tropical Diseases A roadmap for Impementation. Geneva: World Health Organization; 2012. [Google Scholar].
4. Del Brutto OH, Garcia HH. Neurocysticercosis in nonendemic countries: time for a reappraisal. *Neuroepidemiology*. 2012;39:145–146. [PubMed] [Google Scholar].
5. Celikhisar, H. and Ilkhan, G.D. “ Determining The Etiological Factors in Pleural Fluid by Crp, Albumin And Procalcitonin Levels. *Journal of Medical Research and Health Sciences*. 3, 2 (Feb. 2020), 880-885. DOI:<https://doi.org/10.15520/jmrhs.v3i2.157>.
6. Serpa JA, White AC., Jr Neurocysticercosis in the United States. *Pathog Glob Health*. 2012;106:256–260. [PMC free article] [PubMed] [Google Scholar].
7. Cherian A, Syam UK, Sreevidya D, et al. Low seroprevalence of systemic cysticercosis among patients with epilepsy in Kerala – South India. *J Infect Public Health*. 2014;7:271–276. [PubMed] [Google Scholar]
8. Ratnam S, Khanna PN, Bandyopadhyay AK. Incidence of taeniasis in man. *Indian J Public Health*. 1983;27:70–74. [PubMed] [Google Scholar]
9. Singh G, Bawa J, Chinna D, et al. Association between epilepsy and cysticercosis and toxocariasis: a population-based case-control study in a slum in India. *Epilepsia*. 2012;53:2203–2208. [PubMed] [Google Scholar]

10. Saber, T., Hawsawi, N.M., alharthi, A. hassen, algethami, M. hamad, alnefaie, R.A., asiri, A. abdul R. and Saber, T. “ Prevalence and Antibiotic Sensitivity Pattern of Asymptomatic Bacteriuria among Female Students and Staff of College of Applied Medical Sciences, Taif University. *Journal of Medical Research and Health Sciences*. 3, 1 (Jan. 2020), 862-867. DOI:<https://doi.org/10.15520/jmrhs.v3i1.151>.
11. Rafat Khan, AshaAgarwal (2018) Ameliorative Effect of Vitamin C And E Against The Toxicity of Nitrogen Dioxide Gas on Clotting Factors in Albino Rats *International Journal Of Scientific Research And Education*.06,09 (Sep-18) 8023-28
12. Ni LuhPutriSantje, S.L.Sangar (2018) The Model Development of Makeup Learning For Early Mentally Disabled Children in The Extraordinary Kindergarten North Sulawesi *International Journal Of Scientific Research And Education*.06,07 (July-18) 7980-85
13. Raina SK, Razdan S, Pandita KK, Sharma R, Gupta VP. Active epilepsy as indicator of neurocysticercosis in rural northwest India. *Epilepsy Res Treat*. 2012;2012:802747. [PMC free article] [PubMed] [Google Scholar]
14. Singhi P, Singhi S. Neurocysticercosis in children. *J Child Neurol*. 2004;19:482–492. [PubMed] [Google Scholar]
15. Wang, Haidong, Kaja M Abbas, MitraAbbasifard, Mohsen Abbasi-Kangevari, HedayatAbbastabar, FoadAbd-Allah, Ahmed Abdelalim, et al. “Global Age-Sex-Specific Fertility, Mortality, Healthy Life Expectancy (HALE), and Population Estimates in 204 Countries and Territories, 1950–2019: A Comprehensive Demographic Analysis for the Global Burden of Disease Study 2019.” *The Lancet* 396, no. 10258 (October 2020): 1160–1203.[https://doi.org/10.1016/S0140-6736\(20\)30977-6](https://doi.org/10.1016/S0140-6736(20)30977-6).
16. Lozano R, Fullman N, Mumford JE, Knight M, Barthelemy CM, Abbafati C, et al. Measuring universal health coverage based on an index of effective coverage of health services in 204 countries and territories, 1990–2019: a systematic analysis for the Global Burden of Disease Study 2019. *Lancet* 2020.
17. Kinyoki DK, Ross JM, Lazzar-Atwood A, Munro SB, Schaeffer LE, Abbasalizad-Farhangi M, et al. Mapping local patterns of childhood overweight and wasting in low- and middle-income countries between 2000 and 2017. *Nat Med* 2020;26(5):750-759.
18. Khatib M, Sinha A, Gaidhane A, Simkhada P, Behere P, Saxena D, et al. A systematic review on effect of electronic media among children and adolescents on substance abuse. *Indian Journal of Community Medicine*. 2018;43(5):S66–72. https://doi.org/10.4103/ijcm.IJCM_116_18.
19. Puri S, Fernandez S, Puranik A, Anand D, Gaidhane A, Quazi Syed Z, et al. Policy content and stakeholder network analysis for infant and young child feeding in India. *BMC Public Health* [Internet]. 2017;17. <https://doi.org/10.1186/s12889-017-4339-z>.
20. Uddin S, Mahmood H, Senarath U, Zahiruddin Q, Karn S, Rasheed S, et al. Analysis of stakeholders networks of infant and young child nutrition programmes in Sri Lanka, India, Nepal, Bangladesh and Pakistan. *BMC Public Health* [Internet]. 2017;17. <https://doi.org/10.1186/s12889-017-4337-1>.
21. Goyal, C., W.M. Naqvi, and A. Sahu. “An Atypical Case of Febrile Infection-Related Epilepsy Syndrome Following Acute Encephalitis: Impact of Physiotherapy in Regaining Locomotor Abilities in a Patient with Neuroregression.” *Pan African Medical Journal* 36 (2020): 1–6. <https://doi.org/10.11604/pamj.2020.36.101.23855>.
22. Jain, J., S. Banait, I. Tiewsoh, and M. Choudhari. “Kikuchi’s Disease (Histiocytic Necrotizing Lymphadenitis): A Rare Presentation with Acute Kidney Injury, Peripheral Neuropathy, and Aseptic Meningitis with Cutaneous Involvement.” *Indian Journal of Pathology and Microbiology* 61, no. 1 (2018): 113–15. https://doi.org/10.4103/IJPM.IJPM_256_17.
23. Iratwar, S., A. Patil, C. Rathod, P. Korde, V. Mundhe, and H. Deshpande. “Ventriculosubgaleal Shunt in Children with Hydrocephalus.” *Journal of Datta Meghe Institute of Medical Sciences University* 14, no. 3 (2019): 115–18. https://doi.org/10.4103/jdmimsu.jdmimsu_169_19.
24. Kuntal, M., and K. Swarnkar. “Clinical Profile and Predictor of Adverse Outcome in Children with Acute Encephalitis Syndrome: A Cross-Sectional Study.” *Journal of Krishna Institute of Medical Sciences University* 9, no. 1 (2020): 18–26.
25. Ray, S., Jha, A., Afreen Islam, A., &Sengupta, M. (2020). Study of prognostic and diagnostic significance of P53 and PTEN mutation in proliferative lesions of endometrium. *Journal of*

Current Medical Research
<https://doi.org/10.15520/jcmro.v3i08.321>

and Opinion, 3(08), 563-569.