

MANAGEMENT OF LE FORT II FRACTURE FRACTURE – A CASE REPORT

DR.VIJAY EBENEZER

TITLE PAGE:

Type of manuscript – case report

Title — Reconstruction Of Orbital Floor Fracture- A case report

Running title – Reconstruction Of Orbital Floor fracture

Correspondance to - Dr. Vijay Ebenezer

Professor and Head of Department

Names of the author(s):

Dr. Vijay Ebenezer¹, Dr. Shanmuga priyan²,

Professor and Head of the department , Department of oral and maxillofacial surgery , Sree Balaji dental college and hospital , BHARATH UNIVERSITY, Chennai-600100 , Tamilnadu , India.

Reader in the department of oral and maxillofacial surgery, Sree balaji dental college and hospital, pallikaranai, chennai-100.

Name of the Department – Oral and Maxillofacial surgery, Sree balaji dental college and hospital, Pallikaranai, Chennai – 100, Ph no : 9840136328

ABSTRACT:

Lefort classification is the historic classification which is widely used to classify mid facial fractures. The lefort classification was given by Rene Lefort ,who classified mid facial fracture into Lefort I , II and III. Lefort 2 fracture is referred as ‘ PYRAMIDAL or SUBZYGOMATIC FRACTURE .’ Lefort 2 is a floating maxilla which runs from the thin middle area of the nasal bones down either side , crossing the frontal processes of the maxilla into the medial wall of each orbit . Within the orbit , the fracture line runs across the lacrimal bone behind the lacrimal sac to cross the infra orbital margin medial to or through the infra orbital foramen . Extends downwards & backwards across the lateral wall of the antrum below the zygomaticomaxillary suture & divides the pterygoid laminae .Le fort fractures are blunt trauma facial fractures which involves specific pattern of facial bones injury. Pterygoid process of sphenoid bones is involved in all Le fort fractures. Lefort fractures are classified further depending upon the involvement of zygomatic, nasal and maxillary bones. Blunt facial traumas due to motor vehicle collision, assault, falls or sports injury are the most common causes. In our case, Le fort 2 fracture resulted from motor vehicle collision.

KEYWORDS: *lefort fracture , lefort 2, trauma , fracture, treatment, management, Computerized tomography, Facial bones, Open reduction*

1. INTRODUCTION:

Sport injuries account for a high percentage of facial injuries among young persons¹. The potential for serious damage exists in lefort 2 fracture .This case presents a LeFort II fracture that depended entirely on a motor vehicle collision- hit and fall from two wheeler. Midface fractures have universally been the most common pattern of injury, likely due to the central location and fragility of the midface². Anatomic complexity of this region, midface injuries constitute a wide range of fracture combinations, etiologies, and severity.

Immediate management of a patient with midfacial fractures in emergency department includes Maintenance of patent airway,temporary cessation of hemorrhage ,blood fluid replacement,antibiotic prophylaxis,tetanus prophylaxis ,monitoring vitals,assessment of neurologic status (Glasgow coma scale

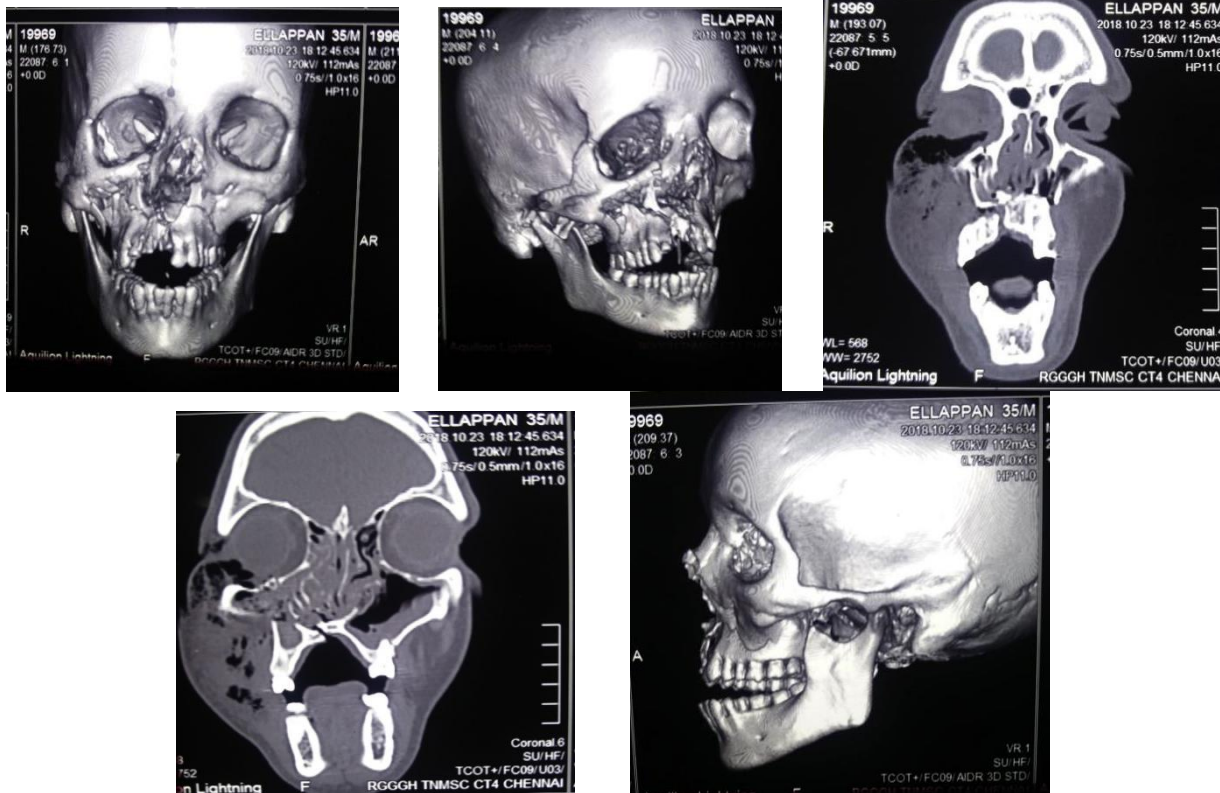
),Evaluation of cervical spine ,control of pain. Signs & symptoms of lefort 2 fracture include ballooning or moon face ,bilateral circumorbital edema & ecchymosis (black eye),bilateral subconjunctival hemorrhage confined to medial half of eye,bridge of nose depressed (flat face),impaction of the fragment against cranial base,if there is gross downward & backward displacement of fragment – elongation / lengthening of face will be seen,bilateral epistaxis ,difficulty in mastication & speech,loss of occlusion,airway obstruction ,surgical emphysema ,csf leak maybe present ,step deformity at the infraorbital margins maybe seen ,anaesthesia / parasthesis of cheek maybe noted,We report a case of lefort 2 fracture and open reduction Internal fixation was done.

2. CASE REPORT:

A 35 year old male patient reported to Sree Balaji Medical College and hospital Chennai . The patient had met with a road traffic accident a few days before reporting here . Following the accident , the patient was taken to another private hospital , for immediate care . The patient had no history of loss of consciousness following the accident.

After reporting to our institution, on general examination the patient was stable , conscious , well oriented and well built ,vitals were all found to be normal . On local examination- peri orbital ecchymosis and edema in relation to right eye ,subconjunctival hemorrhage in ight eye ,laceration below the lower lip measuring about 2*1 cm ,fractured teeth 12 , 11 , 21 and avulsed 22 was present. Routine blood investigations were carried out – CBC, BT, CT , HIV, HBsAg, RBS , RFT . Investigations such as chest x ray, ECG were taken . All the parameters were found to be normal.

CT facial bones with 3D reconstruction was taken. On examining the CT fracture line in the nasofrontal junction and extending laterally across the medial wall of orbit, orbital floor, infraorbital rim and through the zygomaticomaxillary suture line was seen and LeFort II fracture was diagnosed. The fracture was confirmed as it proceeds posteriorly through the nasal septum and pterygoid plates.



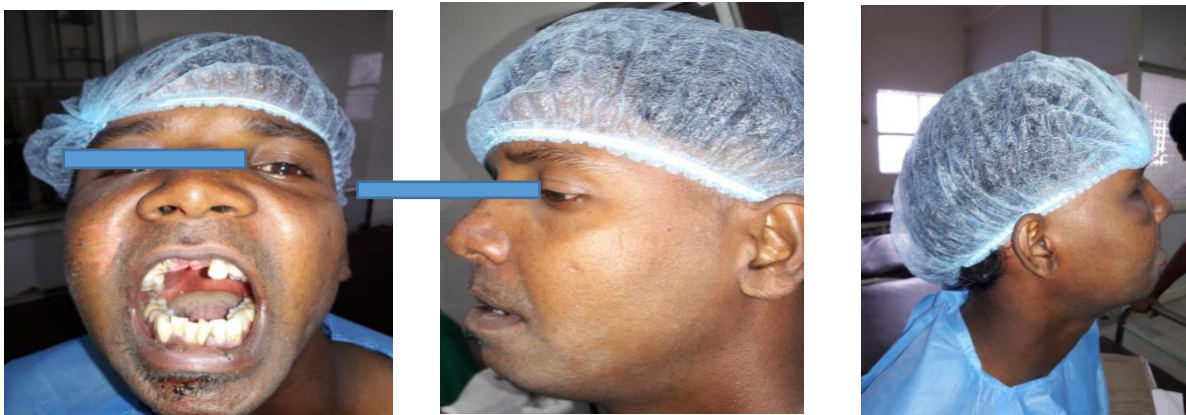
Neurosurgery and anaesthetic fitness was obtained to carry out the surgery. The patient was operated under general anaesthesia, using oro-tracheal intubation. skin preparation was done using betadine solution. Local anaesthesia was administered from 16- 26 region .Eyelets were placed in relation to 15-

16, 25 -26 , 35 -36 and 45 – 46 region Trans palatal wiring was done from 14 to 24 region . Intermaxillary fixation was done.

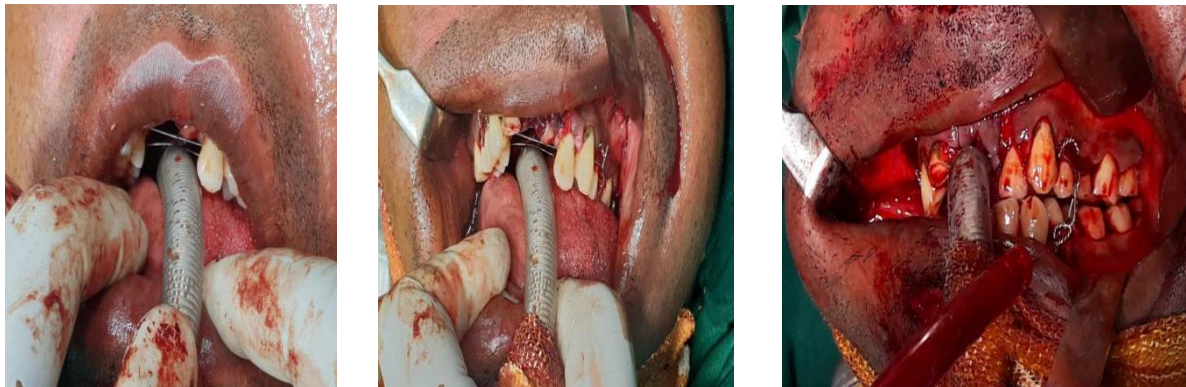Vestibular incision was placed in relation to 17-26 region .Mucoperiosteal flap was elevated and the fracture site was exposed. Rowe's disimpaction forceps was used to manipulate and reduce the fractured fragment .The fracture was stabilised .4 hole 1 shaped plates were placed in relation to right and left pyriform aperture region and the right and left zygomatic buttress region and stabilised with 2*6 mm screws.

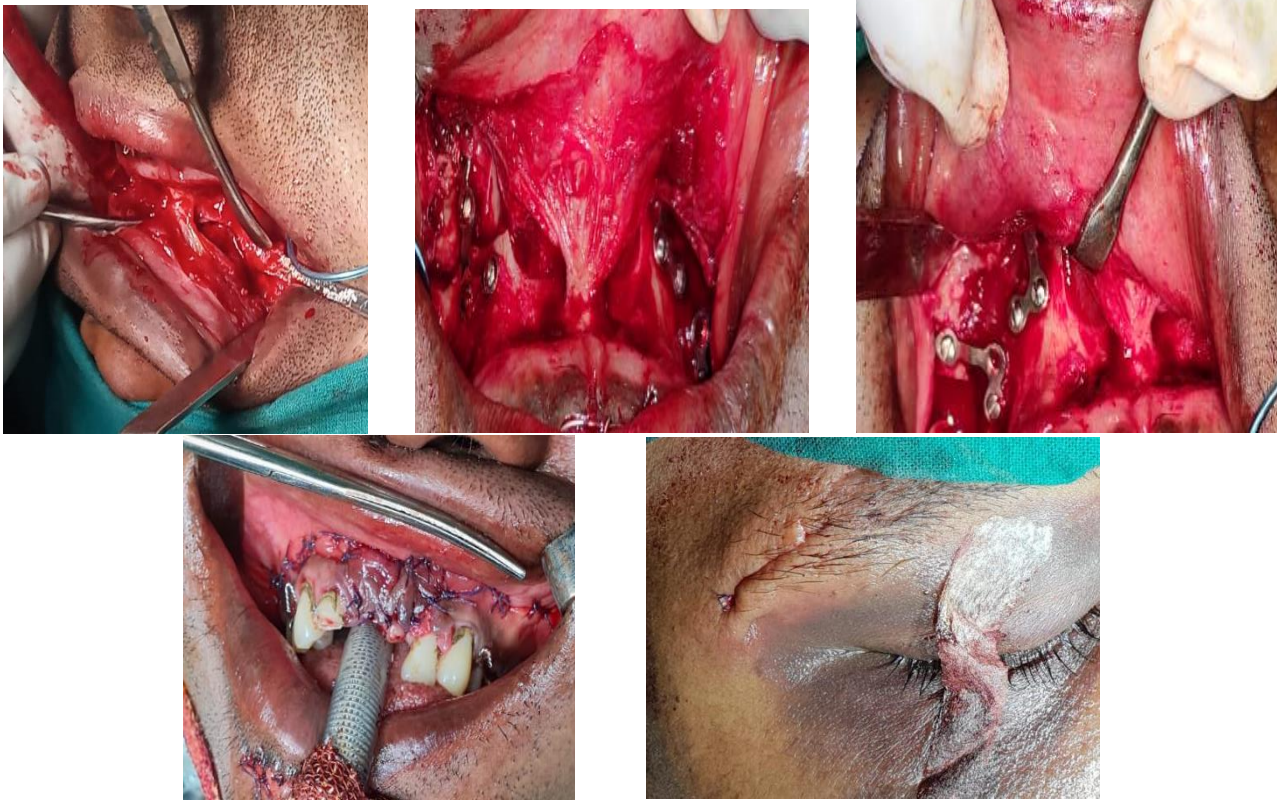Incision was placed in relation to right eyebrow region (lateral eyebrow approach). The right zygomatic arch was then elevated using the rowe's zygomatic elevator .Intermaxillary fixation was then released and occlusion was checked again. Suturing was then done with 4-0 vicryl intra orally and 5-0 ethilon for incision in relation to right eyebrow.

PREOPERATIVE



OPERATIVE





POST OPERATIVE



3. DISCUSSION:

Management of lefort ii fractures involves open reduction followed by internal fixation .The fractured fragment is reduced with a pair of rowe's disimpaction forceps .The fragment should be manipulated firmly away from the base of the skull until it is freely mobile³ .Fixation methods can be divided into two categories : internal fixation (immobilization within the tissues)and external fixation (extra oral immobilization)

Majority of fractures of central middle third can be adequately immobilized by some form of internal fixation . only the more complex and extensively comminuted fractures and those associated with multiple fractures of the mandible which require external support⁴. Surgeon Rene Le fort, explained mid facial fractures classification after studying facial crush injuries in cadavers. He experimented by applying blunt force at different angles on cadaver heads and read about the mid facial fractures⁵. He observed that all mid facial fractures are horizontal, pyramidal or transverse and coined them as Le fort I (horizontal), Le fort II (pyramidal) and Le fort III (transverse).

The common causes of Le fort fracture include road traffic accidents and fall. In Le fort I, fracture line runs horizontally across maxilla and also involves pterygoid process of sphenoid bone. In Le fort II the fracture line is pyramidal running from nasal bridge, lachrymal bones, orbital rims and floors extending up to maxilla. Le fort III fracture is separation of skull and facial bones, the fracture line runs posteriorly from the nasal

bridge towards zygomatic arch passing through medial and lateral orbital walls on both sides, associated with cerebrospinal fluid leak⁶.

Le fort fractures are associated with pterygoid fracture. Le fort II fracture is best recognized with 3D (3 dimensional) CT scan. The common symptoms are pain in affected area with malocclusion, tenderness with or without hematoma. Restriction of eye movements can be present depending upon the extent of injury. Facial X-ray, waters view can be done to visualise Dolan lines and elephants of Rogers. CT scan of face with 3D construction is the investigation of choice.

The three lines-orbital, zygomatic and maxillary lines on radiographs are called Dolan's lines⁷. The zygomatic and maxillary lines together resembles head of elephant called elephant's of Rogers. The aim of Le Fort II fracture management are control of infections, reduction and fixation of fractures segment and immobilization. Increased movement of segments after surgical management can hinder new bone formation and leads to infection⁸.

Reduction has to be done to restore the form, function and aesthetics. Proper occlusion has to be achieved. Open reduction and Internal fixation will be more difficult if it is delayed more than 10 days in mandible and 3 weeks in maxilla⁹. This can cause deformity. IMF Immobilization has to be done for 4 to 6 weeks for mandible and 3 to 4 weeks for maxilla to obtain good occlusion¹⁰.

Complications arising from lefort fracture reduction includes long face or flattening of the entire profile called the 'dish face deformity', anterior open bite upper arch rotation to one side, palatal defects, partial or complete obstruction of the nasolacrimal duct is most common complication of lefort ii fractures – 'dacryocystitis', double vision, oculomotor and abducent nerve damage, non union of fracture.

4. CONCLUSION:

Reduction of lefort 2 fracture has to be carried out in a step wise fashion. When the management is carried out in a step wise fashion, although complex, appropriate reduction of the fractures is possible. Occlusion remains the foundation of proper alignment. Post surgical complications cannot be avoided. Proper management of Le Fort II fracture can restore the function, mastication and occlusion. Maintaining Facial esthetics are the indicators of successful fracture management. Understanding the midface fracture patterns and early identification of associated injuries help us to improve the treatment of these complex patients.

5. REFERENCES:

- [1] Le fort R. Étude expérimentale sur les fractures de la machoire supérieure. *Revue chir de Paris* 1901;23:208–27, 360–79, 479–507.
- [2] 2. Kühnel TS, Reichert TE. Trauma of the midface. *GMS Curr Top Otorhinolaryngol Head Neck Surg* 2015 Dec 22;14:Doc06. [CrossRef] [PubMed]
- [3] .
- [4] 3. Akoglu E, Onur O, Denizbasi A, Kosargelir M, Akoglu H, Ibrahim A. Heading the ball: A case of a Le fort II fracture in a football match. *BMJ Case Rep* 2011 Mar 15;2011. [CrossRef] [PubMed]
- [5] 4. Arslan ED, Solakoglu AG, Komut E, et al. Assessment of maxillofacial trauma in emergency department. *World J Emerg Surg* 2014 Jan 31;9(1):13. [CrossRef] [PubMed]
- [6] Kretlow JD, McKnight AJ, Izaddoost SA. Facial soft tissue trauma. *Semin Plast Surg* 2010 Nov;24(4):348–56. [CrossRef] [PubMed]
- [7] Motamedi MH. An assessment of maxillofacial fractures: A 5-year study of 237 patients. *J Oral Maxillofac Surg* 2003 Jan;61(1):61–4. [PubMed]

- [8] Gonzalez E, Pedemonte C, Vargas I, et al. Facial fractures in a reference center for level I traumas: Descriptive study. *Rev Esp Cir Oral Maxilofac* 2015;37(2):65–70. [CrossRef]
- [9] Bell RB, Dierks EJ, Homer L, Potter BE. Management of cerebrospinal fluid leak associated with craniomaxillofacial trauma. *J Oral Maxillofac Surg* 2004 Jun;62 (6):676–84. [CrossRef] [Pubmed]
- [10] Rhea JT, Novelline RA. How to simplify the CT diagnosis of Le fort fractures. *AJR Am J Roentgenol* 2005 May;184(5):1700–5. [CrossRef] [Pubmed]
- [11] Unger JD, Unger GF. Fractures of the pterygoid processes accompanying severe facial bone injury. *Radiology* 1971 Feb;98(2):311–6. [CrossRef] [Pubmed]