

## Use of Retrograde Intramedullary Locking Nail in Ankle Arthrodesis for in Diabetic Patients: An updated Overview

Abubaker M R Zanbouzi <sup>1</sup>, Omar Abd Elwahab Kelany <sup>2</sup>, Walid Mohmmmed Nafeh<sup>3</sup>, and Mohammed Khalid Saleh <sup>4</sup>

<sup>1</sup> M.B.B.CH, Faculty of Medicine, Tripoli of University, Libya

<sup>2</sup> Professor of Orthopedic Surgery, Faculty of Medicine, Zagazig University.

<sup>3</sup> Assistant Professor of Orthopedic Surgery, Faculty of Medicine, Zagazig University.

<sup>4</sup> Lecturer of Orthopedic Surgery, Faculty of Medicine, Zagazig University.

**Corresponding author: Abubaker M R Zanbouzi**

**Email:** Abubaker.m.r.zanbouzi@gmail.com

### Abstract

**Background:** Ankle arthrodesis for diabetic complications, such as osteomyelitis and Charcot neuroarthropathy (CN), constitute an entirely separate group that calls for different surgical approaches for successful outcomes. Diabetes mellitus is currently the most common cause of neuroarthropathy. Abnormal nociception and proprioception lead to progressive destruction of the joint. Ankle arthrodesis and ankle arthroplasty are the two common operative treatments used in end stage ankle arthritis (ESAA). Recent clinical evidence suggests that ankle arthroplasty leads to superior functional outcomes over ankle arthrodesis. Ankle arthrodesis is indicated for patients with ESAA that failed a minimum of 3 month of conservative treatment. Both internal and external fixation may be used in ankle arthrodesis. Retrograde intramedullary arthrodesis is typically reserved for arthrodesis of both the ankle and subtalar joints. Two standardized methods of ankle arthrodesis for ESAA is described here: Open and arthroscopic.

**Keywords:** Retrograde Intramedullary Locking Nail, Ankle Arthrodesis.

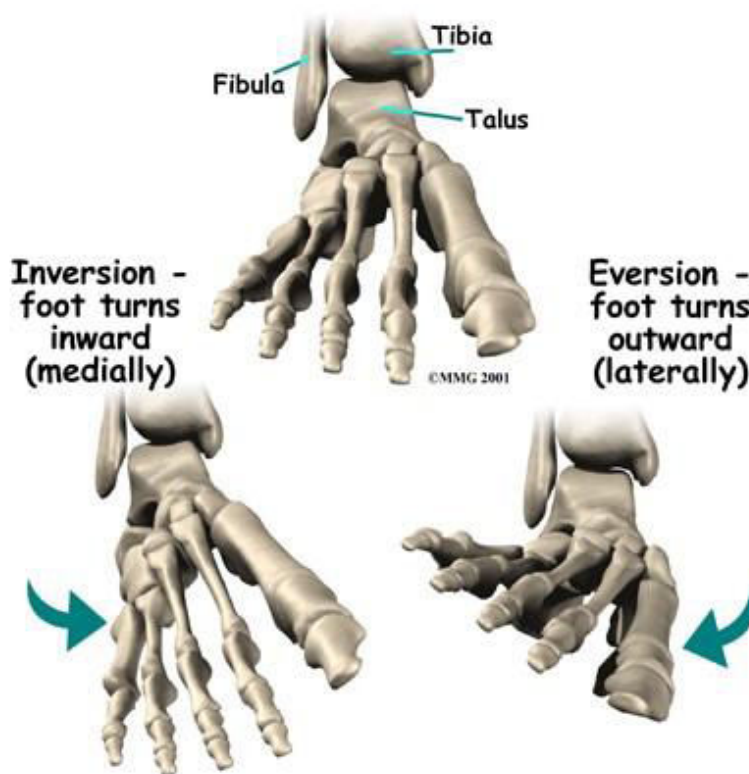
### Anatomy of ankle Joint:

The ankle joint is a hinged synovial joint that is formed by the articulation of the talus, tibia, and fibulabones. Together, the three borders (listed below) form the ankle mortise.

1. The articular facet of the lateral malleolus (bony prominence on the lower fibula) forms the lateral border of the ankle joint
2. The articular facet of the medial malleolus (bony prominence on the lower tibia) forms the medial border of the joint
3. The superior portion of the ankle joint forms from the inferior articular surface of the tibia and the superior margin of the talus.

The talus articulates inferiorly with the calcaneus and anteriorly with the navicular.

- The upper surface, called the trochlear surface, is somewhat cylindrical and allows for dorsiflexion and plantarflexion of the ankle.
- The talus is wider anteriorly and narrower posteriorly.
- It forms a wedge that fits between the medial and lateral malleoli making dorsiflexion the most stable position for the ankle. (1)



**Figure (1): Anatomy of ankle and foot (1)**

### Structure and Function

- The ankle joint is important during ambulation because it adapts to the surface on which one walks.
- The movements that occur at the ankle joint are plantarflexion, dorsiflexion, inversion, and eversion.
- The muscles of the leg divide into anterior, posterior, and lateral compartments (1).

### Articulating Surfaces

- Trochlea of Talus
- Malleolar Mortis formed by Tibia & Fibula
- Lateral & Medial Malleolus (1)

### Joint Capsule

The articular capsule surrounds the joints and is attached above to the borders of the articular surfaces of the tibia and malleoli and below to the talus around its upper articular surface. The joint capsule anteriorly is a broad, thin, fibrous layer, posteriorly the fibres are thin and run mainly transversely blending with the transverse ligament and laterally the capsule is thickened and attaches to the hollow on the medial surface of the lateral malleolus. The synovial membrane extends superiorly between Tibia & Fibula as far as the Interosseous Tibiofibular Ligament (2).

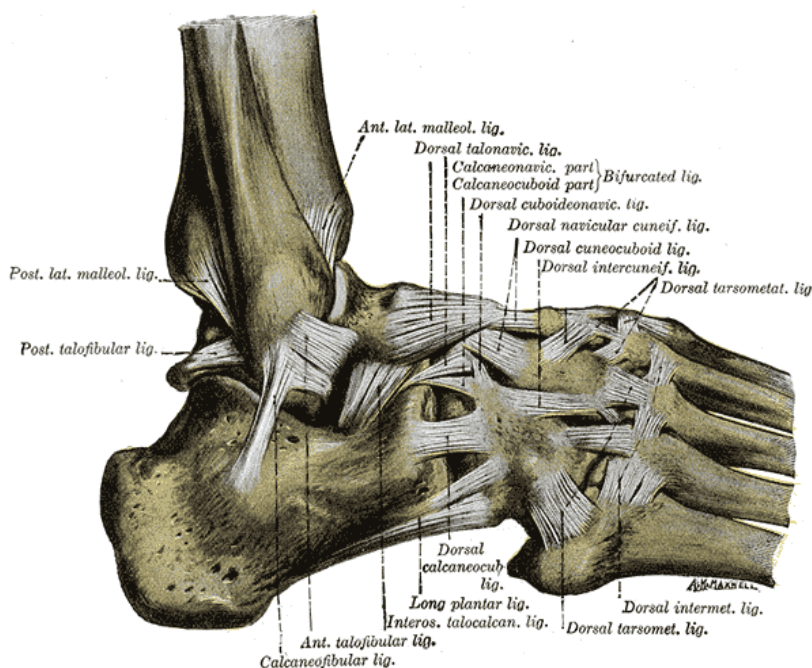
### Ligaments

#### The main stabilizing ligaments

Medially the deltoid ligament, consists of four ligaments that form a triangle connecting the tibia to the navicular, the calcaneus, and the talus. It stabilises the ankle joint during eversion of the foot and prevents subluxation of the ankle joint(2).

Laterally the ankle has stabilization from three separate ligaments, the anterior and posterior talofibular ligaments, and the calcaneofibular ligament. The anterior talofibular ligament connects the talus to the fibula, the weakest of the three lateral ligaments and thus the most frequently injured.

- The posterior talofibular ligament connects the talus to the fibula
- The calcaneofibular ligament connects the fibula to the calcaneus inferiorly.



**Figure (2):** Ankle ligaments (2)

## Muscles

The muscles of the leg divide into anterior, posterior, and lateral compartments.

1. The leg's posterior compartment of the leg divides into the superficial posterior compartment and the deep posterior compartment. The superficial posterior compartment consists of the gastrocnemius and the soleus muscles, which are the primary muscles involved in ankle plantarflexion. The deep compartment plays a role in ankle joint inversion.
2. The tibialis anterior muscle, found in the anterior compartment of the leg, is the primary muscle that facilitates dorsiflexion of the ankle joint.
3. The peroneus longus and peroneus brevis muscles, found in the lateral compartment of the leg, function to facilitate eversion of the ankle joint. (1)

## Classifications of the diabetic Charcot foot

The Charcot foot can be classified into:

- Clinical classification.
- Anatomical classifications.
- Based on natural history.

## Clinical classification.

In clinical practice, the Charcot foot can be classified into the acute and chronic stage. In the acute (also called active) stage, the foot is remarkably red, warm and swollen. This pathology usually

affects the midfoot. Pain is not a prominent feature and patients may report no pain or only some discomfort, which is usually much less in comparison to patients without neuropathy and similar degree of local inflammation. Using a portable infrared thermometer, the physician may document a 2-6°C temperature elevation in the affected vs. the contralateral foot. At this stage, there is no deformity, and the plain foot radiographs are most typically normal. The importance of early diagnosis to arrest the disease progress and avoid further bony destruction cannot be emphasized enough (3).

### **Anatomical classifications**

The most frequently used anatomical classification was proposed by Sanders and Frykberg. This describes five different patterns, depending on foot areas involved. In **Pattern I** (15%), the forefoot [metatarsophalangeal (MTP) and interphalangeal (IP) joints] is affected; in **Pattern II** (40%), tarso-metatarsal (TMT) joints are affected; in **Pattern III** (30%), the naviculocuneiform, talonavicular, and calcaneocuboid joints are involved; in **Pattern IV** (10%), the ankle and subtalar joints are affected; in **Pattern V** (5%), the calcaneum is affected. A simpler anatomical classification distinguishes between three types. These are: the forefoot type involving the IP and MTP joints, the midfoot type involving the TMT and tarsal joints, and the hindfoot variation, in which the ankle joint and calcaneum are involved (4).

Another classification in three types was reported. In type I, the forefoot is affected. In type II, the midfoot (TMT, naviculocuneiform, talonavicular, and calcaneocuboid joints) is affected. Type III involves the hindfoot causing severe instability and is classified into IIIa (involving the ankle joint), IIIb (involving the subtalar joint) and IIIc (resorption of talus and/or calcaneus with impaired weight-bearing) (4).

### **Classification based on natural history**

This classification into three stages is based on Eichenholtz's work (1966). It is a radiological classification describing the natural history of the Charcot foot from initiation through coalescence to consolidation and has been recently reviewed in more detail by the authors elsewhere.

**In stage I (development)**, there is erythema, foot edema and elevated temperature. Plain foot radiographs are commonly normal, but bony debris at joints, fragmentation of subchondral bone, joint subluxation and fracture dislocation of joints may soon ensue (4).

**In stage II (coalescence)**, signs of local inflammation gradually diminish, but radiological pathology becomes more evident. This includes absorption of debris with new bone formation, coalescence of larger fragments and sclerosis of bone ends. At this stage, affected joints may become more stable.

**In stage III (consolidation)**, signs of local inflammation are no longer discernible, and radiographs reveal remodelling of affected bones and joints. It is during this advanced stage that severe deformities may change foot architecture, predisposing to ulceration (4).

### **Ankle Arthrodesis**

Ankle arthrodesis and ankle arthroplasty are the two common operative treatments used in end stage ankle arthritis (ESAA). Recent clinical evidence suggests that ankle arthroplasty leads to

superior functional outcomes over ankle arthrodesis. However, ankle arthroplasty is associated with higher rates of postoperative complications and revision surgeries (5). Despite the increasing popularity of ankle arthroplasty, a large database has indicated that ankle arthrodesis still remains the most common surgical treatment for ESAA (6).

There are several operative techniques for ankle arthrodesis including open or arthroscopic approaches. Although successful clinical outcome can be achieved following both approaches, reported outcomes have varied and are conflicted. The differences in techniques, surgeon skill, patient selection and populations, and outcome measurements utilized all contribute to the variability in outcome after arthrodesis. Ankle arthrodesis should be performed judiciously in young patients, highly active patients, and patients with advanced foot and ankle deformity (5).

### **Indications and Goals of Arthrodesis**

Ankle arthrodesis is indicated for patients with ESAA that failed a minimum of 3 month of conservative treatment. The goal of ankle arthrodesis is to provide a pain-free plantigrade foot during weight bearing activities. Alignment following ankle arthrodesis must be slight valgus ( $0^{\circ}$ - $5^{\circ}$ ), neutral dorsiflexion, and slightly externally rotation. Equinus position of the ankle joint can accompany genu recurvatum and a varus position of hindfoot can develop painful callosities to the lateral forefoot, which may cause hindfoot pain. Additionally, the surgeon should attempt to minimize limb length discrepancies (less than 2.5 cm or 1.0 inch). Limb length discrepancies can result in a symptomatic malalignment with altered gait pattern (7).

Arthroscopic ankle arthrodesis is typically reserved for patients with little to no joint deformity (less than  $15^{\circ}$  of varus or valgus in the coronal plane). Open arthrodesis is best utilized for patients with moderate to severe deformity as this allows for better visualization for malalignment correction. Additionally, as fusion of the ankle joint will inevitably lead to a lack of motion, pre-operative balance of the forefoot is essential. Therefore, careful examination of forefoot balance without excessive pronation or supination is needed. Arthroscopic or open debridement with subsequent external fixation would be preferred by the authors in patients with significant malalignment, comprised skin, limbs discrepancies, and active/previous infection (8).

### **Types of Ankle Arthrodesis**

Numerous surgical techniques for ankle arthrodesis have been described. The technique should be selected based on patient characteristics, function and goal of treatment, as well as the preference of the surgeon (5).

### **Approach**

The approach to ankle arthrodesis is broadly divided into **open** and **arthroscopic** techniques. The open approach is further subdivided into the anterior approach, posterior approach, lateral approach, medial approach, and combined medial and lateral approach. Compared with the arthroscopic approach, the main benefit of an open approach includes less difficulty in correcting malalignment, and ease in applying plates and bone grafts. However, open arthrodesis is associated with higher rates of wound complications due to the extensive amount of soft tissue dissection required. This can subsequently lead to longer hospitalization and recovery. Therefore,

open approaches are generally reserved for patients with moderate to severe ankle deformities with healthy skin (9).

Arthroscopic ankle arthrodesis is indicated for patients with minimal ankle joint deformity (less than 15° of varus or valgus in coronal plane) or patients who are at higher risk of wound complications (e.g., immunosuppressed, diabetics, rheumatoid arthritis patients). Although arthroscopic arthrodesis is increasingly becoming popular, open ankle arthrodesis remains the mainstay procedure for ESAA in the United States of America (10).

### **Fixation methods**

Both internal and external fixation may be used in ankle arthrodesis. Each has its unique advantages; successful outcomes having been demonstrated with both fixation methods. Various methods of internal fixation have been described, including screws, plates, and retrograde intramedullary nails. Many surgeons prefer to use screw fixation as the primary means of internal fixation, because screws are easy to use, have low morbidity (they only require small percutaneous incisions) and are cheaper compared to most other methods. However, higher nonunion rates of the ankle joint have been reported with screw fixation especially in osteoporotic bone (5).

**Plates** are advantageous for ankle arthrodesis because there are many options when using plates. The surgeon has choices with regard the type of plate needed (e.g., conventional or locking), how many plates and where to place the plates. While some surgeons prefer plates because they are stiffer constructs than screws that may achieve better union rates, the extensive dissection needed to place the plate can lead to a higher risk of infection and morbidity.

A combination of plates and screws may also be used. A recent biomechanical study found that a combination of plate and screw fixation provided significantly greater stiffness than plates or screws alone. In this study there were no significant difference between 3 compression screws, anterior plate and lateral plate fixation (11).

**Retrograde intramedullary arthrodesis** is typically reserved for arthrodesis of both the ankle and subtalar joints. Patients with ESAA typically have concomitant subtalar arthritis. In these patients, it is difficult to delineate whether the pain is coming solely from the tibiotalar joint, the subtalar joint or a combination of both. The surgeon must determine this preoperatively because it is best to avoid arthrodesis of the subtalar joint whenever possible especially when the ankle will be fused. In the setting of a tibiotalar arthrodesis the subtalar joint is critical for gait stability. The subtalar joint allows for inversion and eversion of the ankle joint and therefore, this can compensate for a more stable gait when joint motion is permanently reduced post-arthrodesis (12).

**External fixation** is typically indicated for patients with significant bone defects, limb length discrepancies, poor bone quality, and active or previous infection. (5).

### **Operative Treatment**

Two standardized methods of ankle arthrodesis for ESAA are described here: **Open and arthroscopic**. For both methods, the joint is fixed with two or more screws. Patients are placed in

a short leg cast and immobilized for 6 wks. Patients have achieved successful outcomes following either approach in our experience (13).

### **Open arthrodesis with screw fixation**

#### **Patient positioning and equipment:**

The patient is placed in the supine position with the feet at the edge of the bed. A tourniquet is typically used at the level of the thigh and applied before the start of the case. All equipment should be confirmed prior to the onset of the case. Osteotomes, a bone saw, and curettes are needed for the osteotomy and debridement of the joint surface. A large fragment cannulated drill set, and screws (4.0/6.5/7.3 mm) are required to fuse the ankle joint. Fluoroscopy should be used to confirm ankle alignment and screw positions (5).

#### **Steps of the procedure:**

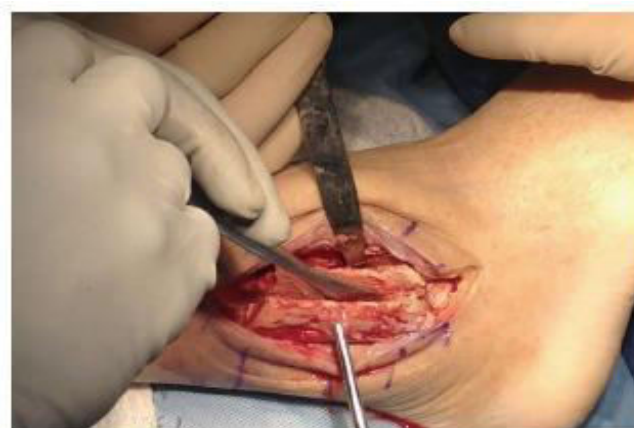(1) Marking anatomical landmarks: Anatomical landmarks are marked using a sterile surgical marker. In this procedure, the lateral malleolus (LM), medial malleolus (MM), ankle joint line, fourth metatarsal, fifth metatarsal, superficial peroneal nerve, and sural nerve are all identified and marked. Then, a hockey-stick-shaped incision is outlined over the lateral aspect of the LM, starting approximately 7.0 cm above the tip of the LM and extending distally to the base of the fourth metatarsal. Additionally, a longitudinal medial skin incision line is marked over medial gutter of ankle joint (5).

(2) Skin incision and osteotomy of distal fibula.

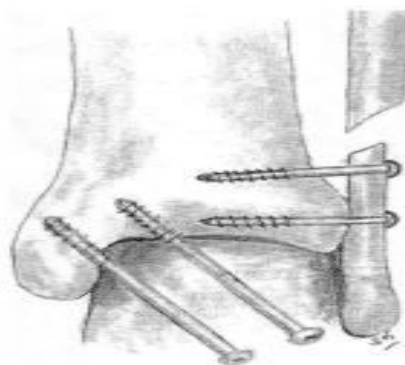
(3) Debridement of joint surface cartilage.

(4) Fusion of tibiotalar joint: The tibiotalar joint is fixed typically using two to three 7.3 mm cannulated screws after adequate alignment is obtained. The alignment of tibiotalar joint should be slightly valgus ( $0^{\circ}$ - $5^{\circ}$ ), neutrally dorsiflexed, and slightly external rotation  $10^{\circ}$ - $15^{\circ}$  (5).

(5) Fusion of lateral malleolus to tibia, two 4.0 mm screws are used to fix the lateral malleolus and distal tibia into place (5).



**Figure (3):** Lateral transfibular approach. (5).



**Figure(4):**Anteroposterior scheme shows the placement of screws. (5).

### **Arthroscopic arthrodesis with screw fixation**

#### **Patient positioning and equipment:**

General arthroscopy equipment is required for an arthroscopic arthrodesis. A 2.7/4.0 mm, 30°/70° arthroscope is typically used. Shavers are required for debridement of soft tissue and for bony resection. A non-invasive distractor and irrigation system are both helpful to obtain good visualization. The fluid pressure is usually set at 50 to 60 mmHg with the fluid flow rate at 0.5 L/min. The ankle joint is fixed using equipment from the large fragment cannulated drill and screw set (6.5 mm). For this procedure, fluoroscopy is necessary (5).

The patient is placed in the supine position with the ipsilateral hip flexed and supported by a well-padded leg holder. The position of the holder should be proximal to popliteal fossa to avoid constriction of the neurovascular bundle. The ankle and hindfoot is held with a sterile distraction strap (5).

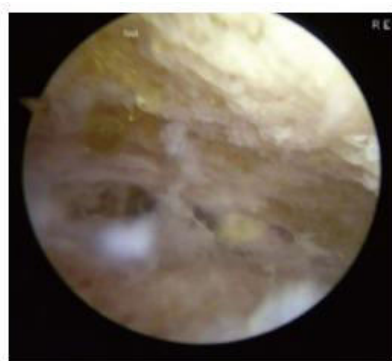
#### **Steps of the procedure:**

(1) Marking anatomical landmarks and establishing portals: The careful identification of anatomical landmarks is critical for any arthroscopic procedure of the ankle. The most commonly injured nerve following anterior ankle arthroscopy is the superficial peroneal nerve (up to 2.9%)(14). Anterior ankle arthrodesis is performed using anteromedial (AM), anterolateral (AL) and occasionally posterolateral (PL) portals. The lateral malleolus (LM), medial malleolus (MM), peroneus tertius, tibialis anterior tendon (TAT), superficial peroneal nerve, and sural nerve are all identified and marked. At the level of ankle joint, the AM portal is established just medial to the medial border of the TAT and the AL portal is placed lateral to peroneus tertius. The PL portal is marked 1.0 mm anterior to the lateral borders of Achilles tendon with also bring at horizontal level with the inferior pole of the MM and the tip of LM. Arthroscopic portals are created using “nic and spread” technique to decrease the risk of iatrogenic nerve damage. After the skin incision, subcutaneous blunt dissection is performed using a mosquito clamp. A 2.7 mm arthroscope sleeve with a trocar is then carefully advanced. Once the anterior aspect of tibia can be palpated with the trocar, it is switched out for a 2.7 mm arthroscope. The authors prefer the insertion of portals in the following order: AM portal, AL portal and PL portals (5).

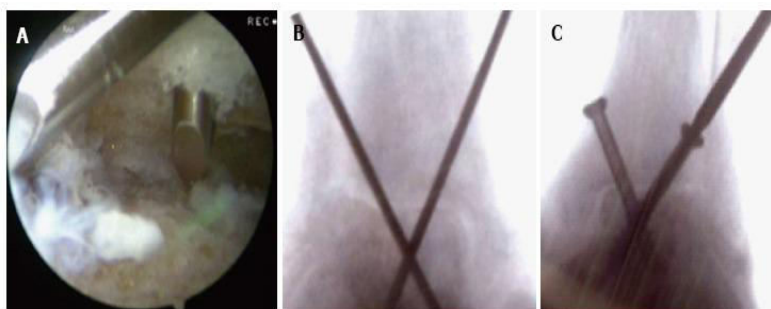
(2) Debridement and exposure: Debridement of the synovium and scar tissue is typically required to improve visualization of the ankle joint surface. Any remaining cartilage on the tibia, the talus or in the medial or lateral gutters is then debrided using a shaver, burr, or curette.

(3) Tibiotalar fixation: The tibiotalar joint is fixed typically using two to three large, cannulated screws (15).





**Figure(5):** Any remaining cartilage on the tibia, the talus or in the medial or lateral gutters is debrided (15).



**Figure(6):** Kirschner wires should be altogether inserted at the tibial joint surface. A: Arthroscopic view shows the location of the Kirschner wires; B: Fluoroscopic view shows location of Kirschner wires; C: Screw fixation (15).

### Biologics

Biologics may be used to aid in fusion of the ankle in both the open and arthroscopic techniques. Two types of biologics are currently available: Osteoconductive and osteoinductive agents. Osteoconductive agents, e.g., bone allografts, demineralized bone matrix and various apatitic pastes, are agents that serve as a scaffold at the site of fusion. This scaffold acts as a tissue network to facilitate autologous cell interaction for osteogenesis. Osteoinductive agents, e.g., bone morphogenetic proteins, platelet-rich plasma or concentrated bone marrow aspirate, are agents that directly facilitate osteogenesis. This may be in the form of containing growth factors (platelet-rich plasma) or stem cells (concentrated bone marrow aspirate) to stimulate the formation of osteoblasts. Biologics should be placed into the fusion site before and after the final seating of screws (5).

### Postoperative Rehabilitation

The ankle joint is immobilized in a non-weightbearing leg cast for 6 wk. The cast is then removed, and the patient is transferred over to a Controlled Ankle Movement Walker Boot. Radiographs should be taken at intervals of 6 wk, 3 mo, 6 mo and 1 year to assess the position of fusion and adequacy of union. A gradual 10% increase every two weeks in weight bearing is advised. However, as soon as complete union is evident on radiographs, patients may be allowed to fully weight bearing (5).

## **Ankle Arthrodesis Using Retrograde Nail**

### **Background:**

When ankle and subtalar joints are arthritic and painful, they both need fusion. This simultaneous fusion of both joints, so called pantalar arthrodesis (PA) is truly a salvage procedure, an alternative to amputation. Previously, PA arthrodesis was meant to fuse only ankle and subtalar joints. Currently, however, PA includes talonavicular and calcaneocuboid joints besides ankle and subtalar joints. Historically, pantalar arthrodesis was done in two stages: Stage I—subtalar arthrodesis, Stage II— ankle arthrodesis. Currently, it is done in one stage, as the results of either one or two stages are the same. There are several methods of doing PA. The principle of treatment, however, remains the same. They are removal of cartilage till bleeding of subchondral bone, keeping the joint surfaces congruous, proper positioning of the foot and ankle and stable fixation. Currently, internal fixation with screws and/or plate, retrograde nailing and ring fixator are preferred methods of fixation (16).

When both ankle and subtalar joints are involved, the preferred technique of fixation is retrograde tibial nail, which passes through calcaneus, talus and tibia. Tibiototalcalcaneal arthrodesis (TTCA) with intramedullary fixation is not a new idea. The first case of tibiototalcalcaneal arthrodesis with an intramedullary (IM) nail was reported by Adams JC2 in 1948. Before the advent of retrograde intramedullary nailing, ankle and subtalar joints were fused using internal or external fixation. However, retrograde tibial nail has certain advantages. The purpose of this thesis is to evaluate the results of retrograde Intramedullary locking nail for PA and evaluation of the nail (16).

### **Indications for Retrograde Nailing in tibiotalar and subtalar joints**

- Traumatic arthritis
- Neuropathic deformities (Charcot joints)
- Osteoarthritis of ankle and subtalar joints
- Rheumatoid arthritis
- failed total ankle replacement.
- Revision arthrodesis
- severely crushed talus, Avascular necrosis of the talus and tumors infection of talus (17).

### **Preoperative Planning**

Careful evaluation is critical for better outcomes.

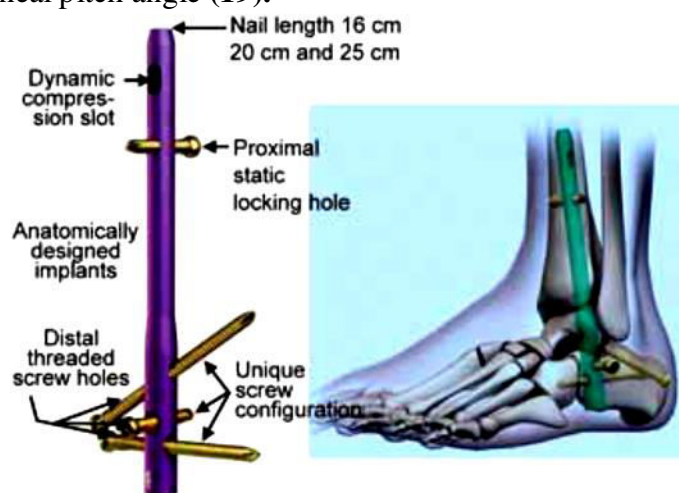
- A. Bone quality
- B. Metabolic disease,
- C. Previous injuries and skin condition are carefully assessed.
- D. Mobility of each joint must be tested.
- E. X-rays of ankle and foot.
- F. Computed tomography is useful to access all deformities.
- G. Blood count, ESR and CRP are important to rule out infection (18).

### **Newer Nail Designs**

The retrograde nails initially used 10 years back, did not have good control over movements of the subtalar joint and calcaneum because the initial nails did not have posteroanterior locking screws.

Therefore, the failure rate was very high. During the past 10 years, the retrograde tibial nail has evolved. Many companies have developed different designs. They all have similar principles. The nail passes through the calcaneum and allows fixation of calcaneum talus and tibia. Initially, older the calcaneus had two latero-medial screws. This was very unstable because of the complex movements of the ankle and subtalar joints (16).

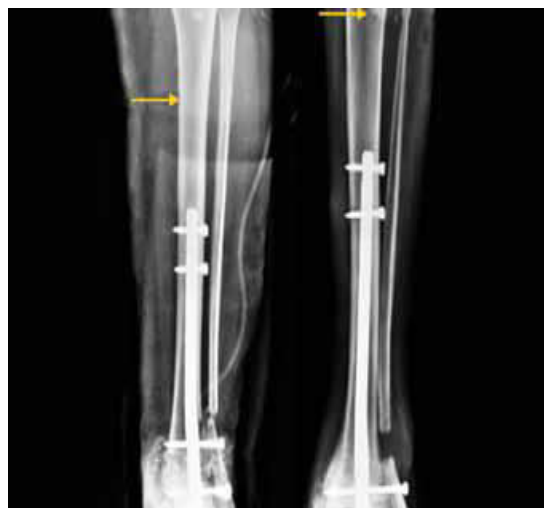Recently, added oblique screw passing through posterior aspect of calcaneum into talus and tibia, spanning one or both the joints is another important innovation. The bend presents in the nail places the heel in a mild valgus position, which is essential. The nails 10 years back had static locking screws going through the bone in the medial-to-lateral plane at all levels. This created a problem when there is erosion and subsidence in some patients, such as with Charcot joints where subsidence occurs. In such a situation, the static locking bolts keep the fusion area with a gap resulting in nonunion or failure of fusion. In the newer design posteroanterior screw was inserted at 20° upward angle parallel to the inferior surface of the calcaneum. This allowed better fixation and matched the calcaneal pitch angle (19).



**Figure (7):** The newer nail has two posteroanterior screws inserted to the calcaneal tuberosity into the retrograde nail: (1) the cuboid screw is passed at 20° parallel to the inferior surface of the calcaneum which matches the calcaneal pitch. The second screw is passed into the talus and third screw is mediolateral screw. The proximal end has a dynamic hole and a static hole (19).

Posteroanterior screw passing into the talus is important to improve the construct stability. The Trigen Hindfoot Fusion Nail (Smith and Nephew) allows independent positioning of the two distal locking screws. The calcaneal screw is directed from the medial part of the calcaneal tuberosity through the nail towards cuboid at a 20° inclination. The more proximal talar screw starts from the lateral part of the calcaneal tuberosity through the nail and into the talar neck at a 60° inclination. This allows posterior to anterior locking distally, independently to prevent rotation around the nail and improve resistance to dorsiflexion-plantar flexion motion (19).

The short nail causes stress riser effect at the proximal end of the nail and may result in fracture. Therefore, currently now routinely use a 300-mm nail for TTCA procedures. This longer nail allows for stabilization of the nail in the isthmus of the tibia (19).



**Fig. (8):** Short nail causes stress raiser effect resulting in stress fracture, so currently longer nails are preferred (19).

**Conflict of Interest:** No conflict of interest.

#### References

1. **Manganaro, D., Dollinger, B., Nezwek, T. A., et al. (2019):** Anatomy, Bony Pelvis and Lower Limb, Foot Joints.
2. **Agur, A. M., & Dalley, A. F. (2018):** Moore's essential clinical anatomy. Lippincott Williams & Wilkins.
3. **Roskopf, A. B., Loupatatzis, C., Pfirrmann, C. W., et al. (2019):** The Charcot foot: a pictorial review. Insights into imaging, 10 (1), 77.
4. **Papanas, N., & Maltezos, E. (2013):** Etiology, pathophysiology and classifications of the diabetic Charcot foot. Diabetic foot & ankle, 4(1), 20872.
5. **Yasui Y, Vig KS, Murawski CD, et al. (2016):** Open Versus Arthroscopic Ankle Arthrodesis: A Comparison of Subsequent Procedures in a Large Database. J Foot Ankle Surg, 55:777–781.
6. **Terrell RD, Montgomery SR, Pannell WC, et al. (2013):** Comparison of practice patterns in total ankle replacement and ankle fusion in the United States. Foot Ankle Int. 2013; 34:1486–1492.
7. **Nihal A, Gellman RE, Embil JM, et al. (2008):** Ankle arthrodesis. Foot Ankle Surg, 14:1–10.
8. **Winson IG, Robinson DE, Allen PE. (2005):** Arthroscopic ankle arthrodesis. J Bone Joint Surg Br, 87:343–347.

9. **Jordan RW, Chahal GS. (2014):** Chapman A. Is end-stage ankle arthrosis best managed with total ankle replacement or arthrodesis? A systematic review. *Adv Orthop*, 986285.
10. **Chun, D. I., & Won, S. H. (2018):** Ankle Arthrodesis. *Journal of Korean Foot and Ankle Society*, 22(1), 1-7.
11. **Clifford C, Berg S, McCann K, et al. (2015):** A biomechanical comparison of internal fixation techniques for ankle arthrodesis. *J Foot Ankle Surg*, 54:188–191.
12. **Zwipp H, Rammelt S, Endres T, et al.(2010):** High union rates and function scores at midterm followup with ankle arthrodesis using a four screw technique. *Clin Orthop Relat Res*, 468:958–968.
13. **Kennedy JG, Hodgkins CW, Brodsky A, et al. (2006):** Outcomes after standardized screw fixation technique of ankle arthrodesis. *Clin Orthop Relat Res*, 447:112–118.
14. **Deng DF, Hamilton GA, Lee M, et al. (2012):** Complications associated with foot and ankle arthroscopy. *J Foot Ankle Surg*, 51:281–284.
15. **Malekpour L, Rahali S, Duparc F, et al. (2015):** Anatomic Feasibility Study of Posterior Arthroscopic Tibiotalar Arthrodesis. *Foot Ankle Int*, 36:1229–1234.
16. **Kulkarni, G. S. (2016):** 18 Retrograde Tibial Nailing for Arthrodesis of Ankle and Subtalar Joints. *Tanna's Interlocking Nailing*, 185.
17. **Palmanovich, E., Ohana, N., Yaacobi, E., et al. (2020):** Preoperative planning and surgical technique for optimizing internal fixation of posterior malleolar fractures: CT versus standard radiographs. *Journal of Orthopaedic Surgery and Research*, 15(1), 1-9.
18. **Motley TA, Carpenter BB. (2012):** Pantalar arthrodesis Chapter 61—McGlamry’s comprehensive Textbook of Foot and ankle surgery. 4th edn. Wolters Kluwer/Lippincott Williams and Wilkins, 1. p. 855z.
19. **Kitaoka H. (2013):** Master techniques in orthopaedic surgery. The foot and ankle. 3rd ed. USA: Lippincott Williams & Wilkives; Total ankle arthroplasty,Chapter 38, p. 597-618.