

Treatment of Proximal Humerus Fractures: Comprehensive Overview

Mohammed Othman Mohammed Abdurabbah¹, Yousof Mohamed Mohamed Khera², Ahmed Mohamed Ahmed Nahala³, and Hossam Fathi Mahmoud⁴

¹Faculty of Medicine – Omar Almuktar University – Libya.

²Professor of Orthopedic Surgery, Faculty of Medicine Zagazig University.

³Ass. Professor of Orthopedic Surgery, Faculty of Medicine Zagazig University.

⁴Lecturer of Orthopedic Surgery, Faculty of Medicine Zagazig University.

Corresponding author: Mohammed Othman Mohammed Abdurabbah

Email: mohamansory90@gmail.com

Abstract

Background: Proximal humerus fractures are one of the commonest fractures occurring in the skeleton. They account for approximately 4 – 5% of the all fracture. The incidence of fracture of the proximal humerus is bimodal in geriatric due to osteoporosis and in adolescents due to high-energy trauma. A conservative treatment in a sling followed by functional rehabilitation under supervision yields satisfactory results in minimally displaced fractures. The proximal humerus is adapted to allow for the large range of motion of the shoulder joint. The proximal humerus consists of the humeral head, the greater, lesser tuberosities, and shaft. The region of transition between the articular cartilage and surrounding bone is defined as the anatomic neck and serves as the site of attachment of the articular capsule, whereas the region immediately inferior to the tuberosities is termed the surgical neck. The incidence of proximal humerus fractures is increasing, especially in the elderly. Proximal humeral fractures account for 4% to 5% of all fractures in adults and less than 1% of children's fractures. Approximately 3% of physal fractures occur through the proximal humerus. Operative management can consist of closed reduction and percutaneous fixation, suture fixation, operative fixation with plate and screw construct, or intramedullary fixation. The goals of operative fixation are to restore the anatomy of the proximal humerus to allow for successful union, maximize function and early rehabilitation. The articular surface's relationship to the shaft must be restored to maximize range of motion as well as stability. The tuberosities must also be reduced to their anatomical position especially Isolated fractures of the greater tuberosity may be managed surgically even with less displacement to maximize function of the arm by re-establishing the insertions of the rotator cuff.

Keywords: Fracture Proximal Humerus, Three or four parts, K-wire plate fixation.

Anatomy of the proximal humerus:

I-Bone

The proximal humerus is adapted to allow for the large range of motion of the shoulder joint. The proximal humerus consists of the humeral head, the greater, lesser tuberosities, and shaft. The region of transition between the articular cartilage and surrounding bone is defined as the anatomic neck and serves as the site of attachment of the articular capsule, whereas the region immediately inferior to the tuberosities is termed the surgical neck (Fig.1). (1)

The inclination of the humeral head relative to the long axis of shaft averages 130 degrees. In the axial plane, the posterior angle of the anatomic neck of the humerus with relation to the

epicondylar axis averages 17 degrees and ranges from 5 degrees of anteversion to 50 degrees of retroversion (Fig.2). (1)

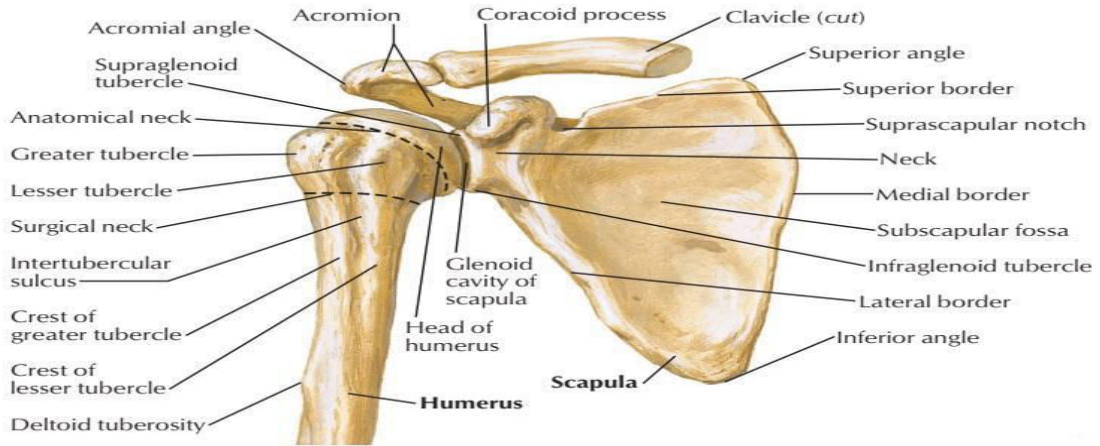


Fig:(1) A: anterior and B: posterior views of proximal humerus and scapula (17)

II-Muscles

The rotator cuff is composed of the subscapularis anteriorly, the supraspinatus superiorly, and the infraspinatus and teres minor posteriorly.⁽¹⁶⁾ The rotator cuff muscles play an important role in displacement of proximal fracture segment, whereas pectoralis major is responsible for displacing the shaft segment. The proximal humerus is composed of **the lesser tuberosity**, which is the site of insertion of the subscapularis; **the greater tuberosity**, which has three facets for insertion of the supraspinatus, infraspinatus, and teres minor; the humeral head; and the shaft⁽¹⁶⁾

Furthermore understanding of the deltoid anatomy and the interval between deltoid and pectoralis major is important to safely achieve fracture exposure⁽¹⁶⁾

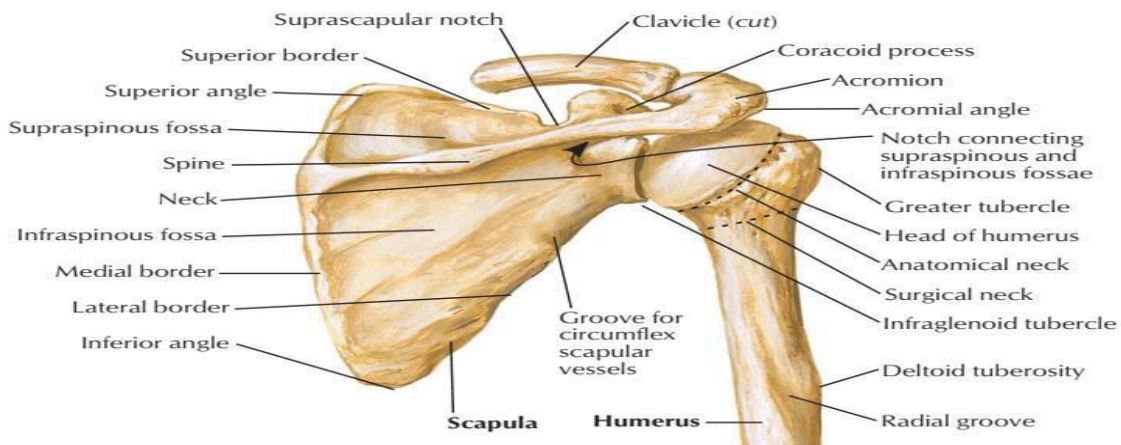


Fig:(2) A: anterior and B: posterior views of proximal humerus and scapula (17)

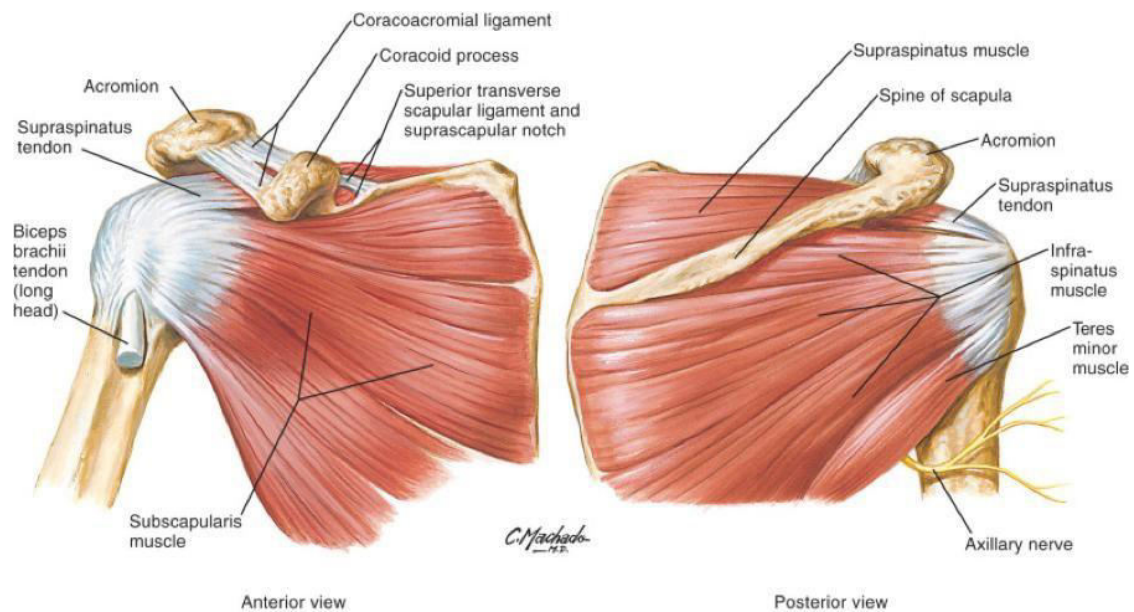


Fig (3): Anatomy deltopectoral region ant shoulder

III-NERVES

The axillary nerve is one of the terminal branches of the posterior cord of the brachial plexus C5-C6. Its motor fibers innervate the teres minor and deltoid muscles; the sensory fibers innervate the skin overlying the lateral aspect of the proximal arm (fig.5).⁽¹⁶⁾

The axillary nerve enters the quadrangular space along with the PCHA near to the surgical neck. In the quadrangular space, the nerve divides into anterior and posterior branches, the posterior branch provides motor input to the teres minor and posterior and middle heads of the deltoid before terminating as the superior lateral brachial cutaneous nerve⁽¹⁶⁾

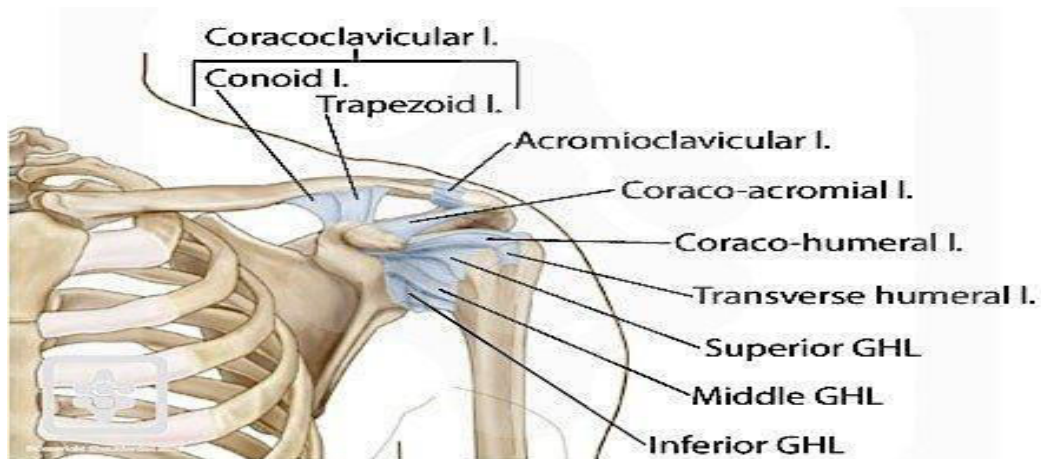
IV- LIGAMENT

Superior Gleno-humeral Ligament

The most superior capsular thickening arises from the labrum at the level of the coracoid base. It passes under the supraspinatus muscle and inserts on the anatomic neck of the humerus.⁽¹⁸⁾

Middle Gleno-humeral Ligament

The middle glenohumeral ligament (MGHL) arises just inferior to the superior GHG and inserts along the middle area of the anatomic neck of the humerus.⁽¹⁹⁾



Fig(4): Glenohumeral Ligament ⁽¹⁹⁾

Inferior Gleno-humeral Ligament

The thickest part of the capsule is the inferior glenohumeral ligament (IGHL). arising from the lower half of the labrum (anterior, inferior, and posterior). The superior margin is designated the superior band, while the rest of the ligament is called an axillary pouch. Both the superior band and the anterior pouch insert on the anatomic neck of the humerus. The posterior pouch dips down to insert on the surgical neck. ⁽¹⁸⁾

Coraco-humeral Ligament

Arising from the lateral base of the coracoid process, it joins the capsule on its exterior surface and extends to both the greater and lesser tuberosities, forming part of the roof of the bicipital tendon sheath. ⁽¹⁸⁾

Coraco-acromial Ligament

It extends between the coracoid process and the acromion, and supports the superior aspect of the joint ⁽¹⁸⁾

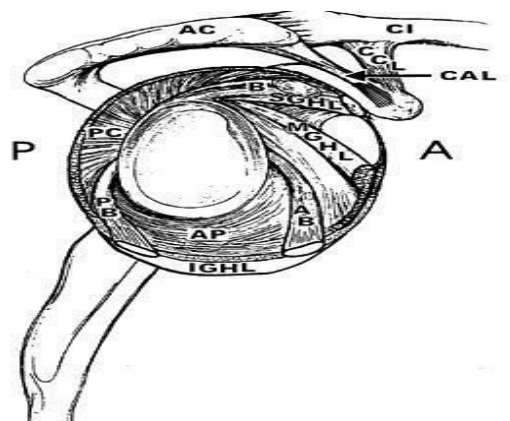


Fig (5): Ligaments of the shoulder as they encircle the glenoid fossa. B, tendon of the long head of the biceps; SGHL, superior glenohumeral ligament; MGHL, middle glenohumeral ligament; CAL, coracoacromial ligament; CCL, coracoclavicular ligaments. Components of the inferior glenohumeral ligament: AB, anterior band; AP, axillary pouch; PB, posterior band; PC, posterior capsules. ⁽²⁰⁾

Clinical Evaluation Incidence

The incidence of proximal humerus fractures is increasing, especially in the elderly. Proximal humeral fractures account for 4% to 5% of all fractures in adults and less than 1% of children's fractures. Approximately 3% of physal fractures occur through the proximal humerus. (4)

Proximal humerus fractures account for over 75% of humerus fractures in patients older than age 40, After age 50 women have a much higher incidence than men especially after menopause, representing the typical characteristic of an osteoporotic fracture. (5)

In younger age the high-energy trauma is the most common cause of proximal humerus fractures. Up to 85% of all proximal humerus fractures are one-part (non-displaced or minimally displaced) fractures; 15% to 20% of all proximal humerus fractures are classified as displaced. (6)

Obtaining a medical history with special attention to nutritional status, osteoporosis, and diabetes may help with treatment planning, as well as long-term follow-up care. Patients should also be evaluated for their physiological age rather than their chronological age. (7)

The symptoms and signs associated with proximal humerus fractures can be quite variable. However, they most often correlate with the degree of fracture displacement and comminution. Pain especially with any attempts at shoulder motion, is almost always present. Inspection of the shoulder usually reveals swelling and ecchymosis. the ecchymosis that develops may extend distal to the arm and forearm or even to the chest and breast area. (6)

Palpation of the shoulder will usually reveal tenderness about the proximal humerus. Crepitus may be evident with motion of the fracture fragments. The entire upper extremity should be examined. The chest should be examined, because rib fractures may occur from a fall (7)

Essential to the clinical evaluation of the patient with a proximal humerus fracture is a complete neurovascular examination of the involved upper extremity. Associated axillary artery and brachial plexus injuries have been reported, especially with fracture displaced medial to the coracoid process. About 20% incidence of nerve injury is reported. Fracture's dislocations increase the incidence of neurovascular injury. The most commonly injured peripheral nerve is the axillary nerve. Both sensory and motor testing should be performed to evaluate axillary nerve function through electromyography (EMG) and nerve conduction tests. (8).

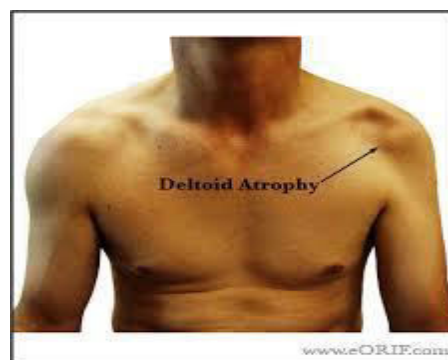


Fig (6): This patient sustained an axillary nerve palsy secondary to glenohumeral dislocation. note the significant wasting.(9)

Treatment of Proximal Humeral Fractures:

Proximal humeral fractures can form a challenge for the treating surgeons because of the generally osteoporotic nature of bone in the elderly and the relative deforming forces of the surrounding

muscles, treatment is often guided by the relative displacement of the anatomic fragments. (10)
Non-displaced fractures treated conservatively, with generally good outcomes. Displaced fractures with angulation of the articular surface $>45^\circ$ and displacement of the major segments >1 cm have been treated surgically. (10)

Operative fixation can provide stability if there is a need for any vascular or nerve repair procedures. Patients who are medically unstable can be treated conservatively or treated in a delayed fashion once they are more physiologically stable. (11)

The fracture pattern can also give clues to the risk of vascular injury to the humeral head and future risk of avascular necrosis. The longer the medial metaphyseal extension of the head, the more likely the vascularity to the humeral head is intact. Also, the severity of osteoporosis can affect the success of operative fixation. (12)

Measuring the cortical thickness of the diaphyseal bone can be a predictor of the bone mineral density, which can affect the success of operative fixation. surgeon should also evaluate the radiographs for osteoarthritis or signs of significant rotator cuff disease such as upward shift of humeral head, as these can have an impact on outcome and treatment. (12)

Non-operative Treatment

Non-operative treatment is indicated for minimally displaced fractures, which according to Neer do not meet the criteria of more than 1 cm of displacement and 45 degrees of angulation. Other relative indications for non-operative treatment may include elderly or debilitated patients with multiple medical problems. However, the outcome of anatomic reduction and fixation is better than that of non-operative treatment, which may lead to nonunion or malunion. If non-operative treatment is selected, a sling is usually applied from 1 to 2 weeks. Elbow and hand motion is encouraged immediately to reduce the risk of extremity swelling. (13)

As non-operative treatment is most frequently used for impacted fractures, passive motion is allowed at no later than 2 weeks when they have assessed that gentle movement of the shoulder is not associated with pain and that the humerus moves as a one unite, X-rays are obtained as well to make sure that the fracture fragments have not displaced with motion. If movement at the fracture site is detected clinically or radiographically, immobilization is maintained for another 2 weeks, followed by repeated evaluation. (14)

After 4 to 6 weeks, if x-rays shown no change in fracture position and evidence of early callus formation, active motion should be started. Strengthening can usually begin at 2 to 3 months after injury. Minimally displaced fractures treated according to this method generally have a high success rate. The major complications following conservative management are symptomatic nonunion, severe loss of motion, avascular necrosis, and posttraumatic arthritis. (15)

Operative Treatment:

Operative management can consist of closed reduction and percutaneous fixation, suture fixation, operative fixation with plate and screw construct, or intramedullary fixation. The goals of operative fixation are to restore the anatomy of the proximal humerus to allow for successful union, maximize function and early rehabilitation. (15)

The articular surface's relationship to the shaft must be restored to maximize range of motion as well as stability. The tuberosities must also be reduced to their anatomical position especially Isolated fractures of the greater tuberosity may be managed surgically even with less displacement to maximize function of the arm by re-establishing the insertions of the rotator cuff. (15)

Closed reduction and percutaneous fixation:

With Percutaneous fixation of proximal humeral fractures less disruption of the vascular supply than conventional open approaches. (16)

The indications for closed reduction and percutaneous pinning include fractures without comminution with good bone quality. Every week radiographic evaluation and shoulder immobilization for duration of 4 to 6 weeks are required. (17)

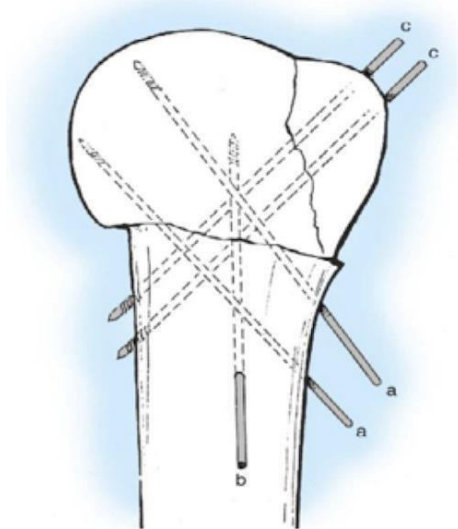
Contraindications include the presence of severe osteopenia or osteoporosis. Comminution of the proximal part of the humeral shaft is also a relative contraindication. Tuberosity comminution that prevents screw or pin fixation precludes the use of this technique. (18)

Operative Technique**Preparation:**

The patient is placed in the beach-chair position with the affected shoulder resting outside the perimeter of the operating table under general anesthesia. This setup allows easy access to an image intensifier. With the C-arm of the image intensifier located cranially, anteroposterior and axillary views of the upper end of the humerus are easily obtained.

Pinning Technique**a) Conventional method:**

The fracture is first reduced under fluoroscopic guidance and either K-wire or screws are inserted percutaneously to stabilize the fracture. Through a stab incision at the level of the surgical neck, the humeral head is elevated with a reduction tool, re-establishing the neck-shaft angle. An anterior pin, an lateral pin, or an antero-lateral pin can be used. The antero-lateral pin is most commonly employed to achieve percutaneous fixation of the shaft to the humeral head. A fourth option, a supero-lateral pin, can be used as a supplement if instability is a problem, but it will slow rehabilitation because it will impinge on the acromion. (18)



Fig(7): Placement of percutaneous pins for fracture fixation. (19)

For safe starting point, lateral pins should enter the humeral cortex at a point just proximal to the deltoid insertion (about twice the distance from the top of the humeral head to the most inferior margin of the articular cartilage as the incision for the fracture reduction) to avoid injury to both the radial nerve at the spiral groove and axillary nerve which is located at an average of 5 cm distal to the acromion with the pin angulated approximately 45 degrees to the cortical surface (20)

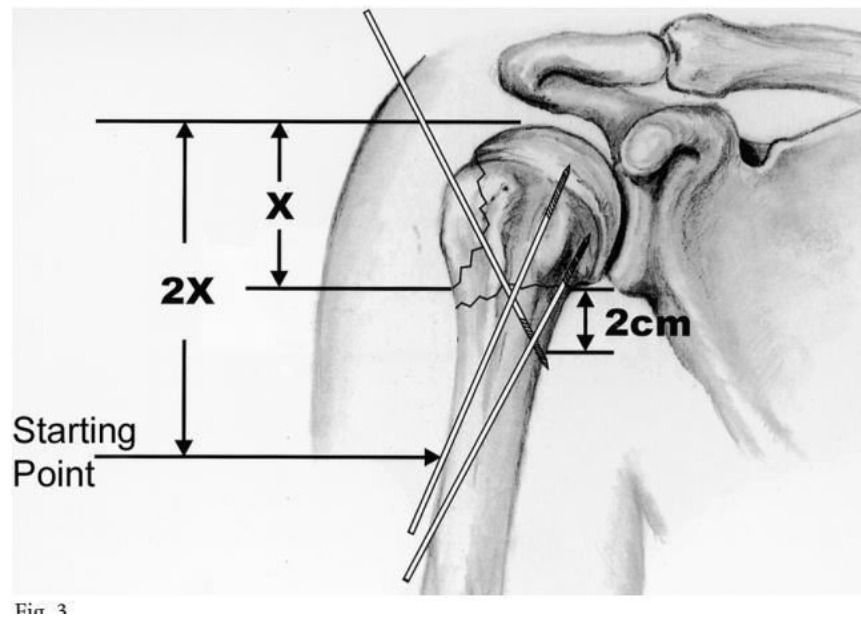


Fig (8): The safe starting point for the proximal lateral pins at the end point for the greater tuberosity pins. X = distance from the superior most aspect of the humeral head to the inferior most aspect of the humeral head. $2X$ = the starting Point for the proximal lateral pin. The end point for the greater tuberosity pin should be >2 cm from the inferior most margin of the humeral head. (20)

b) Modified method:

After the arm and shoulder are draped freely, only longitudinal traction force is applied to the upper extremity with the shoulder in adduction to enable fracture reduction. Confirmation of realignment is undertaken with adjustment of the C-arm of the image intensifier instead of rotation of the humerus. K-wires are then used as joysticks for adjustment of the reduction. We typically use 4 2.5-mm non-threaded-tipped Kirschner wires (also known as pins). We describe the first wire as the reduction pin, the second as the anti-rotation pin, and the third and fourth as the stabilization pins. (20)

Reduction Pin

Reduction of head-shaft fragments is performed with K-wires inserted from the anterior, posterior, or lateral side according to the direction of displaced head. These reduction wires are also placed in different positions depending on the fracture angulations in the sagittal plane. The first 2.5-mm non threaded K-wire is placed through the proximal fragment and passed into the shaft of the humerus.

By placing the K-wire along the wall, a two-point bending effect occurs at the fracture site. This effect enables the operator to reduce the humeral head with no great difficulty and to maintain the anatomic position (20)

Anti-rotation Pin

Counter balance to the reduction obtained by the first pin is provided by a second pin parallel to the first one. If the reduction pin is placed anterolaterally, then the anti-rotation pin is placed posterolaterally and vice versa. Both reduction and antirotation pins are advanced to the level of the midshaft (20)

Stabilizing Pins

two-tipped threaded pins are used to stabilize the fracture side. These pins are inserted into the greater tuberosity drilled into the far medial cortex obliquely passing the fracture line (20)

There are three types of wires the first is Reduction pin, the second is antirotation pin and the third is stabilizing pin (20)

Intramedullary nail:

Intramedullary nailing provides more stable fixation than percutaneous pinning, although less than locked plate fixation. Newer nail designs with polyaxial screws have more stability than earlier designs, and the addition of polyethylene bushings may increase stability and prevent screw back-out. Insertion of an intramedullary nail into the proximal humerus damage the rotator cuff, which can lead to postoperative shoulder pain. The advantages of the technique include preservation of the soft tissues and the biomechanical properties of intramedullary nails. (21)

Suture fixation

This technique has been described as a method to treat proximal humerus fractures and avoid the complications associated with implant placement and arthroplasty. Using this method, non-absorbable sutures are passed through the rotator cuff tissue and/or the bone fragments, in order to obtain and maintain the reduction. This technique avoids extensive soft tissue stripping and the risk of symptomatic implants. It also preserves the bone stock of the proximal humerus, which may allow for future procedures (22)

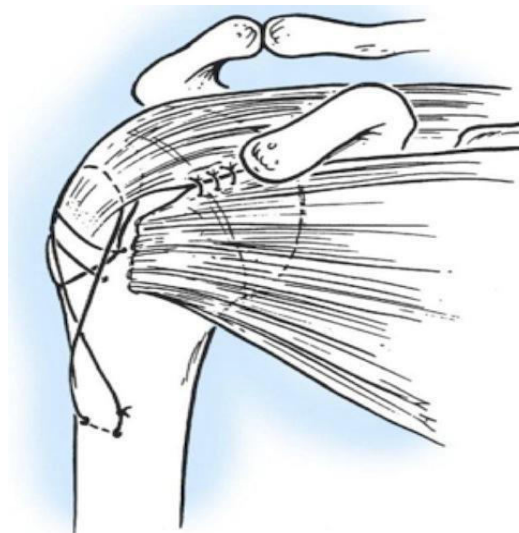

Fig (9): Transosseous non-absorbable sutures incorporate rotator cuff to increase fixation and help control tuberosity fragments. (22)

Plate fixation:

Operative fixation of the proximal humerus has evolved over the years. Development of locking technology, as well as site-specific implant, has helped overcome some of the problems initially seen with operative fixation. Locking screws have improved the fixation of the head and soft metaphyseal, and often osteoporotic bone.

Conventional plating may still be used in the case of a young patient with good bone quality.

Successful treatment with either plating technique relies on bone quality, as well as the accuracy of reduction and humeral head viability. Outcome of the patient using a combination of the plate and screws, as well as osteosuture techniques of the fragments to one another and to the plate, can increase the strength of the fixation. (23)

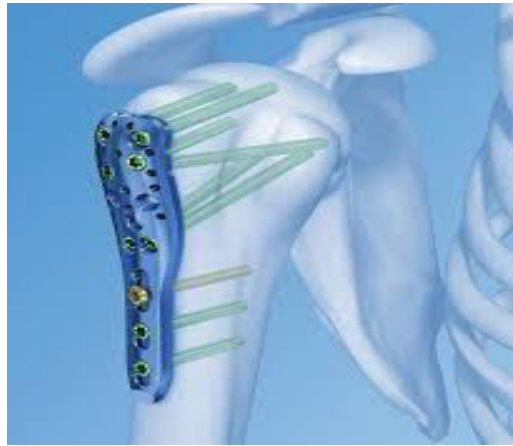


Fig (10): PHILOS Plate

Locking Plate Fixation:

The indications for fixed-angle locked plating are evolving. Its believe that open reduction and internal fixation (ORIF) with a locked plate is ideal for displaced two-part surgical neck fractures, two-part anatomic neck fractures in the patient older than age 40 years, three-part surgical neck fractures with involvement of the greater or lesser tuberosity, and most four part fractures. Fracture-dislocations are usually associated with high-energy injuries. (24)

Surgical approaches

Two surgical approaches are available: the deltopectoral and the antrolateral deltoid splitting. Each has its advantages and disadvantages. The deltopectoral is the most widely used approach and has lower risk of injury to the axillary nerve or deltoid muscle damage, but requires significant soft tissue dissection to gain access to the lateral aspect of the proximal humerus for fracture reduction and plate placement. (1)

The deltoid splitting approach gives easier access to the displaced greater tuberosity and to the area between the greater and lesser tuberosities, just lateral to the bicipital groove but has a higher risk of axillary nerve and deltoid muscle injury. (1)

If the deltopectoral approach is used, an incision is made on the anterior surface of the shoulder from the lateral edge of the tip of the coracoid process paralleling the anterior border of the deltoid and ending near the deltoid insertion. The deltopectoral interval is identified and the cephalic vein is reflected medially. Subdeltoid dissection with an elevator and a finger will lead one to the fracture fragments. (1)

If using the deltoid splitting approach a longitudinal incision is performed and the raphe between the anterior and middle deltoid identified. This interval is divided using a vertical 4 cm incision starting at the anterolateral corner of the acromion. The axillary nerve can be identified by digital palpation on the undersurface of the deltoid traveling from posterior to anterior at an average of 5 cm distal to the acromion. Since the nerve crosses the anterior raphe as a single branch innervation of the anterior deltoid can be preserved by protecting it during dissection. Once identified, the raphe may be further split distal to the nerve to allow access to the lateral shaft for plate placement. (25)

Surgical technique

After fracture exposure, the rotator cuff may be tagged with heavy, non-absorbable sutures in the supraspinatus, infraspinatus, and subscapularis insertions to aid in the reduction of fracture fragments.(26)

These sutures are later incorporated into the plate to augment tuberosity fixation and to help neutralize the deforming forces of the rotator cuff. The head is anatomically reduced via traction or is manipulated with elevators or joysticks. The fracture plane between the lesser and greater tuberosities provide good access to the head for reduction and restore the medial portion of the calcar. Once the head is anatomically reduced, it is provisionally held with K-wires and the tuberosities are then reduced with aid of the cuff sutures. (26)

After anatomic reduction has been confirmed with C-arm, the locking plate is applied. The plate is positioned just lateral to the bicipital groove and inferior to the top of the greater tuberosity to prevent plate impingement in the subacromial space (26)

After achieving fixation in the humeral head, at least three diaphyseal screws are inserted. The final fluoroscopic images should demonstrate anatomic reduction of the proximal humeral fracture. The fracture is then taken through functional range of motion of the shoulder to confirm stability and absence of impingement. Under live fluoroscopy, screw position should be carefully checked to rule out humeral head perforation. (26)

Restoration of the medial hinge is critical to successful anatomic healing of the proximal humeral fracture. In cases of comminution or malreduction of the medial hinge, the placement of calcar specific screws is critical to support the medial column and therefore maintain fracture reduction.(27).

Conflict of Interest: No conflict of interest.

References

1. **Streubel PN, Sanchez Sotelo J, Stienmann SP. (2015):** Proximal humeral fractures. In: **Court Brown CM, Heckman JD, McQueen MM, Ricci WM, Tornetta P**, editors. Rockwood and Green's Fractures in Adults. 8 th ed. Philadelphia: Wolters Kluwer; p. 1341- 1426.
2. **Netter, F. H. (2014):** Atlas of human anatomy, (6th ed.). Philadelphia, PA: Saunders Elsevier.ch.6, P404-416.
3. **Hinson AJ. (2015):** Anatomy and Classification of Proximal Humerus Fractures. In: Crosby L., Neviasser R. (eds) Proximal Humerus Fractures. Springer Cham, chapter 1 ,P1-20.
4. **Fulkerson E, Egol KA, Kubiak EN, et al (2006):** Fixation of diaphyseal fractures with a segmental defect: A biomechanical comparison of locked and conventional plating techniques. Journal of Trauma; 60:830-835.
5. **Michael L. Sidor, Joseph D. Zuckerman. (1993):** The Neer Classification System for Proximal Humeral Fractures. The Journal of Bone and Joint Surgery; 75.A:1745-1750.
6. **PHILOS and PHILOS long. (2010):** the anatomic fixation system for the proximal humerus. Synthes instrument and implant, www.synthes.com/lit.
7. **S. Brianza, G. Röderer, D. Schiuma, R. et al. (2011):** Where do locking screws purchase in the humeral head? Injury, 43 pp. 850–855.
8. **Mark Mighell Brian L. Badman. (2008):** Fixed-angle Locked Plating of Two-, Three-, and Four-part Proximal Humerus Fractures. J AAO Surg.; 16:294-302.

9. **Rosario L, Santo AR, Salvatore L, et al . (2008):** Plates with angular stability your personal experience in surgical treatment of fractures of the proximal extremity of the humerus. *ChirOrgani Mov*; 91:97–101.
10. **Brown F.W., Navigato W.J. (1968):** Rupture of the axillary artery and brachial plexus associated with anterior dislocation of the shoulder: report of a case with successful vascular repair. *Clin Orthop.*;60-195.
11. **Wade R. Smith, Bruce H. Ziran, Jeff O. Anglen, et al (2007):** Locking Plates: Tips and Tricks. *J Bone Joint Surg Am.*;307-89:2298.
12. **Sommer C., Babst R., Müller M., et al. (2004):** Locking compression plate loosening and plate breakage: a report of four cases. *J Orthop Trauma.*; 18:571-577.
13. **Andrew SN, Carolyn MH, Joshua SD, et al.(2011):** Rate of avascular necrosis following proximal humerus fractures treated with a lateral locking plate and endosteal implant. *Archives of Orthopaedic Trauma Surgery*; 1622-131:1617.
14. **Gerber C, Hersche O, Berberat C. (1998):** The clinical relevance of post traumatic avascular necrosis of the humeral head. *Journal of Shoulder and Elbow Surgery*; 7: 586-590.
15. **Connor P.M., Flatow E.L. (1997):** Complications of internal fixation of proximal humeral fractures. *Instr Course Lect.*; 46:25-37.
16. **Todd F. Ritzman. Joseph P. Iannotti.** Malunions, Nonunions, and Other Complications of Proximal Humerus Fractures, Editors: **Iannotti, Joseph P, Williams, Gerald R. (2007):** In *Disorders of the Shoulder: Diagnosis and Management*, 2nd edition, Lippincott Williams&Wilkins; 908-912.
17. **Galatz L., Iannotti J. (2000):** Management of surgical neck nonunions. *Orthop Clin North Am.*; 31(1):51-61.
18. **Johannes D. Bastian, Ralph Hertel. (2009):** Osteosynthesis and hemiarthroplasty of fractures of the proximal humerus: Outcomes in a consecutive case series. *J Shoulder Elbow Surg.*; 18: 216-219.
19. **Kirkley A, Griffin S, Dainty K. (2003):** Scoring systems for the functional assessment of the shoulder. *Arthroscopy*; 19: 1109-20.
20. **Barnes FL., Bradford O. Parsons OB., et al. (2015):** Percutaneous Fixation of Proximal Humeral Fractures. *J Bone Joint Surg Essential Surgical Techniques. Volume 5 - Issue 2 - p. e10.*
21. **Michael TH, Bjorn W, Felix A, et al (2010):** Reliability of Shoulder Abduction Strength Measure for the Constant-Murley Score. *Clinical Orthopaedic Related Research*; 468:1565–1571.
22. **Dimakopoulos P., Kasimatis G., Panagopoulos A. (2007):** Transosseous Suture Fixation of Proximal Humeral Fractures. *J Bone Joint Surg Am*; 89:1700-1709.
23. **Hinkle DE, Wiersma W, Jurs SG (2003):** *Applied Statistics for the Behavioral Sciences*. 5th ed. Boston: Houghton Mifflin.
24. **S.K. Venkatesh Gupta, Sandeep Kumar Reddy.D (2015):** A clinical study of management in proximal humerus fractures in adults with LCP plating *International Journal of Orthopaedics Sciences*; 1(1): 12-15.
25. **Seyhan, M., Kocaoglu, B., Nalbantoglu, U., et al. (2012):** Technique of Kirschner wire reduction and fixation of displaced two-part valgus angulated proximal humerus fractures at the surgical neck. *Journal of Orthopaedic Trauma*; 26: 46-50.
26. **McAnany S, Parsons B.(2014):** Treatment of proximal humeral fractures. *J Bone Joint Surg Rev.* 29;2(4).

27. Gardner MJ, Weil Y, Barker JU, Kelly BT, Helfet DL, Lorich DG. (2007): The importance of medial support in locked plating of proximal humerus fractures. J Orthop Trauma; 21:185-91.