

Original Research

## Comparison Of TIRADS (Thyroid Imaging Reporting And Data System) With Histopathology In Thyroid Swellings.

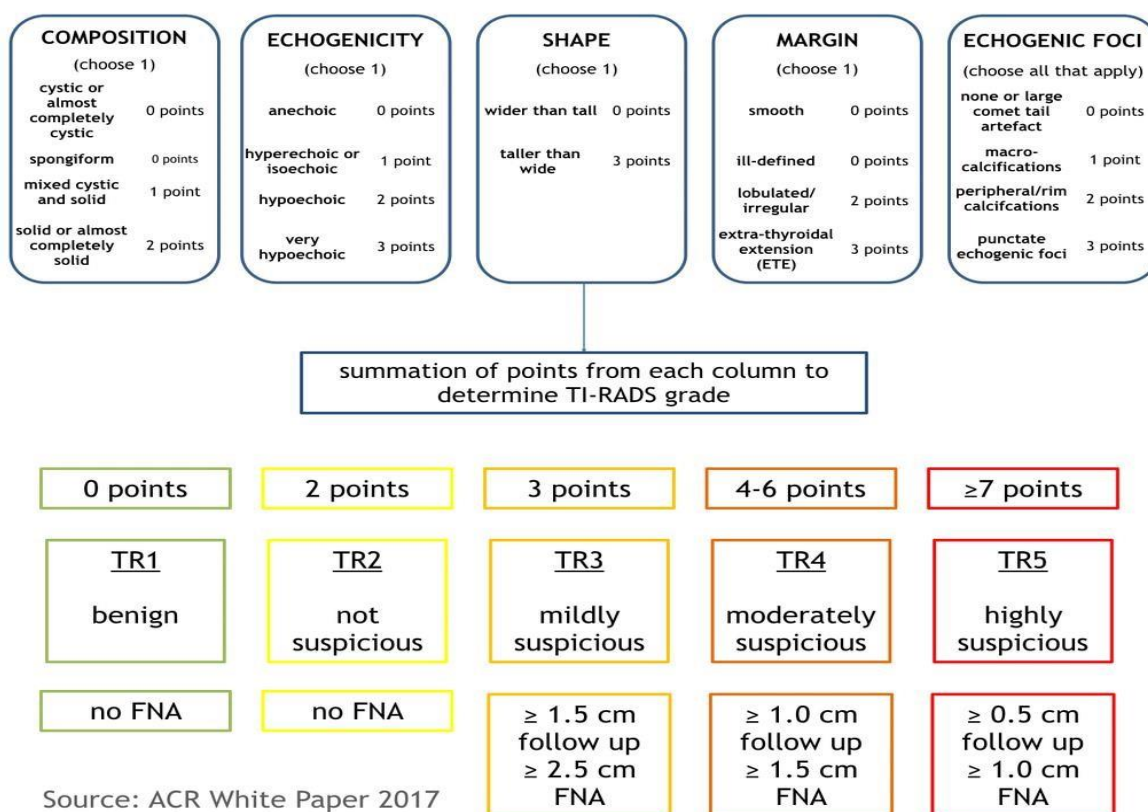
Dr. Ajjuguttu Sujitha

Co Authors: Dr. Biradar Shivanand, Dr. Billakanti Raj kumar

Institution: SVS MEDICAL COLLEGE AND HOSPITAL ,MAHABUBNAGAR

### INTRODUCTION:

Thyroid nodules are very common among general population, especially in women. It is defined as an focal discrete area of unusual growth of thyroid cells with altered echogenicity within thyroid gland that is radiologically and pathologically distinct from surrounding normal thyroid parenchyma. Its estimated incidence is around 3-7 % on clinical examination and can go as high as 67% with the use of high resolution ultrasound which as a sensitivity of 95% for detection of nodule as small as 1-3 mm. Majority of thyroid nodules are benign, but malignancy can be detected in approximately 5–15% of cases, mainly affecting patients younger than 20 or older than 60 years. High resolution ultrasound (USG) is the first line imaging modality in assessment of thyroid nodule followed by ultrasound-guided fine-needle aspiration cytology (FNAC), and surgical decision is mostly relied upon on the FNAC result. Recently, various studies have been performed using ultrasound to determine features which are predictive of malignancy in a thyroid nodule like taller than wider shape, microcalcifications, hypoechogenicity, and irregular margin. The purpose of this study is to determine the diagnostic value of ultrasound and its features in the evaluation of thyroid nodule in comparison with the final histopathologic diagnosis.



**Aims:**

To assess validity of TIRADS in differentiating thyroid nodules as benign and malignant taking histopathology as gold standard.

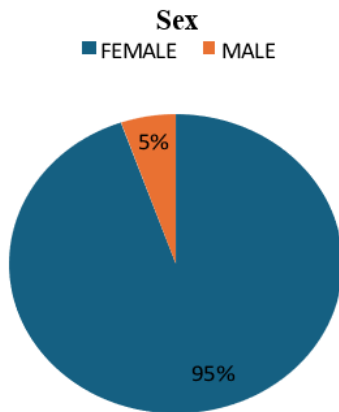
**Methodology:**

1. Study design: Institution based Retrospective study
2. Study place: SVS Medical College Department of Surgery
3. Study duration: 6 months (March 2023 to August 2023)
4. Sample size: 56 patients who under went thyroidectomy in SVS Medical College.

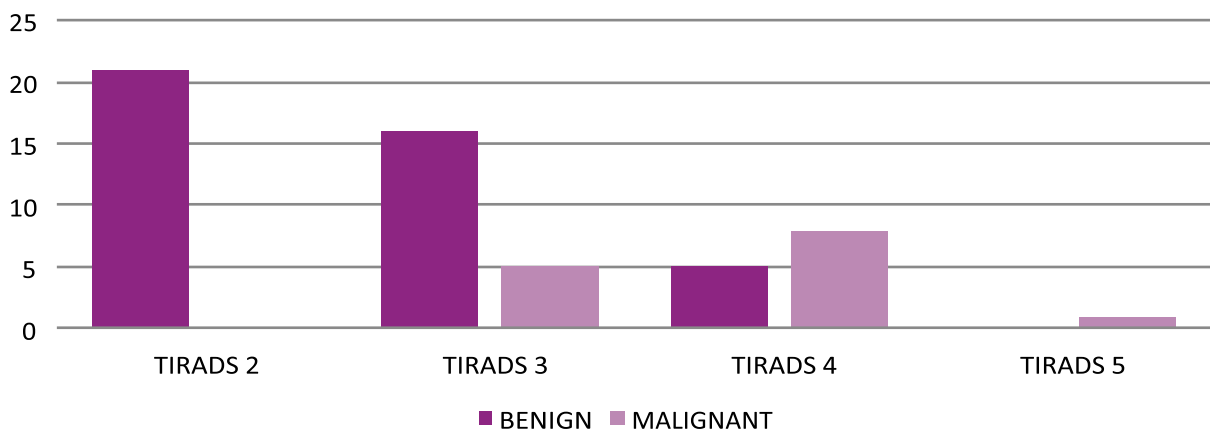
**Results:**

The study included 56 patients who underwent thyroidectomy in the past 6months. There were 53 females (94.6%) and 3 males(5.3%). Their ages ranged from 16-70yrs. All patients were evaluated based on their TIRADS Score and final Histopathological report. Out of 56 patients 30 underwent total thyroidectomy, 14 underwent right hemithyroidectomy and 12 underwent left hemithyroidectomy. 42 of 56 nodules were benign which contributes to 75% of the lesions and 14 were malignant which contributes to 25%. Most encountered categories were TIRADS 2 and TIRADS 3 which accounted for 37.5% each ,followed by TIRADS 4 which accounted for 23.21% and the least encountered were TIRADS 5 which accounted for 1.78%. All the TIRADS 2 lesions were proved to be benign on histopathology. 76.19% of TIRADS 3 lesions were benign and 23.80% of them were malignant.

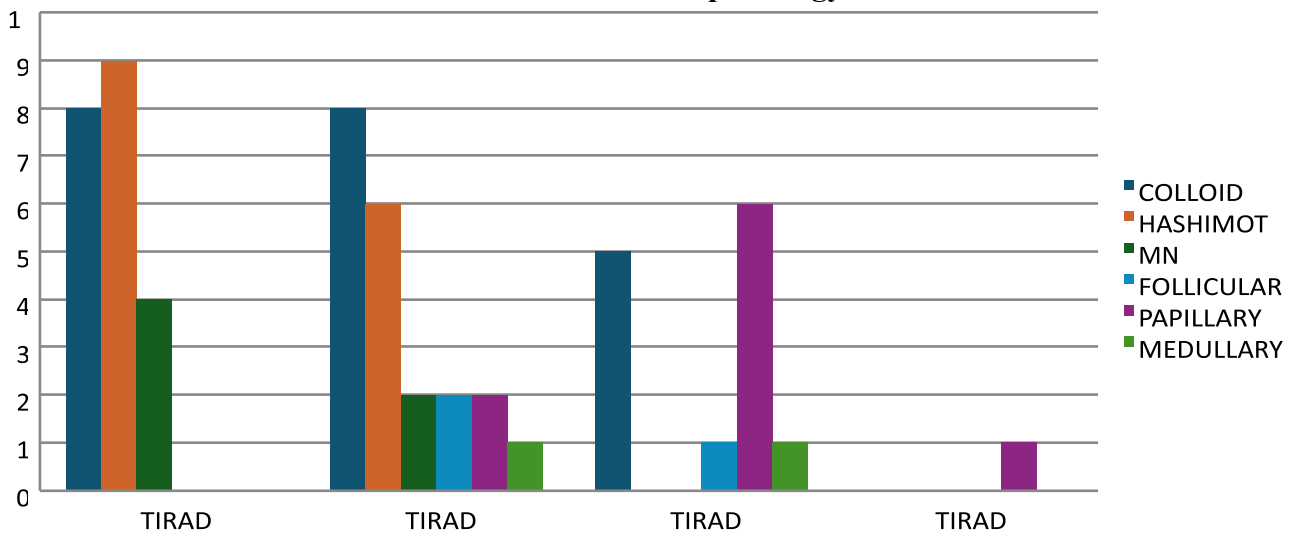
38.46% of TIRADS 4 lesions were benign and 61.53% were malignant. All the TIRADS 5 lesions were malignant.



**TIRADS in Benign vs Malignancy**



## TIRADS Vs Histopathology

**Discussion:**

- Thyroid nodules are quite prevalent and might be difficult to diagnose. Thyroid cancer incidence has more than doubled in the previous 30 years, most likely due to improved screening procedures. As a result, rapid diagnosis via a precisely designed screening strategy is critical for reducing mortality and morbidity.
- Thyroid ultrasound is an important imaging technique in the evaluation of both benign and malignant thyroid nodules.
- In this study, we looked at the ultrasound characteristics of thyroid nodules according to ACRTIRADS 2017 for 56 patients who had a neck ultrasound. 42 of the 56 nodules were benign, whereas the remaining 14 were cancerous. In our study, the prevalence of cancer was 25%. Eight of the fourteen malignant lesions found were papillary carcinomas, three were follicular carcinomas and two were medullary carcinomas. This study had more females(94.6%) than males(5.3%).
- TIRADS 2 and TIRADS 3 lesions contributed to 37.5% each followed by TIRADS 4 lesions which were 23.21% and TIRADS 5 lesions contributed to 1.78% of thyroid lesions.
- This study showed that TIRADS still can be used as a good screening tool for the prediction of malignancy in a patient presenting with a thyroid nodule.
- Specific ultrasound features such as microcalcification, hypoechogenicity, taller than wide nodule and irregular margins may help in the prediction of malignancy in a thyroid nodule which helps in further management whether to observe or proceed with further appropriate investigation such as FNAC.

**Conclusion:**

We concluded that ACR TI-RADS is a suitable and non-invasive technique for evaluating thyroid nodules in everyday clinical practice. TIRADS scoring plays an incremental role in differentiating benign from a malignant thyroid nodule due to its high sensitivity. Risk of malignancy increases significantly with higher TIRADS score. Hence USG can very well predict malignancy in a patient who is presenting with a thyroid nodule.

**References:**

1. Diagnostic value of thyroid imaging reporting and data system in thyroid nodules. International Surgery Journal Mostafa EA et al. Int Surg J. 2021 Aug;8(8):2286-2293.

2. Comparison of TIRADS [Thyroid imaging reporting and data system] with histopathology in assessment of thyroid nodules. *International Journal of Surgery Science* 2020; 4(1): 26-32
3. Osseis, M.; Jammal, G.; Kazan, D.; Noun, R. Comparison between Fine Needle Aspiration Cytology with Histopathology in the Diagnosis of Thyroid Nodules. *J. Pers. Med.* 2023, 13, 1197.
4. Comparison of TIRADS [Thyroid Imaging Reporting and Data System] with Histopathology in Evaluation of Thyroid Nodules. *International Journal of Pharmaceutical and Clinical Research* 2022; 14(12); 945-950.