

# Features Of Allohernioplasty For Postoperative Ventral Hernias In The On-Lay Position Under Conditions Of Infection In The Experiment

Akhmedov A.I.<sup>1</sup>, Tursumetov A.A.<sup>2</sup>, Zhafarov Kh.M.<sup>3</sup>

<sup>1,2,3</sup>Tashkent Pediatric Medical Institute, Republic of Uzbekistan

**Abstract.** *In order to reduce pyoinflammatory wound complications in on-lay allohernioplasty under conditions of infection, the authors experimentally used the “Hemogubka” collagen preparation in combination with the antiseptic miramistin. It has been shown that the use of a new domestic drug, a local collagen hemostatic “Hemogubka” in combination with the antiseptic Miramistin, provides a prolonged presence of the antiseptic around the mesh and thus reduces the inflammatory process and prevents mesh rejection. The results obtained allow us to recommend the developed method to be introduced into clinical practice.*

**Keywords.** *Hemogubka, hernias, on-lay,*

## 1. INTRODUCTION

The urgency of the problem of treatment of postoperative ventral (PVH), especially large and giant hernias is due to a large number of relapses, which occur in 10-60% [4], and according to some authors - in 85% of cases [1,3]. One of the options for allohernioplasty is the location of the prosthesis in the subcutaneous tissue - the on-lay method [4]. The total number of specific complications after on-lay plasty in the early postoperative period ranges from 12.5 to 41%.

The immediate results of treatment of patients using online technology showed that seromas occur in 3.2–37%, infiltrates in 1–6.9%, hematomas in 2–7.2%, necrosis of the skin and subcutaneous tissue in 1.1–4%. % [8,9,10]. Despite the fact that there are opposite opinions regarding on-lay hernia repair, in a number of cases intraoperatively it is not possible to isolate the preperitoneal space with subsequent placement of a mesh implant in it using the sublay technique. The only possible solution in this case is the use of supraponeurotic plastics.

Modern herniology is inconceivable without the use of synthetic materials for alloplasty of ventral hernias. Its use has reduced the incidence of recurrent hernias, but revealed a new problem characteristic of implant surgery - an increase in the incidence of infection in the area of surgical intervention [5,6]. At the same time, it was previously proved that a polypropylene prosthesis when implanted in infected conditions does not contribute to the delay of infection in the wound, does not worsen the conditions for its drainage and does not significantly affect the course of the wound process, which makes it possible to use it without the risk of complications [4,7].

The existing methods for the prevention of postoperative wound suppuration, developed for operations in primary sterile tissues [3,8], are not effective in the presence of an infection in them, which forms an inflammatory shaft around purulent-inflammatory foci,

preventing systemic antibiotic therapy, which further leads to wound suppuration with transplant rejection. Currently, in order to prevent postoperative wound complications in conditions of infection, a number of techniques have been proposed that involve additional implantation of drugs and materials into the plastic zone in one way or another [2,5], but all these methods have not found wide application.

Based on this, the goal of our study was to experimentally study the implementation of endoprosthetics, as well as to develop measures for implantation prevention of wound suppuration and rejection of the implant against the background of infection in the experiment.

## 2. MATERIALS AND RESEARCH METHODS

Our experimental studies were preceded by the study of the presence of a dormant infection in patients with incisional hernias, as well as the nature of the microflora in the presence of wound fistulas in the area of the hernial sac and the landscape of bacteria in the case of suppuration of postoperative wounds after allohernioplasty, hernial water in strangulated hernias. For this purpose, old ligatures removed during the operation, excised granulomas and fragments of scar-altered edges of the aponeurosis, hernial water were subjected to bacteriological examination. There are 97 samples in total. The seeding of pathogenic microflora was 47 -59% and it can be argued that most of the allohernioplasty operations take place under conditions of obviously infected tissues. In the case of suppuration of postoperative wounds, the indicator infections for wound suppuration were: *Staphylococcus aureus* (27.2%), *Staphylococcus epidermidis* (5.4%), *Escherichia coli* (45.4%) and a small number of other groups of bacteria (*Klebsiella pneumoniae*), and there was no growth in 7.3% of cases.

In the first stage, we conducted bench tests to determine the sensitivity of *Staphylococcus aureus*, *Staphylococcus epidermidis*, *Escherichia coli*, i.e. clinical strains of bacteria to the antibiotic Miramistin-0.01%. The drug has a pronounced bactericidal effect against gram-positive (*Staphylococcus* spp., *Streptococcus* spp.), Gram-negative (including *Pseudomonas aeruginosa*, *Escherichia coli*, *Klebsiella* spp.).

In our experiment, to cover the polypropylene (PP) mesh, we used a new domestic preparation "Hemogubka" collagen, developed at the Research Center of Chemistry and Physics of Polymers of the Academy of Sciences of the Republic of Uzbekistan and the State Institution "RSNPTSH named after V.Vakhidov"

In an in vivo experiment, a hernia of the abdomen was simulated on 60 sexually mature outbred white rats weighing 200-250 g under ether anesthesia.

The work was carried out in full compliance with the legislation on ("Rules for the humane treatment of laboratory animals", "Deontology of a biomedical experiment") and ethical principles established by the European Convention for the Protection of Vertebrate Animals used for Experimental and Other Scientific Purposes (adopted in Strasbourg 18.03.1986 and confirmed in Strasbourg 15.06.2006).

We have carried out this experimental study to develop measures to improve the results of allohernioplasty under conditions of infection.

In the first series of experiments, a PP mesh covered with hemogel was used for plasty on the infected wound in the onlay position (30 rats). In the second series of experiments, a PP mesh was implanted, treated with hemogel in combination with miramistin in the position on an infected wound (30 rats). Experimental animals were injected with 1 ml of a mixture of microbial suspension containing 2 billion microbial bodies of *Staphylococcus aureus* and *Escherichia coli* into the operating wound for the purpose of its infection.

The course of the wound process was studied by the duration of its individual phases on the basis of standard clinical criteria: the timing of elimination of the perifocal reaction, the nature and amount of discharge, the period of wound cleansing and the appearance of granulations, the frequency of wound suppuration with rejection of the PP mesh. The objects of morphological study were blocks, excised according to the terms of the study, the muscular-aponeurotic areas of the anterior abdominal wall with a fragment of a polypropylene mesh.

Microscopy and microphotography were performed using an optical system consisting of a Leisa CME light microscope, a DCM-500 digital eyepiece camera, and the FUTURE WINJOE software.

Statistical data processing was carried out using Microsoft Office Excel 2016 and STATISTICA 10.0 software.

Indicators are presented as arithmetic mean and its error ( $M \pm m$ ). The significance of the differences in the mean values was determined using the Student's t-test. The result was considered statistically significant at  $p < 0.05$ .

### 3. RESULTS AND DISCUSSION

Wound healing in animals of the first series of the experiment was accompanied by a progressive increase in tissue contamination with frequent attachment of a secondary infection, which was clinically manifested by the emergence of a progressive purulent-inflammatory reaction (wound suppuration).

Wound healing in animals of the second series, in which PP mesh was used for plastic surgery, treated with a hemogub impregnated with miramistin, provided a more favorable course of the wound process with the RP implant engraftment.

Below, in a comparative aspect, the results of morphological studies of the wound process are presented when using only the PP mesh treated with a hemosub and a PP mesh treated with a hemosub in combination with miramistin under conditions of infection.

In the experiment, in order to create conditions for microbial contamination, 1 ml of physiological solution containing 2 billion suspension of microbial bodies of a daily culture of *Staphylococcus aureus* and *E. coli* was injected into the postoperative wound of animals. After implantation of the PP mesh, the skin and subcutaneous fat were also tightly sutured.

One day (1st series of experiments) ( $n = 30$ ) after hernioplasty of the experimental hernia under conditions of infection, signs of a progressive inflammatory reaction in the form of increasing edema and the appearance of extensive small-point or confluent hemorrhages were found in the tissues of the surgical wound suture area. From the second day of the postoperative period, a cloudy exudate with an unpleasant odor was released between the seams.

Signs of purulent inflammation in the area of the sutured wound persisted for 6-7 days, after which a more favorable course of the wound process with the release of serous-purulent effusion was noted in 3 rats, but with healing on days 10-11, in 17 animals there was a partial dehiscence of the wound edges, which then gradually cleared of purulent-necrotic contents and by the 14th day their wounds practically healed by secondary intention, no rejection of the PP mesh was observed. In rats on days 6 - 7 of the postoperative period, the purulent-inflammatory process progressed, which led to a complete divergence of the wound edges (in 5 animals) due to its total suppuration with partial (fragmentary), but with wound healing by secondary intention with rough edges of the wound by 18 -19 days without rejection of the PP mesh, in 3 cases complete rejection of the implant occurred.

In the second series ( $n = 30$ ) of experiments for the repair of an experimental hernia, the PP implant was used in combination with HemG + Miramistin.

In the area of the sutured wound, all animals showed moderate tissue edema during the first 3–4 days; occasionally, isolated diapedetic hemorrhages were noted on the skin. In 4 observations from 2-3 days after the operation through the line of sutures, the appearance of scanty serous discharge and partial suppuration of the postoperative wound was recorded. In 22 animals, inflammation in the area of the postoperative wound was arrested on the 5th - 6th day of the postoperative period, and by the 7th - 8th day of observation, the wounds healed by primary intention. In the remaining 4 animals, at the same time, the inflammatory reaction in the area of the postoperative wound persisted, which led to a partial divergence of its edges. Suppression of the perifocal reaction and cleansing of wounds from necrotic masses was noted in these animals by days 10-11 of the postoperative period, and healing by secondary intention - on days 13-14.

Light microscopy on day 3 in the group where (Fig. 2.A) treated with "HemG" PP, but without an antibiotic (control group), there is an acute inflammatory process around the threads and in the loops of the cells with base necrosis, i.e. maternal tissue. The surrounding tissue, in the stage of reactive inflammation, is rich in segmented leukocytes, neutrophils and histiocytes. There is a vivid process of sequestration of the debris of the surrounding tissue. The surface of the filaments contains flattened macrophages and deposits of fibrinoid masses with plasma proteins. Small leukocyte infiltrates occur.

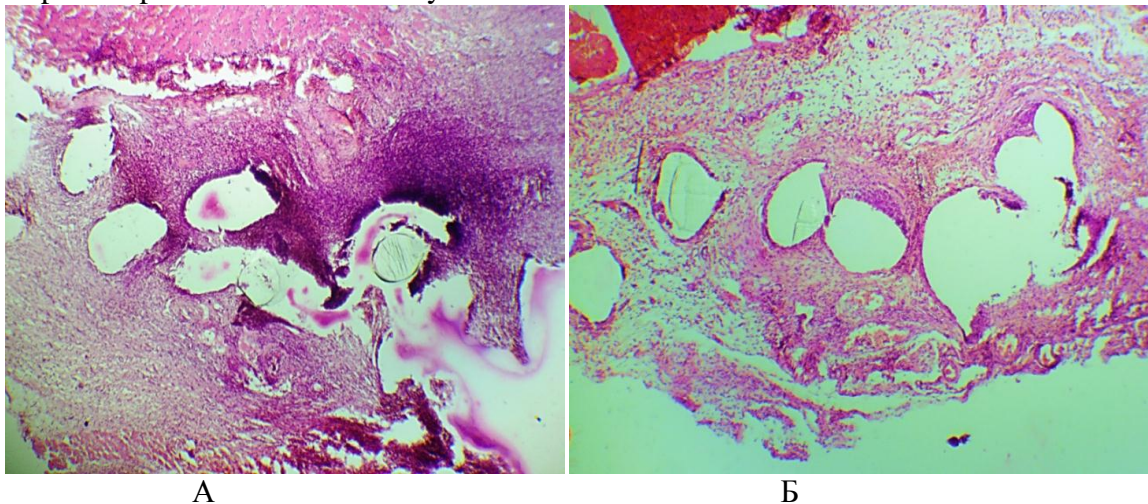


Figure 2A: On the 3rd day. Infected endoprosthesis (PP thread, mesh). Fibrinous-leukocyte infiltrate surrounding the endoprosthesis threads. Staining with Hematoxylin and Eosin. X80 magnification. Control group (without miramistin).

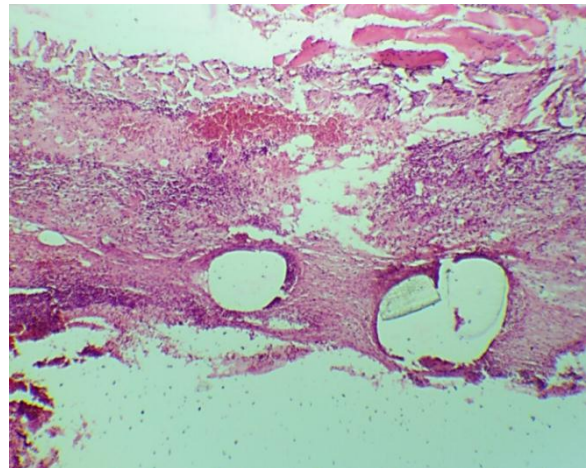
Figure 2B: On the 3rd day. Infected endoprosthesis (PP thread, mesh, HemG + miramistin). Staining with Hematoxylin and Eosin. X80 magnification. Main group.

On the 3rd day after implantation (Fig. 2B) of the endoprosthesis “PP +“ HemG ”+ Miramistin” (main group) around the threads, pronounced tissue edema, inflammatory cell infiltrate, consisting of non-resident cells was observed. Lymphocytes and neutrophils predominate in the field of view. At the same time, a large number of macrophages in the stage of phagocytosis were encountered in the immediate vicinity of the endoprosthesis threads. In the inner surface of the abdominal wall at the level of the fascia, there is an endoprosthesis enveloped in a thin capsule; there are no signs of the formation of collagen fibers.

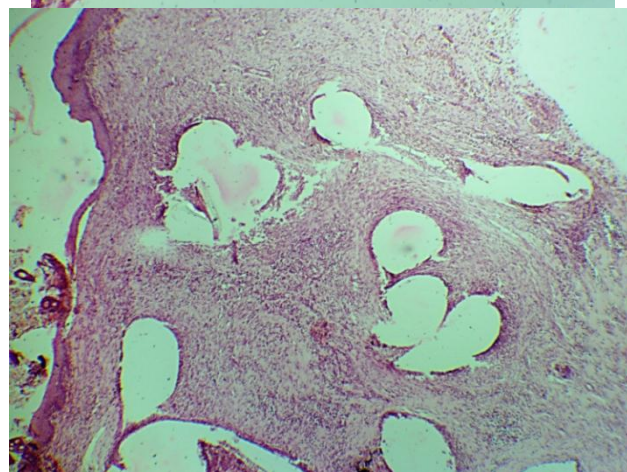
Thus, on the 3rd day, the morphological picture observed in the connective tissue fully corresponds to exudation, the severity of which is much greater than in sterile conditions. This is confirmed not only by the large area of the infiltrate, but also by the predominance of neutrophils, macrophages, and mast cells in the field of vision in the

degranulation stage, including when using endoprostheses with antibacterial properties, i.e. on the 3rd day in both groups the inflammatory-degenerative process still takes place.

When studying micropreparations using endoprostheses on the 7th day "HemG" without miramistin (control group), it was revealed that the fibrous connective tissue of the dermis is sharply edematous, the blood vessels are full-blooded, around which there were a large number of mast cells in different stages of functional activity (Fig. 3A). The endoperitoneal surface of the parietal peritoneum is totally destroyed with the disintegration of the aponeurosis. Diffuse inflammatory infiltration over the entire surface of the micro-section. There are signs of angiomasia without cell proliferation. In the area of mesh fixation, the annular rim is represented by coarse fibrous tissue with uneven vascularization and with perifocal diffuse mononuclear inflammatory infiltration with an admixture of neutrophils.



A



B

Figure 3A: Infected endoprosthesis (polypropylene thread, mesh). A fragment of the anterior abdominal wall with fragments of a mesh explant. Staining with Hematoxylin and Eosin. Magnification: X80. Control group.

Figure 3B. Infected endoprosthesis, 7 days (polypropylene thread, mesh + GemG + Miramistin). Staining with Hematoxylin and Eosin. X50 magnification. Main group.

When studying drugs in the main group (PP + HemG + Miramistin) on day 7 (Fig. 3B) around the PP mesh threads, moderate inflammatory cell infiltration was still preserved. However, the mesh prosthesis is surrounded by a capsule, the capsule is thinner in comparison with later periods, the collagen capsule is poor in proliferating cells, between the threads there is an accumulation of mesenchymal protein contents, by the nature of mucoid and fibrinoid swelling, they are loose with a mesh structure. The tissue around the implant

acquires a loose cellular structure with myxomatous foci. Around there is an accumulation of lymphocytic and histiocytic infiltrates, vascular formations are scarce.

Thus, on the 7th day in the main group, there is a moderately pronounced inflammatory reaction, there are areas of accumulation of lymphocytic and histiocytic infiltrates, neutrophilic granulocytes, macrophages, lymphocytes and plasma cells, and in the control group, signs of an acute inflammatory process and alteration persist in the section. Acute necrosis with destruction of the surrounding tissue, intensely hyperchromic membrane around the threads, uneven edema of the interstitial tissue with serous exudate.

On the 14th day, when using the PP + HemG endoprosthesis (control group, without Miramistin), the formation of a connective tissue capsule is observed. There are numerous active fibroblasts on the prosthesis threads. In the field of view, giant multinucleated cells are small, the number of dark basophilic nuclei in them varies from 4-6, and they are located along the periphery of the cells. The capsule of the endoprosthesis is without fibrous formations and is partially anesthetized, along the edges of the capsule disintegration due to infiltration with segmented leukocytes (Fig. 4A).

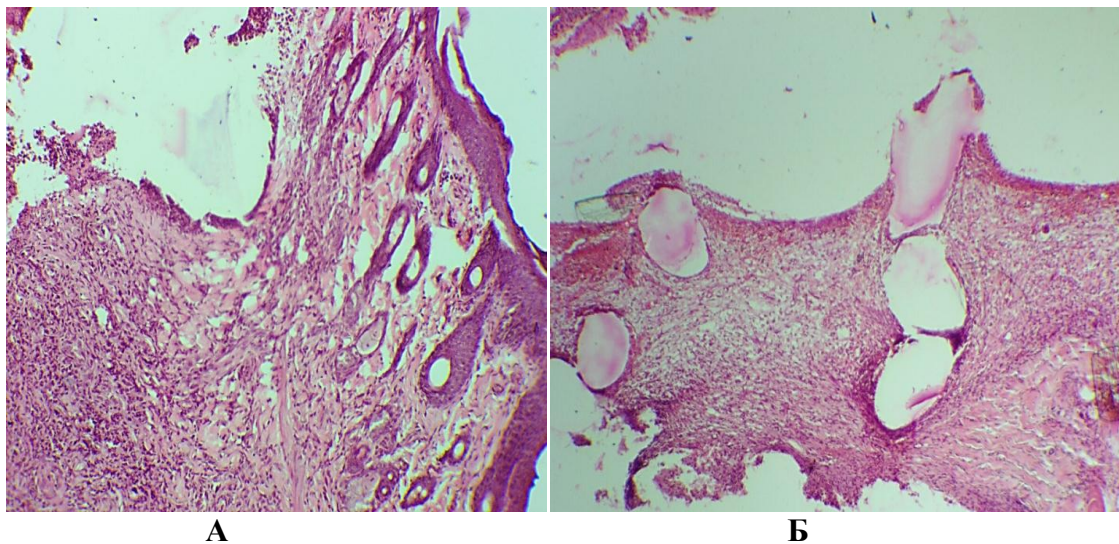


Figure 4A: Infected endoprosthesis, 14 days (PP thread, mesh + HemG). Staining with Hematoxylin and Eosin. Increase X –80. Control group without miramistin.

Figure 4B: Infected endoprosthesis (PP thread, mesh + HemG + miramistin). On the 14th day. Stained with Hematoxylin and Eosin. Increase X-100. The main group.

On the 14th day, the severity of inflammatory changes around the PP threads with HemG and miromistin (main group) (Fig. 4B) significantly decreased. The endoprosthesis was surrounded by a connective tissue capsule composed of thin collagen fibers. Inflammatory cellular infiltration persisted in the immediate vicinity of the threads. In some places, the beginning of the formation of thin collagen fibers is visible. Subsequently, the threads of the implant are surrounded by fine-fibrous connective tissue rich in cellular elements. Flattened fibroblasts are adjacent to the filament surface. Macrophages are present in the spaces between the filaments.

Thus, by the 14th day in preparations using an implant treated with HemG with miramistin, there is already a well-formed connective tissue capsule, although there is still a slight microbial contamination, and in the control group the endoprosthesis capsule without fibrous formations and partially anesthetized, along the edges of the capsule disintegration due to infiltration segmented leukocytes, infiltration, edema.

On day 21 (control group), the threads were surrounded by a thin layer of loose connective tissue, which passed into the surrounding tissue without sharp boundaries. In the

deep layers, collagen fibers were located, acquiring an ordered direction (Figure 5A). On the surface of the filaments, the cells are located more closely, forming concentric layers. Diffuse mononuclear inflammatory infiltration penetrates into the intermuscular spaces with necrosis and destruction of muscle fibers. The threads of the endoprosthesis are surrounded by loose, fine-fibrous connective tissue, rich in cellular elements, containing macrophages, multinucleated giant cells of foreign bodies and young fibroblasts.

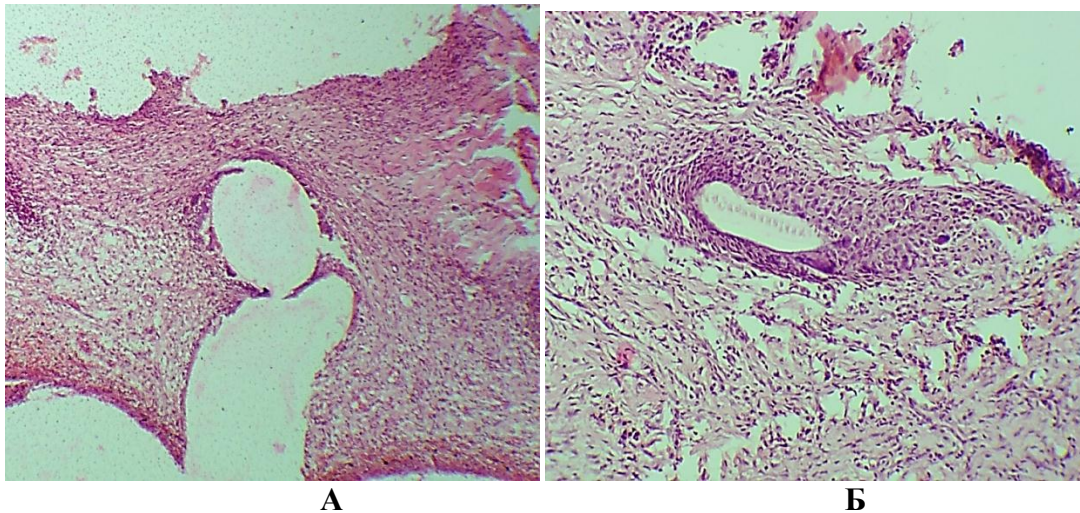


Figure 5A: Micrograph of the tissue surrounding the PP + HemG endoprosthesis without miramistin on day 21 under conditions of microbial contamination. Stained with Hematoxylin and Eosin. Increase X - 100. Control group

Figure 5B: On day 21, PP mesh + HemG + miramistin (main group).

As follows from Figure 5B, the proliferative reaction with a large number of fibroblasts located between the rare collagen fibers is disordered. They are thin, with a high content of amorphous intercellular substance. There is also an abundant formation of the vasculature in the proliferation zone of young connective tissue. The endoprosthesis thread is surrounded by a forming annular connective tissue capsule containing lymph-histiocytes, macrophages and multinucleated giant cells of foreign bodies. On the surface of the filaments, the cells are flattened, forming a continuous layer. There are cells with a chaotic distribution of nuclei, but sometimes the nuclei are larger and their number is less.

On day 21, the threads of the mesh endoprosthesis were surrounded by a fibrous connective tissue capsule. Minor inflammatory changes occurred only in the immediate vicinity of the endoprosthesis.

Thus, on day 21 in the main group, the threads of the mesh endoprosthesis were surrounded by a fibrous connective tissue capsule. Minor inflammatory changes occurred only in the immediate vicinity of the endoprosthesis. The endoprosthesis thread is surrounded by a forming annular capsule of lympho-histiocytes, macrophages and multinucleated giant cells of foreign bodies. On the surface of the filaments, the cells are flattened and form a continuous layer. In the control group, the threads of the endoprosthesis are surrounded by loose fine-fibrous connective tissue rich in infiltrates, inflammatory cell elements, containing young fibroblasts, macrophages, multinucleated giant cells of foreign bodies.

On the 30th day, in the comparison group (Fig. 6A) (PP mesh + without miramistin) (control group), an accumulation with cellular-tissue reactions was observed around the prosthesis. Basically, the process is the formation of a mature connective tissue capsule with proliferation, transformation and differentiation of cells. But inflammatory phenomena persist, namely, mild lymphoplasmacytic infiltrates with an admixture of macrophages.

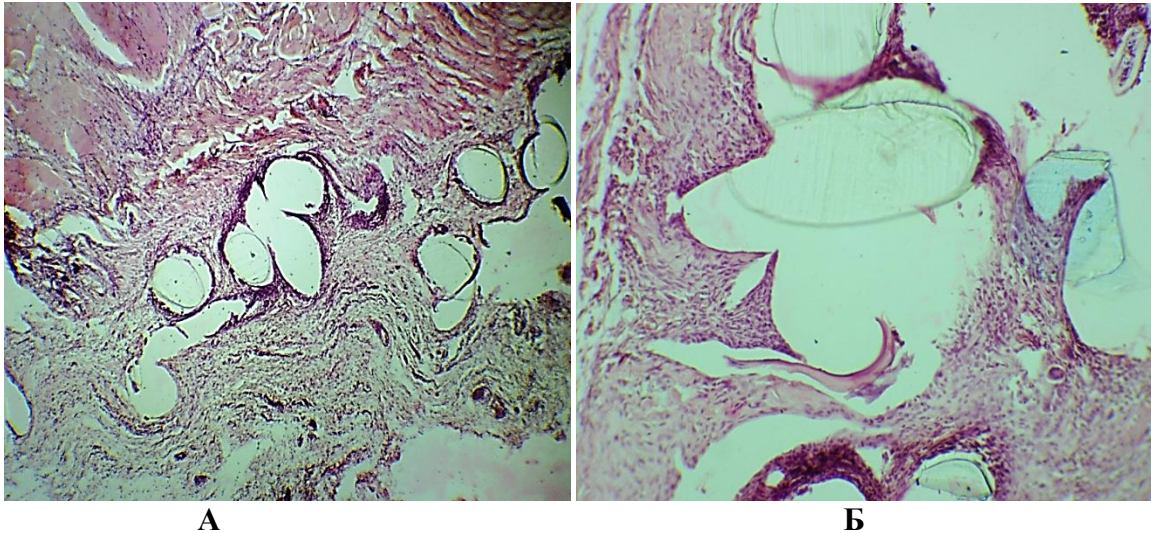


Figure 6A: PP mesh + HemG. Weak lymphoplasmacytic infiltrates with an admixture of macrophages. Stained with Hematoxylin and Eosin. X80 magnification. Control group.

Figure 6B: PP mesh + miramistin + HemG. Staining with Hematoxylin and Eosin. Magnification x-150. Main group.

Around the threads of the PP endoprosthesis there are multinucleated giant cells of foreign bodies, the formation of a powerful connective tissue capsule 2.6 mm thick is noted, from which the ingrowth of young connective tissue fibers into the cells of the endoprosthesis is noted. The capsule is represented by 5-10 layers of coarse collagen fibers, the inner layers of the capsule are concentric around the mesh implants, from the outside they smoothly pass into bundles of collagen fibers of the connective tissue.

On the 30th day, the threads of the endoprosthesis (Fig. 6B) (main group) were surrounded by a connective tissue capsule consisting of collagen fibers ordered and oriented along the endoprosthesis, i.e. a smooth connective tissue capsule is formed around the mesh thread (Fig). Cell proliferation and transformation around the explant. The formation of macrophages, mast cells, giant cells, fibroblasts and fibrocytes, and single lymphocytes is noted.

Thus, implantation of a PP with a HemG prosthesis into obviously infected tissues in all cases leads to wound suppuration, but without rejection of the implant, even against the background of a purulent-inflammatory process, which lasts up to 14 or more days. When PP implantation with HemG in combination with miramistin in conditions of infection, it suppresses the purulent-inflammatory process in the wound for 7-14 days and ensures the engraftment of the implant.

#### 4. CONCLUSION

1. The reason for the development of postoperative purulent complications in 47 -59% of patients with postoperative ventral hernias of the abdomen in cases of implantation of a synthetic prosthesis is ligature fistulas not excised during the operation and inflammatory infiltrates that occur after previous operations, which leads to wound suppuration and implant rejection.
2. Under the experimental conditions, implantation of a mesh polypropylene prosthesis, treated with a hemogap without an antiseptic in the onlay position, into obviously infected tissues in all cases leads to wound suppuration, and in some cases to implant rejection.
3. Under the conditions of infection, implantation of a mesh polypropylene prosthesis treated with a hemogloss in combination with an antiseptic miramistin in the onlay position provides suppression of the pyoinflammatory process on days 7-14 and implant engraftment.



4. The developed method of local prevention of purulent wound complications in allohernioplasty under conditions of infection, using a polypropylene mesh treated with hemogubes and miramistin, suppresses infection and inflammatory reaction in wounds and reduces the frequency of early purulent-inflammatory complications and can be recommended for clinical use.

## REFERENCES

- [1] Zarivchatskiy M.F., Yagovkin V.F.// Comparative assessment of the results of surgical treatment of large and giant incisional ventral hernias / Bulletin of surgery named after V.F. I.I. Grekov. - 2005. -№ 6. - P. 33-37.
- [2] Kornilaev P.G., Plechev V.V., Shavalaev R.R. Implantation prevention of pyoinflammatory wound complications // Surgeon. -2011.-№4.-P.12-17.
- [3] Kuznetsova V.M., Parshakov A.A., Afanasyevskaya E.V. Inhibition of adhesion of staphylococcus bacteria on mesh implants in combination with biocides (in vitro) // Antibiotics and chemotherapy. -2017. -T 62. -No. 11-12. P. 12-20.
- [4] Sukhovatykh B.S., Netyaga A.A., Valuiskaya N.M. Hernioplasty without tension with a polypropylene endoprosthesis "Esfil" in patients with strangulated abdominal hernias of large and giant sizes. Bulletin of Surgery. -2005.-№6.-P.38-41.
- [5] Cherkasov M.F., Hindikainen A.Yu., Pomazkov A.A., Sulima V.I. Experimental substantiation of the method of prevention of postoperative wound complications of hernioplasty // Modern problems of science and education. -2017.-№3.-P.17-23.
- [6] Baucom R.B., Ousley J., Oyefule O.O., Stewart M.K., Phillips S.E., Browman K.K. et al. Evaluation of long-term surgical site occurrences in ventral hernia repair: implications of preoperative site independent MRSA infection. *Hernia* 2016; 20 (5): 701—710.
- [7] Edmiston C.E., McBain A.J., Kiernan M., Leaper D.J. A narrative review of microbial biofilm in postoperative surgical site infections: clinical presentation and treatment. *J Wound Care* 2016, 25: 693—702.
- [8] Sanders D., Lambie J., Bond P., Moate R., Steer J.A. An in vitro study assessing the effect of mesh morphology and suture fixation on bacterial adherence. *Hernia* 2013; 17 (6): 779—789.
- [9] Cobb W.S., Carbonell A.M., Kalbaugh C.L., Jones Y., Lokey J.S. Infection risk of open placement of intraperitoneal composite mesh. *Am Surg* 2009; 75: 762-768.
- [10] Chevrel, J. P. Traitement des grandes eventrations medians par plastic en paletot et prothese / J. P. Chevrel // *Nouv Presse Med.* — 1979. — Vol. 8, №2. — P. 695–696.