

PECULIARITIES OF LARYNGEAL ULTRASOUND IN DIAGNOSIS OF DYSPHONIA

Kudrat Mengkobilovich Salomov

Assistant of the Department of Otorhinolaryngology, pediatric otorhinolaryngology, pediatric dentistry. Tashkent Pediatric Medical Institute. Tashkent, Uzbekistan

E-mail: salomov.qudrat@mail.ru

Shavkat Ergashevich Amonov

DSc, Professor of the Department of Otorhinolaryngology, pediatric otorhinolaryngology, pediatric dentistry. Tashkent Pediatric Medical Institute. Tashkent, Uzbekistan

E-mail: lor_amonov@mail.ru

Nigora Abdumalikovna Rasulova

Candidate of Medical Science, Associate Professor of the Department of Otorhinolaryngology, pediatric otorhinolaryngology, pediatric dentistry. Tashkent Pediatric Medical Institute. Tashkent, Uzbekistan

E-mail: Rasulova.dora@gmail.com

Dodar Rahimovna Djabbarova

Candidate of Medical Science, Associate Professor of the Department of Otorhinolaryngology, pediatric otorhinolaryngology, pediatric dentistry. Tashkent Pediatric Medical Institute. Tashkent, Uzbekistan

E-mail: dodarrakhimovna@mail.ru

Habibullo Nasratullaevich Adullaev

Candidate of Medical Science, Associate Professor of the Department of Otorhinolaryngology, pediatric otorhinolaryngology, pediatric dentistry. Tashkent Pediatric Medical Institute. Tashkent, Uzbekistan

E-mail: abdulhabib@mail.ru

Firuza Bahtiyorovna Nurmukhamedova

Candidate of Medical Science, Assistant of the Department of Otorhinolaryngology, pediatric otorhinolaryngology, pediatric dentistry. Tashkent Pediatric Medical Institute. Tashkent, Uzbekistan

E-mail: firuza.nurmuhamedova84@mail.ru

ABSTRACT

Diagnosis and treatment of diseases of the larynx remains one of the most difficult tasks of otorhinolaryngology. Often, diseases of the larynx are manifested by impaired vocal function, that is, dysphonia. Voice pathology not only affects interpersonal relationships but also creates difficulties in professional activities. This is especially true for people of voice-speech professions, whose professional suitability and longevity depend on the quality of their voice.

When dysphonia develops, patients usually consult an outpatient otorhinolaryngologist, who must diagnose and prescribe treatment.

Materials and methods: Our study included 103 patients aged 6 to 80 years. 20 patients out of 103 were in the control group, and 83 were in the main group. The study was conducted from 2019 to 2022 on the basis of TASHPTI.

Results and discussions: Upon receipt of patients' complaints, there was hoarseness of voice, difficulty breathing, fatigue during a prolonged conversation, and sore throat. The results of the study revealed organic changes in 69 patients and functional changes in 14 patients. There were organic changes in vocal fold nodules in 14 (16.9%), vocal fold polyps in 23 (27.7%), laryngeal papillomatosis in 10 (12%), and vocal cord cysts in 7 (8.4%).

Conclusion: Ultrasound is an easily accessible, non-invasive, and harmless method that allows you to obtain images in real time, with a higher resolution than cross-sectional images.

KEYWORDS: dysphonia, hoarseness, voice disorders, larynx, vocal fold polyp, vocal fold nodules, ultrasound.

INTRODUCTION

In our society, professions related to speech are becoming more common, so voice correction is a social and economic problem. For most, the voice is not just a communication tool, but also a "means of production" that gives income and self-realization. Previously, only singers, actors, and teachers were "voice professionals"; today this group includes managers of all levels, business and tourism workers, employees of insurance companies, and many others whose professional activities in our communicative age are associated with a large voice load. [1].

Laryngeal diseases are usually invariably accompanied by loss of vocal function, which may persist after therapeutic measures. In turn, to restore efficiency not only by removing the tumor or treating the inflammatory process, but it is also important to adjust the voice. Dysphonia is becoming more common as a result of insufficient attention to the problem, increasing to 65% among teachers, according to the data of access to phoniatic offices [2], and increasing to 60% among students of the Faculty of Speech from 35% in the first year to 60% at the end of the training [3].

The study of voice function begins during a dialogue with the patient during the analysis of voice and sound disorders during an outpatient session with an otorhinolaryngologist and a phonopedist. Laryngoscopy and laryngeal endoscopy with stroboscopy are used to assess the condition of the vocal folds, providing visual information regarding the anatomy and closure of the glottis. The task is to overcome the laryngeal reflex, as well as the limitations of quantitative criteria for evaluating voice function.

Ultrasound diagnostics has become widely used in clinical practice, which has led to a revolution in non-invasive imaging of organs and systems. The larynx, which was previously considered inaccessible for ultrasound examination (ultrasound) due to its tiny size and the presence of air in the lumen, was no exception [4]. The diagnostic role of ultrasound Doppler examination of the larynx has been studied in more detail in children, with the conclusion that "the potential of the method (high visibility of the results, visualization of areas of violation of the patency of the respiratory tract and mobility of the ligamentous apparatus of the larynx) is of undoubted interest" [5].

In some articles, the authors disagree on what is stained with Dopplerography: a column of air or soft tissues, and they believe that artifacts predominate in the final image since the staining goes far beyond the genuine vibrating structures.

Purpose of the study: to study the diagnostic value of ultrasound examination of the larynx in various diseases of the larynx accompanied by dysphonia.

MATERIALS AND METHODS

83 patients of various age groups who had the laryngeal disease were monitored on the basis of TashPMI from 2019 to 2022. We conducted a subjective and objective assessment of the voice for the diagnosis and clinical studies of laryngeal pathology. The examination of patients included such techniques as general otorhinolaryngological examination, laryngoscopy, ultrasound of the larynx and thyroid gland, laryngostroboscopy, endoscopic examination of the respiratory tract, and psycho-neurological examination.

Before the examination of each patient, a subjective assessment was carried out, in which special attention was paid to five main characteristics of a normal voice (Wilson D.K., 1990) [14]: absence of hoarseness, rudeness or hyperventilation; volume; voice corresponding to age, gender, and physical parameters; balance of oral and nasal resonance (absence of nasal twang); accurate pronunciation of words (mainly intonation and stress, absence of gross speech disorders).

Ultrasound examination of the larynx was performed with high-frequency (7-18 MHz) linear and sector (6.5-8 MHz) sensors (the latter for assessing the base of the tongue and the pre-laryngeal space) to obtain high-resolution images on the ultrasound diagnostic device "SG HealthCare".

Ultrasound of the larynx included median transverse, paramedially transverse, and longitudinal projections obtained in the patient's position on the back, although, in patients with difficulty breathing, a sitting position can also be used. The first projection: in the transverse plane along the midline, the scan is carried out from top to bottom, starting just above the hyoid bone, and the patient's chin should be raised up. Second and third (right and left transverse paramedian) projections: The next step is to scan in the right and left transverse paramedian positions.

All patients were divided into two groups. Group I (control) consisting of 20 patients - a healthy voice without changes or deviations from the norm. There were no complaints about persistent violations of voice function among the examined patients. Also, there was no history of diseases of the vocal apparatus. They were noted to have no clinical symptoms of any neurological or somatic diseases.

Group II (main group) consists of 83 patients aged 6 to 80 years who are on inpatient treatment or who have applied for diagnostic endoscopy and treatment of various diseases of the larynx on an outpatient basis, as well as patients whose laryngeal pathology was detected during a routine diagnostic examination.

RESULTS AND DISCUSSION

Patients mostly complained of voice changes of varying degrees of severity (weakening, hoarseness, fatigue, lack of voice).

Examination of patients in group II revealed the following diseases: paralysis of the vocal cords, paresis of the vocal cords, inflammation of the larynx, benign laryngeal tumors, and laryngeal cancer (Table 1)

Table 1.

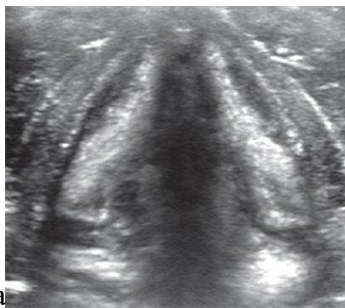Distribution of patients by laryngeal disease.

Disease	Male n=56	Female n=27	Total (%) n=83
Paralysis of the vocal cords	-	2	2 (2.4%)
Paresis of the vocal cords	-	1	1 (1.2%)
Inflammation of the larynx	3	2	5 (6.02%)
Benign laryngeal tumors	49	21	70 (84.3%)
Laryngeal cancer	4	1	5 (6.02%)

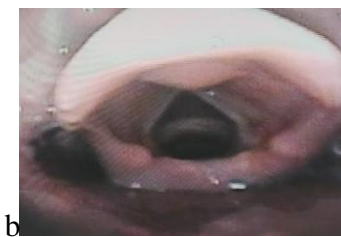In patients of group II (n=83), the cause of dysphonia was:

- vocal fold nodules - 14 patients (16,7%);
- polyp of vocal folds - 23 patients (27,7%);
- laryngeal papillomatosis - 10 patients (12%);
- vocal cord cysts - 7 patients (8,4%);
- functional dysphonia - 14 patients (16,7%);
- laryngeal cancer - 5 (6%);
- posttraumatic postintubation laryngeal stenosis, chondroperichondral genesis -2 (2,4%) patients;
- pachydermia of the interstitial space - 4 (4,8%) patients;
- granuloma –3 (3,6%)
- fibroma –1 (1,2%)

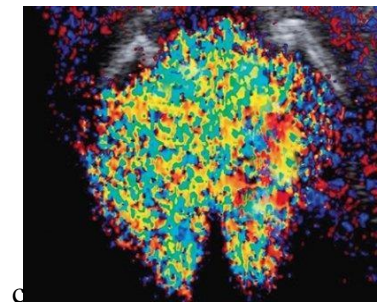
The results of ultrasound of the larynx showed that normally the cartilage and soft tissues of the larynx are usually located symmetrically and avascularly during ultrasound examination (Fig. 7, a). The vocal folds diverge on inspiration and converge on exhalation in the gray scale mode, but their internal contour is hypoechoic and blurred, which makes it impossible to judge the degree of closure with using ultrasound, as with laryngeal endoscopy (Fig. 1, b). Small marginal formations on the vocal folds are also difficult to visualize.



a
Ultrasound of the larynx in B-mode. Cross-section at the level of the vocal folds.



b
Laryngeal endoscopy



c
Ultrasound of the larynx in Doppler mode with a phonation test. Cross-section at the level of the vocal folds

Figure 1. Ultrasound and laryngeal endoscopy (normal).

When all muscle groups act in concert, with suitable scanning mode settings, the coloring of the vocal folds and elastic cone is symmetrical and synchronous during Dopplerography with phonation samples (Fig. 1, c).

Figures 2-7 show several types of diseases detected by ultrasound examination of the larynx. Contrary to expectations, the papilloma on the surface of the anterior part of the right vocal fold (Fig. 2, a-b) appears to be a hypoechoic rounded structural defect, and phonation tests show that it is inactive; on the other hand, a clot of mucus on the right vocal fold (Fig. 2, a-b) appears to be an echo positive formation that is excessively mobile during phonation; the tumor is visualized as a hypoechoic defect of irregular shape (Fig. 2, a-b), without staining in the tumor lesion during phonation tests.

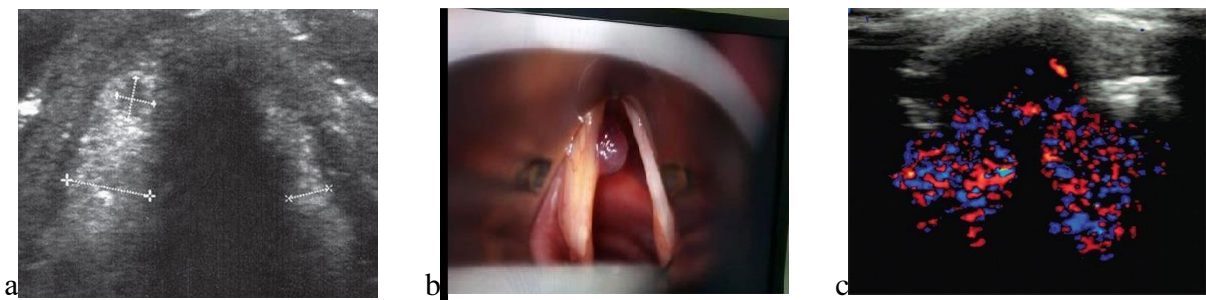


Figure 2. Polyp of the right vocal fold.

The right vocal fold is thickened, and in its anterior part there is an oval-shaped avascular hypoechoic region with a clear contour and without additional acoustic effects measuring 2.0×2.5 mm on ultrasound of the larynx in the gray scale mode. During endoscopy, a thickening of the right vocal fold was observed, as well as an anterior polyp up to 2.0 mm in size. In addition, there is less strong staining of the anterior part of the right vocal fold compared to the contralateral side during ultrasound examination of the larynx in Doppler mode with a phonation test (Fig.2).

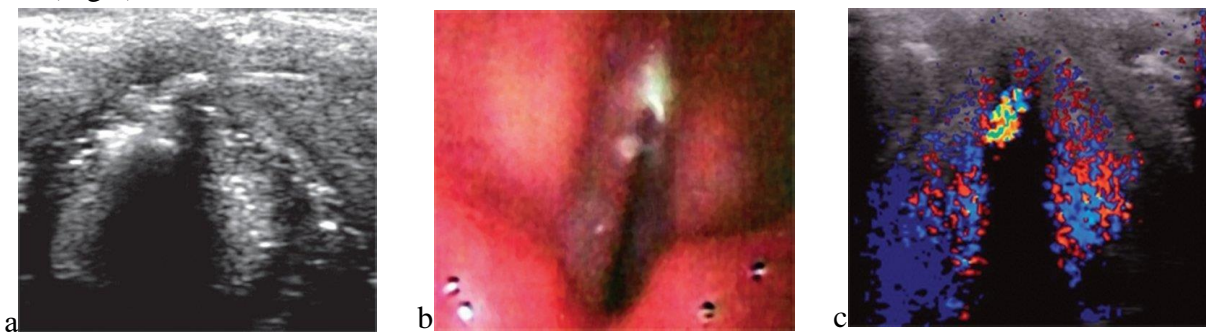

Figure 3. A clot of mucus on the left vocal fold.

Avascular formation of average echogenicity with a size of 1.5 mm is detected without additional acoustic inclusions on ultrasound examination of the larynx in the gray scale mode with a clot of mucus on the right vocal fold at the free edge of the right vocal fold in its anterior part.

During an endoscopy of the larynx, a lot of mucus is visible on the surface of the anterior part of the right vocal folds. Ultrasound examination of the larynx in Doppler mode with a phonation

test: the staining of the vocal folds proper is symmetrical, there is a local increase in vibration in the form of a brighter spot corresponding to a clot of mucus along the free border of the right vocal fold in its anterior part (Fig.3).

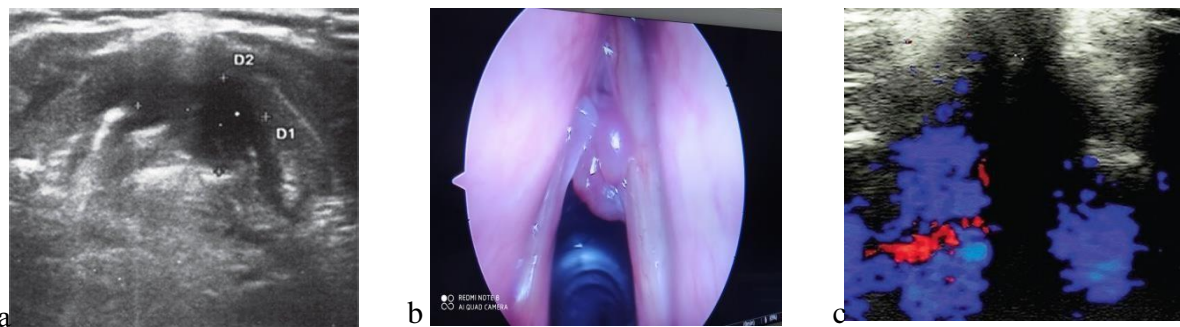
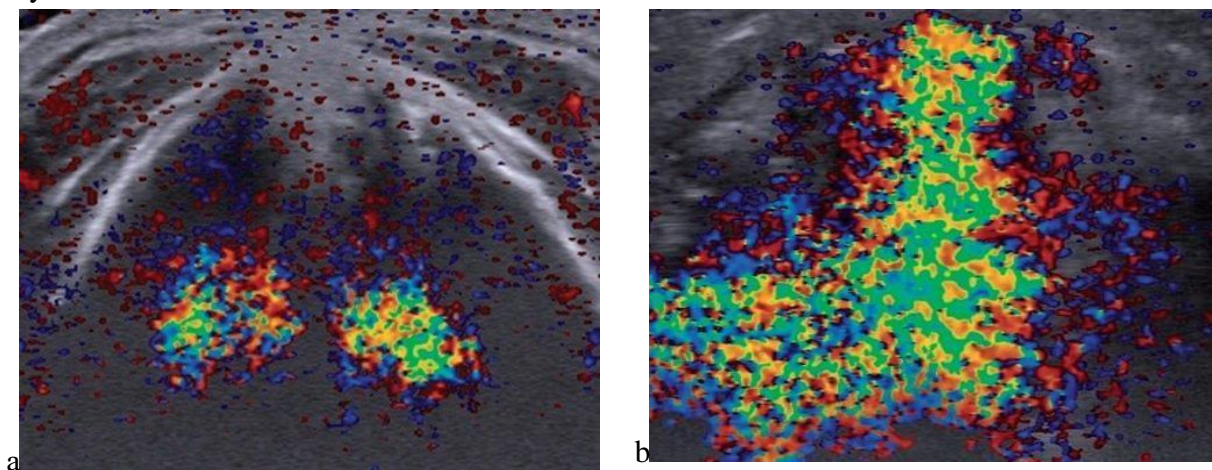


Figure 4. Laryngeal cancer

In the grayscale mode, an ultrasound examination of the larynx reveals a hypoechoic formation, mainly in the left vocal fold, but also in the area of the anterior commissure and partially in the anterior part of the right vocal fold, irregular in shape, with an uneven fuzzy contour without additional acoustic effects measuring 6 x 4 mm.

During endoscopy of the larynx, the left vocal folds are unevenly thickened with the transition to the anterior commissure and the anterior part of the right vocal fold. The defect of staining of the anterior and middle parts of the left vocal fold, as well as the anterior part of the right vocal fold, corresponds to the area affected by the tumor. Ultrasound of the larynx in Doppler mode with a phonation test: there is a defect in the staining of the anterior and middle parts of the left vocal fold and the anterior part of the right vocal fold, corresponding to the area affected by the tumor (Fig.4).

With dysphonia, there is a loss or weakening of the function of a certain muscle or muscle group (Fig. 5). As a result, the staining defect can be symmetrical or asymmetric, synchronous or asynchronous in nature.



a Symmetrical violation of the mobility of the anterior parts of both vocal folds.

b Impaired mobility of the anterior and middle parts of the right vocal fold.

Figure 5. Types of disturbance of vocal fold oscillations in functional dysphonia

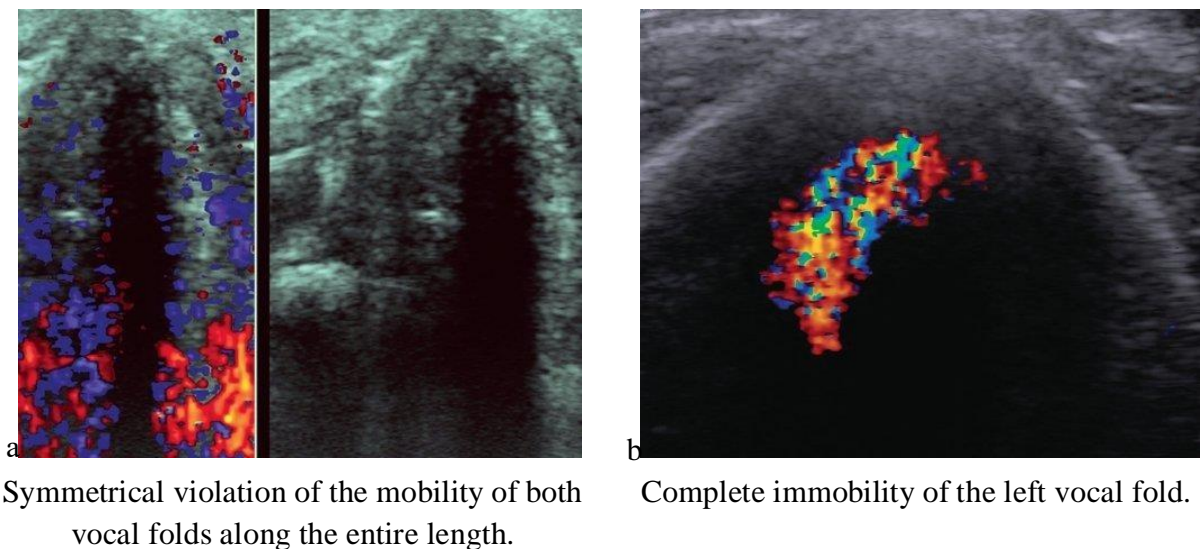


Figure 6. Types of disturbance of vocal fold oscillations in functional dysphonia

The Dopplerographic picture is accompanied by a slight shortening of the staining zone at the beginning of phonation due to the immobility of the posterior parts of the left vocal fold, which is observed in a sequential series of images obtained when viewing the clip (Fig. 7).

As phonation progresses, the vibrations of the left vocal cord decrease faster, the vibrations disappear, and only the right half of the larynx makes a sound.

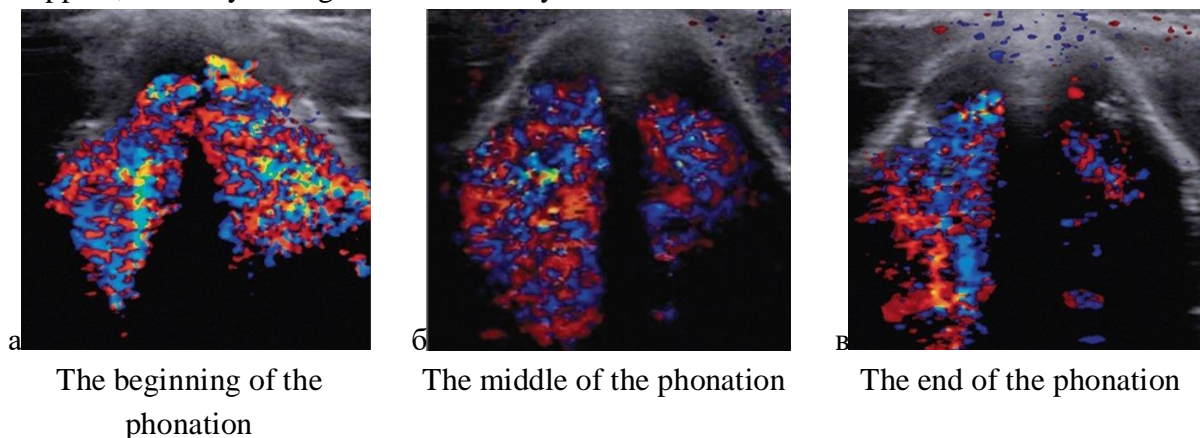


Figure 7. Sequence of images in Doppler mode with functional dysphonia

CONCLUSION

The larynx is an organ of high complexity, both functional and anatomical structure. Evaluation of this organ requires deep anatomical, histological and functional knowledge.

To perform this assessment, the doctor has at his disposal a direct clinical and laryngoscopic examination, as well as various imaging methods. Although magnetic resonance imaging (MR) and computed tomography

CT scans are currently the preferred imaging methods, but they have limitations when assessing the condition of the larynx. This is due to the possibility of spatial resolution and the fact that they only perform static evaluation.

Ultrasound is an easily accessible, non-invasive and harmless method that allows you to obtain images in real time, with a higher resolution than cross-sectional images. This modality, especially with the advent of high-resolution ultrasound, has been found to be at least

comparable to CT or MRI for the diagnosis of malignant and benign formations such as vocal nodules, polyps, cysts and papillomatosis, as well as in the diagnosis of functional disorders leading to dysphonia.

Based on all these considerations, we conclude that ultrasound is the method of choice when assessing the condition of the larynx and can play an additional role in the algorithm of laryngeal examination.

REFERENCES

1. Vasiliev A.Yu., Olkhova E.B. Ultrasound diagnostics in emergency children's practice // Guide for doctors. M., 2010. pp. 55-65.
2. Olkhova E.B., Soldatsky Y.L., E. Onufrieva.K., N. Shchepin.V. Ultrasound examination of the larynx: possibilities, prospects, limitations // Bulletin of Otorhinolaryngology. 2009. N5. pp. 9-12.
3. Olkhova E.B., Soldatsky Y.L., E. Onufrieva.K., N. Shchepin.V. Diagnostic role of ultrasound Doppler examination of the larynx in children // Ultrasound and functional diagnostics. 2006. N3. pp. 42-51.
4. Rodionova O.I. Early diagnosis and prevention of voice disorders in persons of voice-speech professions. Autoref. diss. Candidate of Medical Sciences. M., 2013.
5. Taptapova S.L., Sergeeva T.A., Ryabova S.V. Experience of voice restoration in diseases of the larynx of various genesis. M., 2003. p. 4.
6. Matta I.R., Khalan K.B., Agraval R.H., Kalvari Sr. Ultrasound laryngeal examination in the diagnosis of vocal cord paralysis: an insufficiently used tool? J Laryngol voice. 2014;4:2-5.
7. Netter F.H. Interactive atlas of human anatomy // University of Rochester, School of Medicine and Dentistry, Rochester, New York // www.netterart.com . // 2003 Icon Learning Systems LLC: Plate 75.
8. Mamatova Sh.R., Karabaev Kh.E., Namakhanov A.M. Ultrasonographic study of rhinosinusitis in children of early age. Journal of Biomedicine and Practice. 2021:63-69.
9. Vendler. Common errors in the diagnosis and treatment of voice disorders. Actual problems of phoniatria and surdology: materials of scientific and practical conf. M., 1988:16-17.
10. Amonov Sh.E., Salomov K.M. The role of gastro-esophageal reflux in the etiology of chronic diseases of the larynx. Journal of Biomedicine and Practice. 2020:869-873.
11. Lavrova E.V., Taptapova S.L., Ermakova I.I. The importance of phonopedia in the rehabilitation of patients with functional voice disorders. Bulletin of Otorhinolaryngology. 1984;4:55-59.
12. Rudin L.B. The importance of family history for the diagnosis of voice. Communicative disorders of the voice: materials of scientific and practical conf., hearing and speech. M., 2003:185-186.
13. Boikova N.E. Clinical and functional state of the vocal apparatus in patients with hypothyroidism. Russian otorhinolaryngology. 2002;1:20-21.
14. Boikova N.E., Mkrtumyan A.M. The state of the vocal apparatus in autoimmune thyroiditis. Communicative disorders of voice, hearing and speech. Materials of the scientific and practical conference. M; 2003:25-27.

15. Volkova G.V., Boikova N.E., Filimonova N.A., Tarasova T.D. Features of speech development and voice function in congenital hypothyroidism. Russian otorhinolaryngology. 2002;1:23-24.
16. Grinhalkh T. Fundamentals of evidence-based medicine. Moscow: GEOTAR-Media, 2015.
17. Vetshev P.S., Yankin P.L., Zhivotov V.A. et al. Ultrasound examination of the larynx in the diagnosis of impaired mobility of the vocal folds. Endocrine surgery. 2016;10(3):5-14.