

ORIGINAL RESEARCH

Assessment of origin of sinoatrial nodal artery in human cadaveric heart specimens

¹Dr. Mrs Megha.A.Doshi, ²Dr. Mr Shashikant.B. Mane, ³Dr.Priya.P.Roy

^{1,2}Professor, ³Associate Professor, Department of Anatomy, Krishna Institute of Medical Sciences, Karad, Maharashtra, India

Correspondence:

Dr. Priya.P.Roy

Associate Professor, Department of Anatomy, Krishna Institute of Medical Sciences, Karad, Maharashtra, India

Received: 18 September, 2022

Accepted: 23 October, 2022

ABSTRACT

Background: The sinoatrial node, or pacemaker of the heart, is a small mass of histologically distinct myocardial cells. The present study was conducted to assess origin of sinoatrial nodal artery in human cadaveric heart specimens.

Materials & Methods: 45 formalin fixed adult human cadaveric heart of either gender obtained in Anatomy department were studied. The coronary arteries were dissected and analyzed for the origin of sinoatrial nodal artery and observations were noted.

Results: Out of 45 hearts, 25 were of males and 20 were of females. Origin of sinoatrial nodal artery was from right coronary artery in 27 and left coronary artery in 18 specimens. The difference was significant ($P < 0.05$).

Conclusion: Knowing the variations in the blood supply of SA node and study of origin and distribution of sinoatrial nodal artery helps cardiologist and cardiac surgeons to understand the ischemic etiology of sinus node diseases and corrective steps needed.

Key words: sinoatrial nodal artery, Heart, Specimen

INTRODUCTION

The sinoatrial node, or pacemaker of the heart, is a small mass of histologically distinct myocardial cells.¹ It is sub-epicardially situated in the wall of the right atrium, just below the superior vena cava, at the top of the sulcus terminalis. It has no macroscopic or palpable features that indicate its location.² The artery supplying sinoatrial node mostly arises from the first segment of the right coronary artery, from its initial 1-2 cm. First branch of right coronary artery is conal artery and second branch of the RCA is sinoatrial nodal artery (SANa).³

The SANa most frequently originates from either the right coronary artery (RCA) or the left circumflex branch (LCX) of the left coronary artery (LCA).⁴ When originating from the RCA, the SANa tends to arise from the proximal segment, contrary to its origin from the LCX, which can be proximal or distal. Furthermore, origins of the artery directly from the LCA have also been frequently reported.⁵ In rare cases, extra-coronary origins of SANa, including from the aorta and the bronchial artery have been observed as well. The micro-vascularization of the SAN differs from other atrial tissue by consisting of a highly dense plexus of arterioles and capillaries.⁶ This rich vascularization facilitates adequate perfusion of

the SAN to meet its unique metabolic demands.⁷ The present study was conducted to assess origin of sinoatrial nodal artery in human cadaveric heart specimens.

MATERIALS & METHODS

The present study comprised of 45 formalin fixed adult human cadaveric heart of either gender obtained in Anatomy department. The study was approved from ethical committee of institute.

Specimens with gross congenital anomalies were excluded from the study. The coronary arteries were dissected and analyzed for the origin of sinoatrial nodal artery and observations were noted. Results of the study was compiled and assessed statistically. P value less than 0.05 was considered significant (P< 0.05).

RESULTS

Table I Distribution of specimens

Total- 45		
Gender	Male	Female
Number	25	20

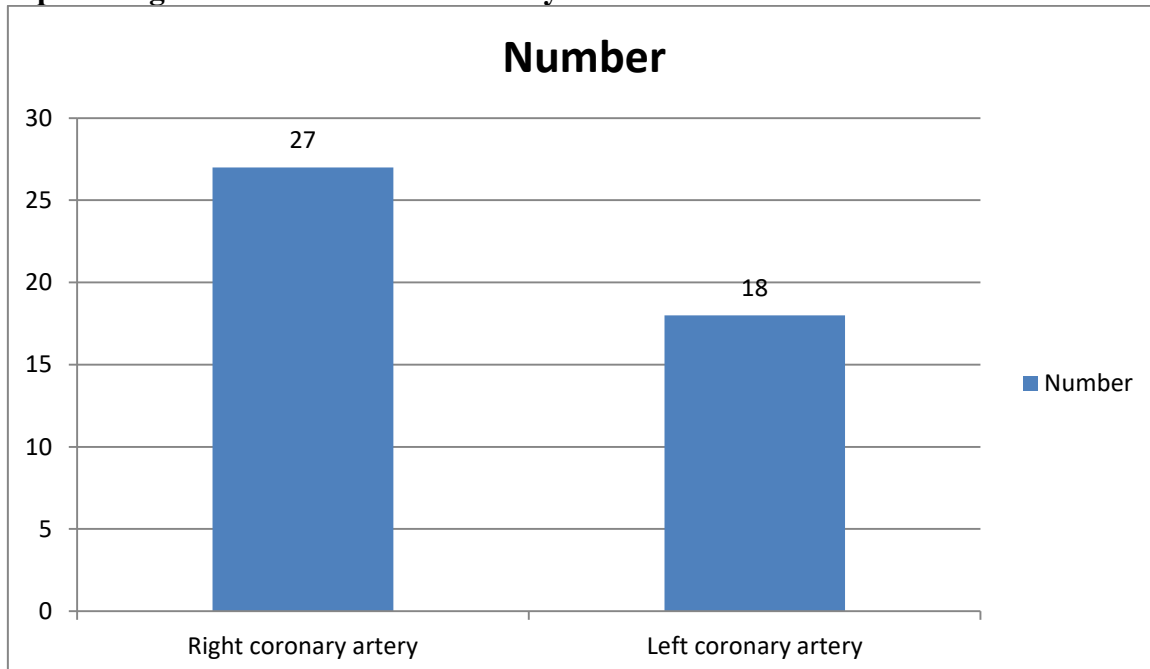
Table I shows that out of 45 hearts, 25 were of males and 20 were of females.

Table II Origin of Sinoatrial Nodal Artery

Origin	Number	P value
Right coronary artery	27	0.05
Left coronary artery	18	

Table II, graph I shows that origin of sinoatrial nodal artery was from right coronary artery in 27 and left coronary artery in 18 specimens. The difference was significant (P< 0.05).

Graph I Origin of Sinoatrial Nodal Artery



DISCUSSION

The sinoatrial nodal artery (SANa) is a branch of the coronary circulation that supplies blood to the sinoatrial node (SAN), Bachmann's bundle, crista terminalis, and the left and right atrial free walls.⁸ Due to the highly variable anatomical characteristics of the artery, a consensus has yet to be reached on its normal anatomy.⁹ Furthermore, detailed anatomical

knowledge of the artery and its variations is essential to understand both cardiac disease processes and avoiding iatrogenic injuries during interventional cardiology or cardiosurgical procedures.^{10,11} The present study was conducted to assess origin of sinoatrial nodal artery in human cadaveric heart specimens.

We found that out of 45 hearts, 25 were of males and 20 were of females. Vikse et al¹² in their study sixty-six studies (n = 21455 hearts) were included in the meta-analysis. The SANa usually arose as a single vessel with a pooled prevalence of 95.5% (95%CI:93.6–96.9). Duplication and triplication of the artery were also observed with pooled prevalence of 4.3% (95%CI:2.8–6.0) and 0.3% (95%CI:0–0.7), respectively. The most common origin of the SANa was from the right coronary artery (RCA), found in 68.0% (95%CI:55.6–68.9) of cases, followed by origin from the left circumflex artery, and origin from the left coronary artery with pooled prevalence of 22.1% (95%CI:15.0–26.2) and 2.7 (95%CI:0.7–5.2), respectively. A retrocaval course of the SANa was the most common course of the artery with a pooled prevalence of 47.1% (95%CI:36.0–55.5). The pooled prevalence of an S-shaped SANa was 7.6%.

We observed that origin of sinoatrial nodal artery was from right coronary artery in 27 and left coronary artery in 18 specimens. Sinha et al¹³ studied the anatomical origin of sinoatrial Nodal artery, from Right coronary artery or left coronary artery in indian human cadavers. Out of total 50 cases studied, sinoatrial nodal artery was originating from right coronary artery in 39 (78%) hearts while in remaining 11 (21.27%) hearts SA nodal artery was arising from left coronary artery. When it is arising from left coronary artery it is a branch of left circumflex artery rather than the main trunk. Human cadaveric hearts SA Nodal artery is originating from right coronary artery in maximum (78.0) percent population comparing with the previous studies done globally. Study of origin and distribution of sinoatrial nodal artery helps cardiologist and cardiac surgeons to understand the ischemic etiology of sinus node diseases and corrective steps needed.

In the one study which reported both diameters of an RCA arising SANa by Ortale et al¹⁴, the mean diameter at the origin (1.7 mm) was larger than that within the node (1.2 mm). In cases of SANa arising from the LCX, the pooled mean diameter was larger (1.481 mm), but this was not statistically significant. As artery diameter data may be useful for the planning of catheterization procedures. Snell's anatomy state that the artery of the sino atrial node supplies the node and the right and left atria and in 35% of individuals it arises from the left coronary artery.¹⁵

The limitation of the study is small sample size.

CONCLUSION

Authors found that knowing the variations in the blood supply of SA node and study of origin and distribution of sinoatrial nodal artery helps cardiologist and cardiac surgeons to understand the ischemic etiology of sinus node diseases and corrective steps needed.

REFERENCES

1. Richard S. Snell. Clinical anatomy be regions, 8th edition, Wolters Kluver, Lippincot Williams and Wilkins, 2008:113,114.
2. Kalpana R. A Study on principal branches of coronary arteries in humans. J Anat. Soc. India 2003;52(2):137-140.
3. N Hima Bindu. Variations in the origin and course of sinoatrial nodal artery (Abstract no. 45). Anat Soci. Ind 2006:61.
4. Oncio M. Specifics of the blood supply of the sinoatrial node. Rev Med Chir Soc Med Nat lasi. 2006 Jul-Sep;110(3):667-73.

5. Siri. A.M. A study of branching pattern and distribution of coronary arteries in adult human heart. Dissertation M.D. Anatomy, 2008.
6. Lakshmi Ramanathan. Origin of SA and AV nodal arteries in South Indians: an angiographic study. *Arq. Bras Cardiol.* 2009 May;92(5).
7. Arda Sanh Okmen. Sinoatrial node artery arising from posterolateral branch of right coronary artery: definition by screening consecutive 1500 coronary angiographies. *Anadolu Kardiyol Derg* 2009;9:481-5.
8. Chummy S Sinnatamby. *Last's anatomy, Regional and Applied* 11th Edition, Elsevier Churchill Livingston, 2006, 210.
9. Caetano AG and Lopes AC. Critical analysis of the clinical and surgical importance of the variations in the origin of sino-atrial node artery of the human heart. *Rev. Assoc. Med Brass* 1995;41(2):94-102.
10. Standring S. *The anatomical basis of clinical practice* 40th Edition, Philadelphia: Elsevier Churchill Livingston, 2008:978-980.
11. Proudfit W L, This week's citation classic. *Circulation*; 1966;33:901-10.
12. Vikse J, Henry BM, Roy J, Ramakrishnan PK, Hsieh WC, Walocha JA, Tomaszewski KA. Anatomical variations in the sinoatrial nodal artery: a meta-analysis and clinical considerations. *PLoS One.* 2016 Feb 5;11(2):e0148331.
13. Priti Sinha, Sanjeev Saxena, Satyam Khare, Shilpi Jain, Rashmi ghai, Ramkumar Kaushik. Anatomical study of origin of sinoatrial nodal artery in human cadaveric hearts. *Int J Anat Res* 2018;6(1.1):4857-4860.
14. Ortale J, Paganoti C, Marchiori G. Anatomical variations in the human sinuatrial nodal artery. *Clin (Sao Paulo).* 2006;61(6):551-8.
15. Richard S. Snell. *Clinical anatomy be regions*, 8th edition, Wolters Kluver, Lippincot Williams and Wilkins, 2008:113,114.