ISSN 2515-8260 Volume 09, Issue 07, 2022

STUDY OF VASCULAR PATTERN OF PLACENTA

Dr. PRATHIK DASARI [1], Dr. RESHMA SULTANA [2], Dr. PARIMALA SIRIKONDA [3], Dr. JANAKI VUPPALA [4]

1. Postgraduate, Department of Anatomy, Osmania Medical College, Hyderabad, Telangana.
2. Senior Resident, Department of Anatomy, Government Medical College, Siddipet, Telangana.
3. Assistant Professor, Department of Anatomy, Osmania Medical College, Hyderabad, Telangana.
4. Professor & HOD, Department of Anatomy, Osmania Medical College, Hyderabad, Telangana.

BACKGROUND

- Placenta is a discoid, choriodecidual structure, developing during pregnancy and carries vital functions of the foetus such as respiration, nutrition & excretion. Its foetal surface is covered with smooth glistening membrane (amnion) which can be easily stripped upto the umbilical cord.
- The surface of chorion thus exposed is also smooth and running in between its two layers are the branches of umbilical vessels called chorionic vessels which are most firmly secured in place.
- The well-being of the foetus is affected by many factors but a healthy placenta is the single most important factor in producing a healthy baby.
- The Placenta is the principal cause of maternal and perinatal mortality if it is abnormal, and if there is placental insufficiency, it can even lead to foetal growth retardation.
- Verma. R et al in their study stated that the birth weight of neonate was higher in magistral pattern in comparison to dispersal pattern in both sexes.
- De Paepe suggested that the magistral/mixed vascular distribution pattern may represent an important placental architectural feature contributing to the complex pathophysiology of Twin to twin transfusion syndrome (TTTS).

MATERIALS & METHODS

- A total of sixty (60) fresh and intact placentae of normal full term pregnancies were collected from Obstetrics & Gynaecology department. After thorough washing with water, vascular pattern of placentae was observed by Dissection method. The specimens were photographed, labelled and percentages of vascular pattern was tabulated.
  The Placenta can be categorized into three varieties based on their vascular pattern namely-
- **Dispersed variety-** Each umbilical artery of placenta begins at once as a series of divisions, dichotomous in nature, which fill each half of the placenta with arteries of gradually diminishing caliber. They are arranged like the spokes of a wheel.
- **Magistral variety-** Placenta has two arteries which extends almost as far as the margin of placenta before their caliber diminishes.
- **Mixed variety-** Umbilical vessels show combination of dispersed and magistral in which umbilical vessel shows successive divisions along with side branches.

RESULTS

- Out of the total of sixty (60) full term placentae obtained and examined in the Department of Anatomy during the study period, (8)13.3% of Dispersed type, (18)30% of Magistral type & (34)56.7% of Mixed type of pattern of chorionic vessels were observed.

VASCULAR PATTERN	NUMBER OF PLACENTA	PERCENTAGE
DISPERSED VARIETY	8	13.3%
MAGISTRAL VARIETY	18	30%
MIXED VARIETY	34	56.7%

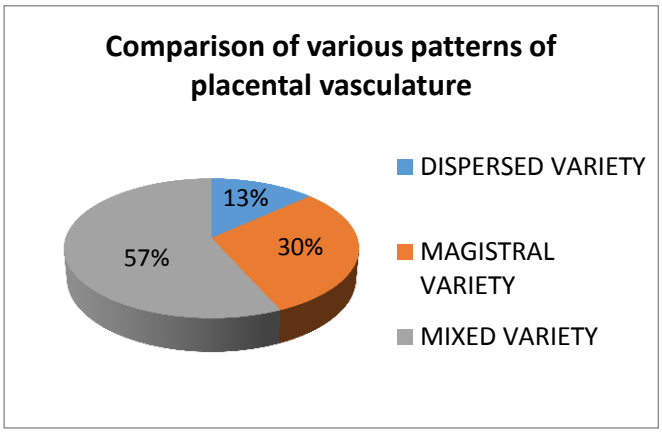

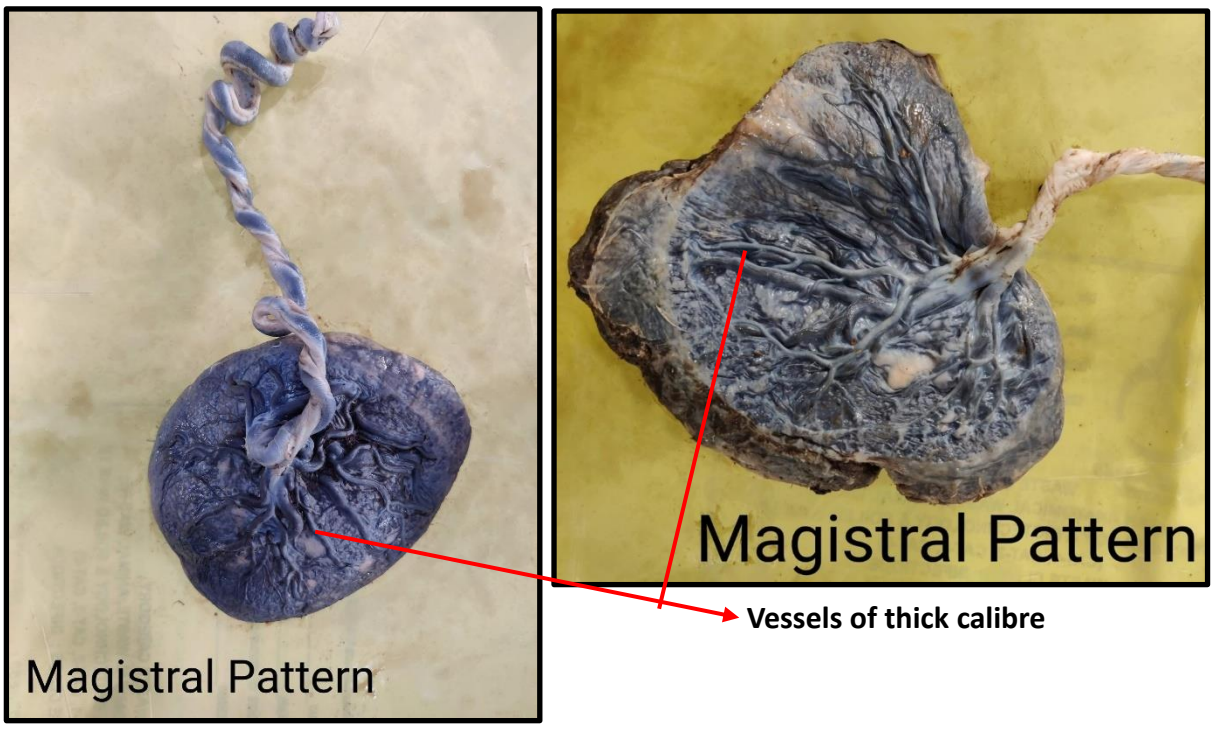

Fig.2: Magistral pattern of Placental vasculature

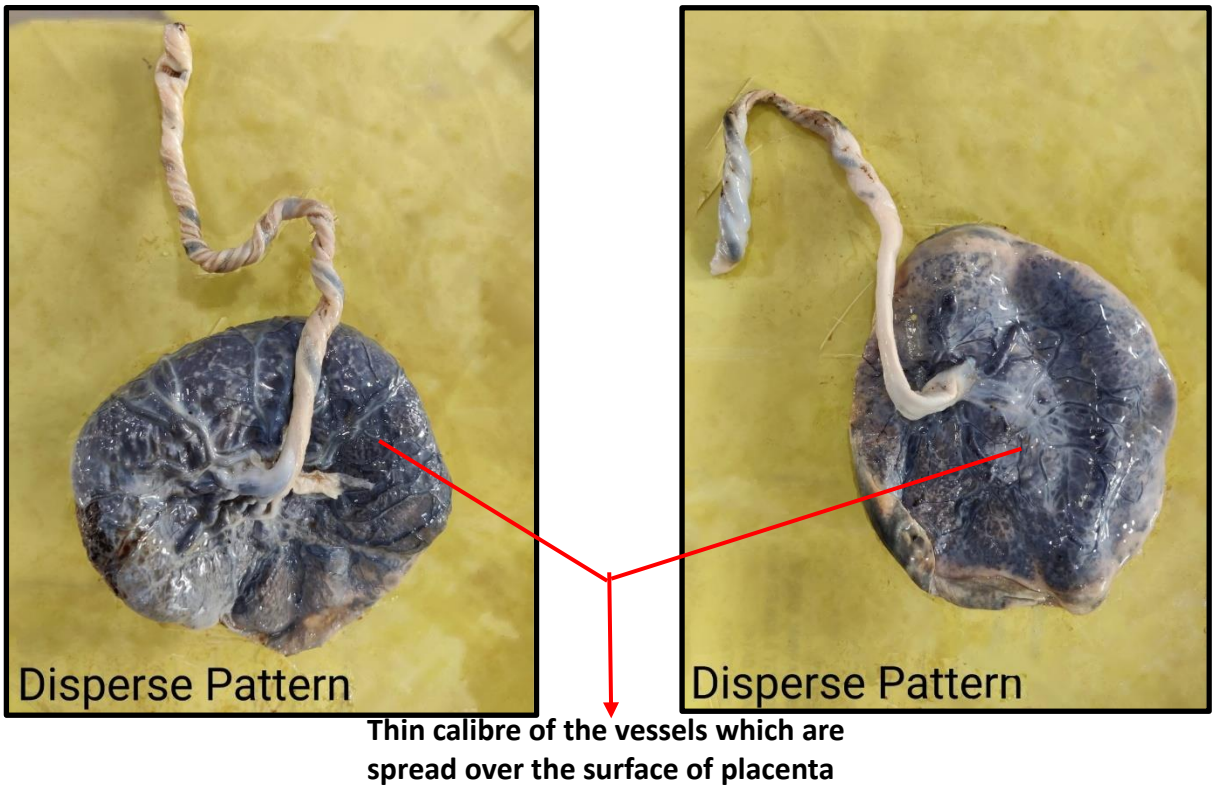

Fig.3: Disperse pattern of Placental vasculature

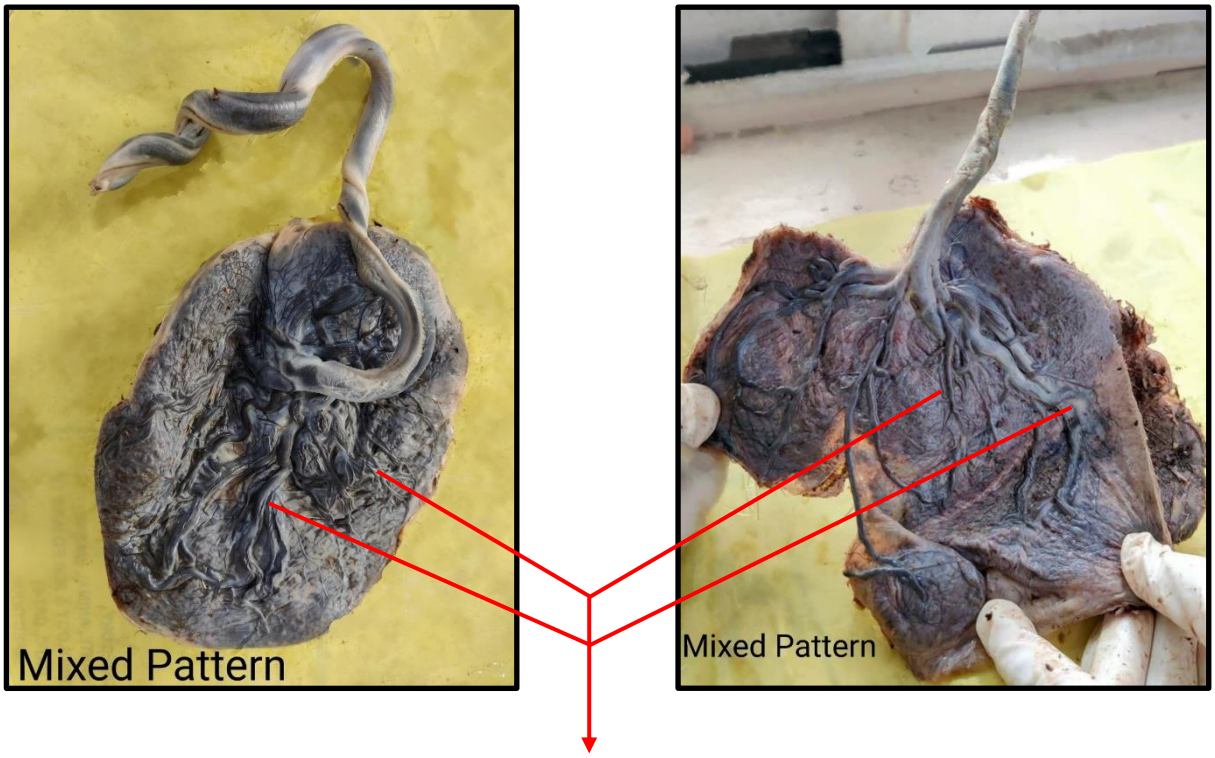

Fig.4: Mixed pattern of Placental vasculature

CONCLUSION

- In our study we found that Mixed type of vascular pattern of normal human placentae was almost four times and two times more common than that of Disperse type and Magistral type respectively.
- Variations in the vascular pattern of placenta is usually associated with foetal growth retardation, childhood hypertension and various other pathological conditions. Reduction of uteroplacental circulation results in foetal hypoxia.
- Hope our study adds knowledge to the placental vasculature and help the Obstetricians, Embryologists and Paediatricians to understand the patho-physiological mechanisms of Placenta and design the treatment plans accordingly for a better maternal and foetal outcome.

REFERENCES

- Parimala Sirikonda et al. Morphology and morphometric analysis of human placentae. Int J Biol Med Res. 2021; 12(1): 7236-7243.
- Mirbod P. 2018 Analytical model of the feto-placental vascular system: consideration of placental oxygen transport.R. Soc. open sci.5: 180219.
- Soni S, Bhardwaj K, Garg S, Mishra S.K. Study of arterial pattern of normal human placenta in reference to its shape, weight and Hyrtl's Anastomosis. Int J Med Res Rev 2017;5(05):455-461. doi:10.17511/ijmrr. 2017.i05.03.

- Patel J, Patel B, Dave R, Ram S, Bhojek N, desai J; A study of placental vascular pattern by corrosive cast in Gujarat region; NJRM 2014;5(1) : 64-71.
- Veerabhadrappa HC. Study of the vascular organization of the placenta. Int J Health Sci Res. 2013;3(4):32-35.
- M Yousuf Sarwar, Nilesh Kumar, Nawal Kishor Pandey. "Observations on vascular pattern of chorionic blood vessels of placenta". Journal of Evolution of Medical and Dental Sciences 2013; Vol. 2, Issue 44, November 04; Page: 8650-8654.
- VERMA, R.; PRASAD, R.; MISHRA, S. & KAUL, J. M. Vascular pattern of chorionic blood vessels of placenta and its correlation with the birth weight of neonate. Int. J. Morphol., 30(3):952-955, 2012.
- Wang Y, Zhao S. Vascular Biology of the Placenta. San Rafael (CA): Morgan & Claypool Life Sciences; 2010.
- Cunnigham FG et al. Abnormalities of the umbilical cord, in William's obstetrics, 21st edition, New York, MC Graw Hill Medical publishing Division; 2001: pages 23-31.
- Bhargava and Raja. Anatomy of fetal blood vessels on the chorial surface of the placenta in normal pregnancy and development. Acta Anat 1970;75:13-26.
- Crawford JM. Vascular anatomy of human placenta. Am J Obst Gynaecol 1962;54:1543-67.
- De Paepe ME, DeKoninck P, Friedman RM Vascular distribution patterns in monochorionic twin placentas.Placenta. 2005 Jul;26(6):471-5.