

Vacterl Anomalies With Anorectal Malformations

Temur Narbaev

*Ph.D., Assistant Professor of the department of Pediatric Surgery
Tashkent Pediatric Medical Institute Republic of Uzbekistan*

e-mail: temur1972@inbox.ru

Abstract: *There is no consensus among pediatricians and pediatric surgeons - on issues of early recognition of anorectal malformations and VACTERL abnormalities, preoperative management and methods of primary surgical correction; this in turn leads to the fact that many medical practitioners make a large number of diagnostic and technical errors. Which inevitably leads to unreasonable and redo operations, early disability and a decrease in the quality of life. Atresia is the absence of the anus, anal canal and rectal lumen. With so called "low form" of atresia, the blind end of the bowel is directly under the skin, and with "high form" at 1.5-2 cm higher. In this case, the rectus which has not descended can be communicated by fistula with neighboring organs. Recognition of atresia itself is not simple: with an external examination, the absence of the anus and the release of meconium through the anus, the presence of fistula. The picture of anorectal abnormalities varies depending on the type of defect and the presence or absence of combined defects and multiple defects. Depending on the "clinical dominant" of one or another concomitant pathology, the child was sent to the appropriate specialist. In some cases, in relation to the revealed lesions of the anorectal zone, it was necessary to adhere to expectant tactics in relation to the planned operation. This is what happened if information about a particular nosological unit made it possible, in general terms, to predict a not always positive outcome of the operation, and aggravating moments were also present.*

Keywords: *anorectal malformations, early diagnosis, accompanying anomalies, VACTERL syndrome.*

I. INTRODUCTION

Anorectal malformations (ARM) in children are still one of the difficult problems of pediatrics, in particular pediatric colorectal surgery. The incidence of anorectal malformations in recent years has no tendency to decrease and, according to various authors, ranges from 1 per 4000-5000 live births. Atresia of the anus without fistula occurs in 10% among patients of this group, and the frequency of rebirth of a child with a similar defect for a married couple is 1%^{1,2,3,4}. Fistulous forms are much more common than non-fistulous, accounting for 71% of the total number of anorectal malformations, of which about 50% are in girls^{5,6,7}. In the structure of congenital malformations, the share of ARM is about 7%, while they are in 9th place among all malformations according to the international registry. If we take into account the concomitant malformations like VACTERL on the part of other organs and systems in case of anorectal malformations, then the problem of establishing the "clinical dominant" of one or another concomitant pathology, the need for expectant tactics and further stages of contacting specific specialists^{8,9,10,11}.

Anorectal malformations include a wide range of congenital anomalies, affecting not only the anus and rectum, but also the urogenital tract, cardiovascular, neurological and other systems^{12,13}. The problem of early diagnosis and treatment of children with anorectal

malformations in modern pediatrics is one of the most discussed topics. An analysis of the studied scientific and medical literature showed that despite the long history of the treatment of ARM in children, there is still no consensus on the use of diagnostic methods for verification of VACTERL, and as a result, the absence of a diagnostic program^{14,15}. Despite the successes achieved in the treatment of children with congenital malformations of the anorectal zone, this problem remains far from solved, which is largely due to concomitant pathology, complex anatomy and topography of the rectal zone, and an increased sensitivity of immature tissues to surgery^{16,17}. Patients with anorectal malformations should undergo a detailed examination in the neonatal period to exclude VACTERL abnormalities. In this case, special attention should be paid to the examination of the genitourinary system, spine, spinal cord, heart. Caution should be given to patients with high forms of anorectal agenesis and with its helpless variants^{18,19,20}.

Improving the results of early diagnosis and treatment of both anorectal malformations, and concomitant malformations and developmental abnormalities from other organs and systems.

II. MATERIALS AND METHODS

The work is based on the results of an early examination and treatment of 309 children with anorectal malformation, taking into account VACTERL abnormalities. All patients have been managed in the clinic of the Tashkent Pediatric Medical Institute for the period from 2000 to 2019.

The number of children with anorectal malformation depending on gender and age is presented in table-1.

Table- 1. Children with anorectal malformation depending on gender and age

Gender	Age (in years)					Total
	0-1	1-3	4-7	8-11	12-15	
Boys	24	62	17	5	4	112
Girls	84	65	29	12	7	197
Total	108	127	46	17	11	309

The table shows that out of 309 patients, boys were 112 (36.3%), girls were approximately twice as many as 197 (63.7%). Among the examined patients, a large proportion accounted for up to 3 years - 127 (41.1%). The second most frequent patient is one year old - 108 (34.9%). 46 (14.8%) patients were from 4 to 7 years old.

Along with routine and general clinical examination methods, all children underwent: abdominal x-ray, high-pressure distal colostogram, VCUG, perineal (pelvic) ultrasound, Echo-CG, neurosonography and MRI screening tests to detect concomitant anomalies of the brain, spinal cord, cardiac and urinary system.

Depending on the results of the examination, the patients are divided according to the classification adopted by the International Conference on the Development of Standards in the Treatment of Anorectal Malformations with the participation of 25 world leading pediatric coloproctologists in the Krickenbeck (Germany) in 2005 in table - 2.

Table- 2. Number of patients with ARM according to Krickenbeck classification.

Clinical groups	Number	Rare anomalies	Number	Total
Perineal fistula	58	Rectal diverticulum	2	60

Vestibular fistula	76	Rectal atresia	2	78
Rectourethral fistula		Rectal stenosis	1	1
Prostatic fistula	10			10
Bulbar fistula	13			13
Rectovesical fistula	12	Rectovaginal fistula	26	38
Atresia without fistula	52	H-type fistula		
		Vestibular	10	62
		Vaginal	3	3
Cloaca	5	Rectal pouch	2	7
Anal stenosis	9	Other forms:		9
		-rectoscolotal fistula	2	
		-anal ectopy	6	
		-anal ectopy with stenosis	2	
		-caeco-vesical fistula (aplasia) of colon	4	
		- атрезия(аплазия)толстой кишки	3	
		-epithelial coccygeal fistula	5	
		-cleft perineum	2	
		-VACTERL-associated	4	28
Total	235		74	309

III. RESULTS

It should be noted that the collaboration of both a pediatrician and a neuropathologist, nephrologist, cardiologist, geneticist and pediatric colorectal surgeon - in the early detection and development of an algorithm for diagnosis and further treatment tactics for anorectal malformations is very important. So, for every 3 children with anorectal malformation, concomitant anomalies and malformations were found, especially in children with the VACTERL association, i.e., a combination of malformations of the esophagus (usually atresia of the esophagus), rectum (atresia of the anus), heart, kidneys, spine and limbs, and in most children, a combination of several variants of these malformations and developmental abnormalities was noted, in which an error in recognition or late, more than 1-2 days, diagnosis leads to aggravation of complications of concomitant malformations and to development incompatible with knowledge of situations.

At the initial examination of the newborn, the absence of the anus is noted. If, for some reason, the child is not examined, then often by the end of 1 day a picture of low intestinal obstruction develops. Sometimes in the presence of a so called "high fistula", meconium discharge from the urethra can be noted. With aplasia of the distal sacrum and tailbone, in some cases there is a symptom of a "sagging perineum". If only a single hole is visualized, it is a cloaca, when the external opening of the urethra, intestine and vagina open in one cavity, while the bladder drains into its upper part through the urethra, which can be shortened so that it seems to be completely absent.

The pediatrician's examination begins with an examination of the perineum and sacrococcygeal region. This helps to determine the presence or absence of the anus, to localize the unusual location of the circular anal sphincter, which is important for choosing the method of surgical correction of anomaly (in girls, the vaginal sphincter is also reduced during this test - the vulvo-anal reflex). Most often in proctological practice, the position of the patient examined on the back with the limbs moderately brought to the stomach is used.

This position is convenient not only for a detailed examination of the perineum, anus and digital examination of the rectum, but also for anoscopy, examination with a rectal mirror, when probing a fistula, a sample with a dye, when determining the anal reflex, etc.

First of all, pay attention to the condition of the skin around the anus, the inner surfaces of the buttocks and sacrococcygeal region. In this case, the condition of the skin is noted (the depth of the anal funnel is retracted or flat). Of great importance is the detection of fistulous openings, which are given a detailed description: localization, their diameter, the condition of the tissues around the external openings (inflammation or epithelization), the nature of the fistula separated, the presence of tissue seals around the openings.

During the examination of the perianal zone, an anal reflex is checked. Anal reflex is present in all healthy children. It can change, increase, decrease or completely disappear, for many reasons of a functional or organic nature. The existing parallelism between the anal reflex and the contractility of the sphincter allows you to easily and quickly obtain information about the state of tone and the strength of muscle contraction of the anal pulp. The anal reflex is checked by stroke touches of the perianal skin with a probe or non-sharp needle and assessed by the force of contraction of the external sphincter. The best condition for determining the anal reflex is created with the position of the subject on the back.

Auscultation makes it possible to hear and evaluate the intensity of peristalsis, detect signs of paresis or spastic intestinal obstruction, listen to a loud pulsation of the aorta far from the midline of the abdomen with paresis or paralysis of the intestine, and much more.

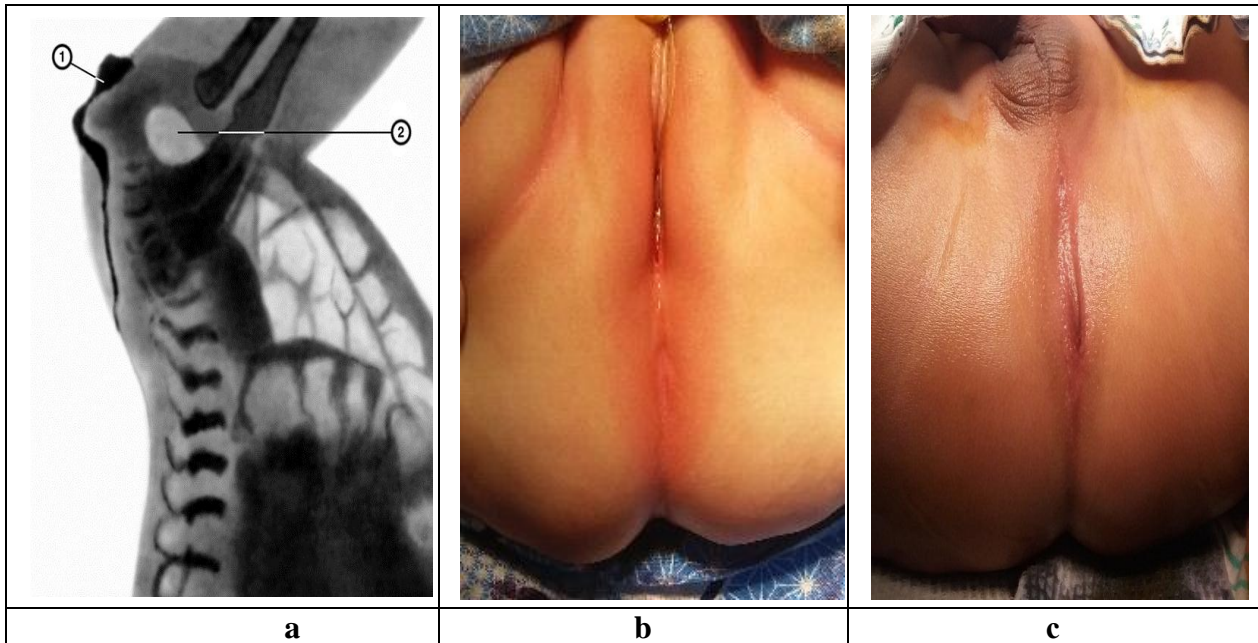
Palpation of the abdomen is one of the most valuable research methods. By palpation, tension of the abdominal muscles is established, location, size, texture and mobility, spastic contractions of intestinal loops, ascites, etc. are determined.

With a digital rectal examination in children. Severe spasm of the anal sphincter in a child, or vice versa, sphincter weakness. The anal reflex was carefully checked : visible contraction of the muscles of the external anal pulp (retraction of the anus) with stroke line irritation of perianal skin. For differential diagnosis of atresia height with fistula during examination, probing and fistula calibration are necessary.

The examination began with a radiography of the abdominal cavity. In the absence of an aperture on the X-ray, a picture of intestinal obstruction (Kloiber's arches, intestinal pneumatosis, etc.).

24 hours after the birth of the child, to determine the extent of the level of atresia, a special X-ray study was used according to Kakovich-Wangestien-Rice (Cackovic, 1924; Wangestien O.H., Rice C.O., 1930¹³). The essence of the technique is that before the study, the place where the anal opening should be, is marked with an object that delays x-rays. Then, an x-ray of the abdominal cavity and pelvis is made in the anteroposterior and lateral projections, turning the child down with his stomach and raising his pelvis. The distance between the control mark on the perineum and the blind end (gas bubble) is used to judge the height of the atresia (Fig. 1)

Fig. 1. Radiograph according to Wangensteen-Kakovich of a newborn with atresia of the rectum: a - (lateral projection): 1 - label (smear) of a radiopaque substance on the skin of the perineum; 2 - a gas bubble in the blind end of the intestine; Photo of the perineum with atresia b - in girls; c- with boys;



It is very important that this method is most reliable in the study no less than 24 hours after the birth of the baby, when the gases have time to penetrate to the blind end of the intestine, non-compliance which may be one of the reasons for the diagnostic error, and the wrong choice of the method of radical surgery.

Fistulography was carried out using water-soluble contrasts (urographin, trazograf, etc.) in age dosages; for children under one year of age 50-100ml, 1-3 years old 100-300ml, 4-7 years old 400-700ml, over 7 years old 700-1000ml under high pressure. At the same time they specified - the caliber and length of the fistula, including the outer and inner holes. In the presence of secondary megacolon phenomena, intestinal sanitation was performed through the fistulous opening with physiotherapeutic measures, after which control fistulography was performed. Reducing the diameter of the colon and the appearance of the gaustra was an indication for surgical intervention.

Ultrasound scanning (ultrasound) - the method has a number of advantages compared to X-ray examination: it does not bear radiation exposure and is used as a screening test to detect combined defects, it does not require special preparation and anesthetic management, it allows a more accurate determination of the shape of the anomaly. Ultrasonic determination of the level of atresia performed a scan of the perineum in the sagittal and frontal plane. A change in the contrast of the echo signal determined the diastasis between the skin of the perineum and the blind atresized end of the rectum filled with meconium.

If necessary, combined studies were performed (CT with NMR, X-ray with ultrasound and NMR), which allowed us to obtain valuable information about the anatomical variant of anorectal malformation, as well as concomitant malformations and anomalies of the development of other organs and systems.

IV. DISCUSSION

Using the above general clinical and diagnostic methods for anorectal malformations, almost every child managed to identify one or more concomitant malformations and concomitant congenital malformations.

The combination of fistulous forms of anorectal malformations with malformations and developmental abnormalities of other organs and systems are presented in table-3.

Table-3. The combination of anorectal malformations with abnormalities and malformations of other organs and systems.

nAnomalies by systems	Types of anomalies			Totally
Uro-nephrologic	Renal aplasia (hypoplasia) - 2 Doubling of the kidneys and ureters - 2	Congenital hydronephrosis-5 Urethral stenosis-2 UVR-4	Megaureter-3 Neurogenic Bladder-6	24 (30,4%)
Cardio-vascular	VSD-5	ASD-3	TF-3	11 (13,9%)
Gastro-intestinal	Esophageal Atresia-3	Fetal hernia-2	Ledd's syndrome - 3	8 (10,1%)
Genital	Cryptorchidism-4 Hypospadias-1	Septum vagina-2	Vaginal atresia-4	11 (13,9%)
Neurologic	Hydrocephalus-2 Microcephaly-1	Spinal hernia-4	Paresis Plegia-3	10 (12,7%)
Chromosomal	Down's Syndrome - 4	Poland's syndrome -1		5 (6,3%)
Sensoric	Malformations of the eye-2	Sensorineural Deafness-1		3 (3,8%)
Skeletal	Agenesis of the tailbone-4	Polydactyly-2	Aplasia of the limbs-1	7 (8,9%)
Totally	30	26	23	79(100%)

As can be seen from the table, from the total number of children with anorectal malformation, 79 concomitant anomalies and malformations were found. Expectant tactics for anorectal malformations were necessary for esophageal atresia, pronounced neurological status (hydro-microcephaly, organic lesions of the spinal cord) and severe malformations of the genitourinary tract (megaureter, vesicoureteral reflux, hydronephrosis) and cardiovascular system (cardiofetallo, myopathy), etc.

Of the 309 (100%) patients who entered the clinic, 154 (49,8%) children formed colostomy as a palliative stage of treatment. Performing a one-stage primary radical surgery for anorectal malformation is postponed. The reason for this was the above contraindications associated with the "clinical dominance" of concomitant associations in the form of anomalies and malformations of other organs and systems, which increased the risk of surgery and required expectant management.

Moreover, in 117 (76%) children, colostomy was formed on the first day of life, more often in perinatal centers and clinics in the community where, using early diagnostic methods, it was possible to identify concomitant associations of anomalies and malformations of other organs and systems and to avoid postoperative complications.

In 37 (24%) patients with anorectal malformation, colostomas are formed in our clinic. In this group of children, diseases of the neurological, urinary and cardiovascular systems came to the fore, which also increased the anesthetic risk and created contraindications for simultaneous radical surgery.

Thus, there is no single examination scheme and early diagnosis of anorectal malformations and the accompanying anomalies and malformations of other organs and systems. The use of classic methods from a simple clinical examination to complicated expensive diagnostic methods is sometimes not critical, there is no introduction of modern actively developing methods, the reliability of which is much higher, leads to an erroneous interpretation of the form of the defect, and as a result to unreasonable tactics of surgical correction. The consequence of this is the development of complications associated not only directly with the anorectal zone, but also the aggravation of the course of associated concomitant diseases, which leads to early disability and a decrease in the quality of life of children.

V. CONCLUSION

The correct assessment of the results of clinical and additional research methods allows us to determine not only the form of the anomaly, but also aims to identify concomitant defects: the spine, urogenital system, congenital heart defects, brain. An analysis of the data showed that 80 - 90% of defects can be accurately diagnosed in the neonatal period by routine clinical examination of the perineum, and when using instrumental methods, the diagnostic capabilities approach 100%. The study of multiple concomitant malformations and developmental abnormalities from the standpoint of pediatrics and clinical surgery will allow, based on these studies, to carry out an optimal systematization of the entire complex of birth defects, to identify ways to prevent the development of anomalies in the process of embryogenesis and adequate ways to eliminate them. Most concomitant anomalies and malformations in anorectal malformations remain unrecognized or are diagnosed with a great delay, which often leads to severe progressive structural and functional changes in various organs and systems in children with the development of disability and a decrease in the quality of life.

VI. REFERENCES

- [1] Smirnov AN, Poddubny IV. Surgical treatment of anorectal malformations in children (review of foreign literature). *Surgery*.1990;8:149-155.
- [2] Bischoff A, Levitt MA, Pena A. Update on the management of anorectal malformations. *Pediatr. Surg.* 2013; 29(9):899-904.
- [3] Puri A, Chadha R, Choudhury SR, Garg A. Congenital pouch colon: follow-up and functional results after definite surgery. *J. Pediatr.Surg.*2006;41:1413-9.
- [4] Narbaev TT, Aliev MM, Turaeva NN, Ollabergenov OT. Results of surgical treatment of anorectal malformation in children. *Med. Scientific and Innovative J. of the Eurasian J. of Pediatrics.*2019;1(1):136-143.
- [5] Aliev MM, Razumovsky AYu, Narbaev TT. Modified method of perineal proctoplasty with anorectal malformation in children. *Russian J. Pediatr Surg., Anesthesiology and Intensive Care.* 2019;9(3):33–42
- [6] Degtyareva YuG. Congenital malformations of the anorectal region. Monograph; Rep. scientific and practical Center of *Pediatr. Surg.- Minsk*, 2017.180. ISBN 978-985-581-237-2.
- [7] Salamov KN. Anorectal anomalies in combination with malformations of other organs and systems. *Probl. Proctology MIIOI Research Institute of Proctology M.* 1989;8:51-54.
- [8] Holschneider AM. *Anorectal Malformations in Children: Embryology, Diagnosis, Surgical Treatment, Follow-Up*, Heidelberg: Springer 2006.269-281.

- [9] Aliyev MM, Narbaev TT, Dzhalalov MD, Kholmetov ShSh. Concomitant anomalies and malformations with anorectal malformation in children. *Scientific and practical J. Pediatrics.*2017;3:6-9.
- [10] Lautz TB. Vacterl associations in children undergoing surgery for esophageal atresia and anorectal malformations: Implications for pediatric surgeons. *J. Pediatr Surg.* 2015;50(8):1245-50.
- [11] Mittal A, Airon R, Magu S, Rattan K, Ratan S. Associated anomalies with anorectal malformation (ARM). *The Indian J. of Pediatrics.*2004;6:509 - 514.
- [12] Krasovskaya TV, Kobzeva TN, Smirnov AN, Novozhilov VA. A program for examining patients with malformations of the anorectal region. *Vopr. protection of motherhood and childhood.*1989;8:25-28.
- [13] Levin MD. Standardization of x-ray examination of the colon and anorectal zone / MD Levin, YuG Degtyarev, VI Averin, JF Abu-Varda, TM Bolbas // *News surgery.*2013;21(4):90–98.
- [14] Karsten K, Voiding Cystourethrography in the Diagnosis of Anorectal Malformations. / Karsten K, Rothe K, Märzheuser S. // *Eur J Pediatr Surg.*2016;26(6):494-499.
- [15] Cuschieri A. Anorectal anomalies associated with or as part of other anomalies. *Am. J. Med Genet.*2002;110:122-130.
- [16] Lenyushkin AI, Chuplak II. Problems of combined proctourogenital pathologies in pediatric surgery. *Pediatric Surgery.*2001;1:12-16.
- [17] Narbayev TT, Tilavov UKh, Turaeva NN. Rehabilitation of Children with Anorectal Malformations. *J. Progressing Aspects In Pediatrics And Neonatology.*2018;1(5):1-5.
- [18] Ivanov PV, Kirgizov IV, Baranov KN, Shishkin IA. Stage treatment of anorectal malformations in children. *Med. Bulletin.*2010;3:88-89.
- [19] Ivanov VV, Axelrov VM, Belkovich SV. Colostomy as the first stage of surgical correction of malformations of the anorectal region in newborns. *Pediatric Surgery M.*2007;2:6-8.
- [20] Holschneider A, Hutson J, Peña A, Beket E, Chatterjee S, Coran A. et al. Preliminary report on the International Conference for the Development of Standards for the Treatment of Anorectal Malformations. *J. Pediatr. Surg.*2005;40: 1521—6.