

Study of Physiological and Histological effects of Mono Sodium Glutamate (MSG) on thyroid gland and Liver in Male Rats

Noor Ali Zayed^{1*}, Noori Mohammed Luaib², Raghad Harbi Mahdi³

¹ Biology Department, College of Science, Mustansiriyah University, Baghdad, Iraq

² Biology Department, College of Science, Mustansiriyah University, Baghdad, Iraq.

³ Biology Department, College of Science, University of Baghdad, Baghdad, Iraq.

Background

Food additives are used in practically all sorts of food preparation and processing to improve the quality of the food that we eat. MSG, or glutamic acid sodium salt, is one of the most abundant naturally occurring non-essential amino acids. Glutamic acid is a key component of several proteins, including fish, meat, milk, and many vegetables, and it is essential for human metabolism. The purpose of this study was to look into the effect of mono sodium glutamate on thyroid weight and hormone (T3, T4, TSH) as well as liver weight and enzymes such as GOT, GPT, total bilirubin, and ALP in male rats.

Method : This study used 54 male rats divided into nine groups, each with six rats, Group 1, 2, and 3 (control group); the experimental groups (Group 4, 5, and 6) received intra-peritoneal doses (60mg/kg) of MSG for (2,4,8) weeks. Other experimental groups (Groups 7, 8, and 9) received intra-peritoneal doses (30 mg/kg) of MSG for (2,4,8) weeks.

Result: increased doses of MSG and treatment time caused, Long term exposure to MSG with different doses increased in liver weight and enzymes (GPT, GOT, total bilirubin and ALP) serum levels, also increase in thyroid weight as well as TSH and decrease in thyroid hormone (T3, T4) serum levels. We demonstrate indication that MSG administration to male Wistar

rats altered thyroid weight and hormone , also caused damage in liver and altered biochemical parameters. Histological thyroid section showed very wide area of damage (necrosis) and few follicles with colloid material but no scalloping (non- functioning)and lined by flat epithelial cells , and liver section showed dispersed focal area of hepatocyte cell damage sinusoid dilation .

Keywords: MSG; Thyroid weight, T3 , T4, TSH, Liver weight ,liver enzyme , GPT, GOT, ALP ,Total bilirubin ; Rats

1 Introduction

Food additives are chemical chemicals that are purposely added to food to preserve, sweeten, color, and flavor it. MSG (mono sodium glutamate) is commonly used as a flavor enhancer or food ingredient. MSG is the sodium salt of glutamic acid, a non-essential amino acid (IFIC, 1994). MSG is composed of 78% glutamic acid, 22% sodium, and water (SAMUELS,1999). Glutamate is found in a wide range of foods, and because of its flavor-enhancing properties, glutamate is frequently added to foods, usually as a purified monosodium salt known as monosodium glutamate or MSG (Zia *et al.*, 2014). The liver is the largest internal organ in the body, located beneath the diaphragm and directly above the stomach on the right side of the abdomen. The liver is important in the metabolism of nutrients as well as some xenobiotics such as food additives and environmental toxins (Giannini *et al.*, 2005). Excessive MSG consumption can cause liver damage (Ortiz *et al.*, 2006) .

The liver is the mammalian body's biggest gland. And the liver plays an , important role in the detoxification of harmful chemicals like alcohol, which produces free radicals that aid in the alcohol-mediated oxidative stress (Nordmann *et al.*, 1992). Gluconeogenesis, conversion of carbohydrates and proteins into lipids, glycogen storage, phospholipid, lipoprotein, and cholesterol synthesis, and fatty acid oxidation

are also involved in the biosynthesis and release of non-essential amino acids and plasma proteins .

The negative effects of MSG consumption may be rising. Many authors have indicated that eating small doses of MSG once a week without experiencing reactions, although experiencing reactions when similar goods were consumed uncooked for two or three days. The current study sought to evaluate the effects of MSG toxicity on the liver cells of male rats. Many studies have found that MSG (2mg/gm of body weight) produces changes in the liver parenchyma of mice, including dilated sinusoids, inflammatory cells, and pyknotic nuclei (BHATTACHARYA *et al*) .

2 Materials and methods

2.1 Animals

Adult male Sprague-Dawley albino rats (*Rattus norvegicus*), age 2-3 months, body weight 200-225 g. The animals were collected from the national center for drug control and research (NCDCR)/ministry of health. They were subsequently moved to the animal house at AL-Mustansyria University's college of science. Male rats were housed in clean, segregated plastic cages with metal network covers in a climate-controlled environment with 22-25 degrees Celsius, 60% humidity, 12 hours of light and darkness, and free access to food and water.

2.2 experimental design

In this study, 54 male rats were randomly separated into three groups and treated for two weeks, one month, and two months

Each groups had six rats :

Groups 1,2,3 (control groups) got intraperitoneal injections of distilled water for varying lengths of time (2 weeks, 1 month, and 2 months)

Group 4,5,6 (experimental groups) . received intraperitoneal injection dose (60mg/kg) for various periods (2 weeks, 1 month, and 2 months)

Group 7,8,9 (experimental groups) : received intraperitoneal injection dose (30mg/kg) for various periods (2 weeks, 1 month, and 2 months) .

2.3 Preparation of Monosodium Glutamate solution

1. Group (1) injected
with 30 mg/kg of Monosodium Glutamate (Low dose) in the intra peritoneal rout.

The solution prepared by dissolving 60 mg of Monosodium Glutamate in 10 ml of distilled water (Alalwani , 2014) .

2. Group (2) injected
with 60 mg/kg of Monosodium Glutamate (High dose) in the intra peritoneal rout.

120 mg of Monosodium Glutamate were dissolved in 10 ml of distilled water to make the solution.

2.4 Collection of Blood Samples

At the end of each experiment, the animals were weighed and completely anaesthetized with diethyl ether for several minutes before blood samples were obtained via heart puncture and collected in heparinized and non-heparinized tubs for hormonal, biochemical and hematological, immunological, and molecular examination. 4 ml of blood was drawn from each rat to obtain sera (0.5-1.0) ml, which were separated by centrifugation at 3000 rpm for 5 minutes and stored at -20oC until analysis. The rats' organs, liver, thyroid gland, liver, kidneys, and testes were removed, then rinsed with normal physiological saline 0.9% (NaCl) to remove blood, blotted with filter paper, weighed, and preserved in the fixative solution neutral buffered 10% formalin.

2.5 Thyroid hormone

2.5.1 T3 hormone

It was represented by enzyme –lined immunosorbent assay (ELISA) kit for quantitative determination of concentration of T3 according to mybiosource/USA

2.5.2 T4 Hormone

It was represented by the enzyme–lined immunosorbent assay (ELISA) for quantitative determination of concentration of T4 according to mybiosource/USA

2.5.3 TSH Hormone

It was represented by the enzyme–lined immunoassay tests (ELISA) for quantitative determination of concentration of TSH according to mybiosource /USA

Histopathological Study

The Preparation for histological sections was performed according to the method of (Humason, 1979)

2.6 Biochemical analysis : (Flexor – EL80/ company : Vitalab/ south Africa)

The enzymatic parameters of liver function were detected by used automatic biochemical analyzer (company : Vitalab/ south Africa)

2.6.1 Functions of the Liver

2.6.1.1 Measurement of the Level of ALP

According to (Vitalab/South Africa), ALP was tested using an international federation of clinical chemistry IFCC technique for determining serum alanine aminotransferase levels in serum.

2.6.1.2 Measurement of the Level of GOT

According to (Vitalab/South Africa), GOT was tested using an international federation of clinical chemistry IFCC technique for determining serum alanine aminotransferase levels in serum.

2.6.1.3 Measurement of the Level of GPT

According to (Vitalab/South Africa), GPT was tested using an international federation of clinical chemistry IFCC technique for determining serum alanine aminotransferase levels in serum.

2.6.1.4 measurement of the level of Total Bilirubin serum (company : Vitalab/ south Africa)

According to (Vitalab/South Africa), TBS was tested using an international federation of clinical chemistry IFCC technique for determining serum alanine aminotransferase levels in serum.

2.7 Statistical Analysis

The SAS (2012) program was used to examine the effect of several factors (MSG concentration and duration) on research parameters. In this study, the least significant difference -LSD test (ANOVA) was utilized to compare means.

RESULT:

Thyroid weight and functions

2.8 Thyroid gland

2.8.1. Thyroid weight

. Figure (1) depicts the results of MSG impacts on thyroid weights at various doses. The animal rats exposed to MSG for 2 weeks demonstrated a high significant increase ($p \leq 0.05$) in thyroid weight of treated rats with different dose (30 and 60) mg/kg (0.205 ± 0.01), (0.261 ± 0.02) respectively in comparison to control groups (0.171 ± 0.01)mg, as well as a high significant increase ($p \leq 0.05$) in thyroid weight exposed to MSG for 4 weeks with different dose (30 and 60) mg/kg (0.230 ± 0.01), (0.368 ± 0.01)mg respectively In addition, rats exposed to MSG for 8 weeks showed a substantial rise ($p \leq 0.05$) in thyroid weight (0.260 ± 0.02), (0.538 ± 0.01)mg compared to control groups (0.178 ± 0.01)gm

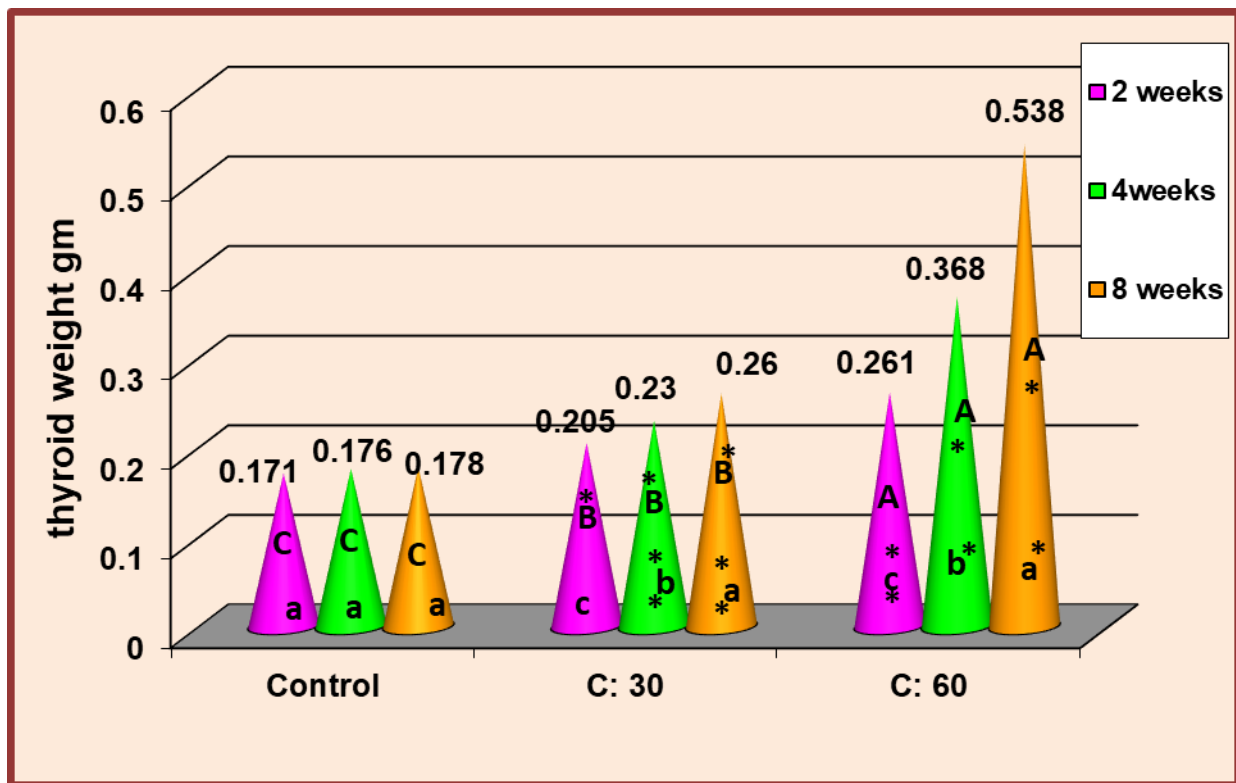


Fig. 1: Effect of different concentrations of MSG (30,60) gm/kg on thyroid weight of rats with different periods of time (2,4,8) weeks in comparison with control groups.

* significant increase ($P \leq 0.05$).

(A,B,C) Using days as a fixed factor and concentrations as a variable factor, represent the meaningful difference between groups.

(a,b,c) show the significant difference between groups when concentrations are fixed and days are variable

2.8.2 Thyroid functions

The statistical analysis of the current study for the effect of MSG on thyroid hormone functions included TSH, T3, T4 figure (2),(3)(4) reveals that :

TSH values increased significantly ($p < 0.05$) at different MSG doses (30 and 60 mg/kg) for different durations (2, 4 and 8) weeks (7.47 ± 0.11), (11.97 ± 0.41), (8.54 ± 0.08), (17.38 ± 0.40), (10.67 ± 0.04), (23.48 ± 0.52) in comparison to control groups (6.30 ± 0.08), (6.52 ± 0.1) .

$p < 0.05$) in serum level of T3 (ng/ml) \geq There was a high significant decrease ($p < 0.05$) of different dose (30 and 60) mg/kg (2.08 ± 0.02), (1.59 ± 0.02) (ng/ml) respectively when exposed to MSG for 2 weeks in comparison to control groups (2.96 ± 0.04) (ng/ml), also there was a high significant decrease ($p < 0.05$) in level of T3 for 4 weeks at both dose (30 and 60)mg/kg .In addition, there was a substantial drop in serum T3 levels at doses (30 and 60 mg/kg) in 4 weeks (1.89 ± 0.03), (0.246 ± 0.04) ng/ml in compare to control groups (2.17 ± 0.04) ng/ml figure 3 .

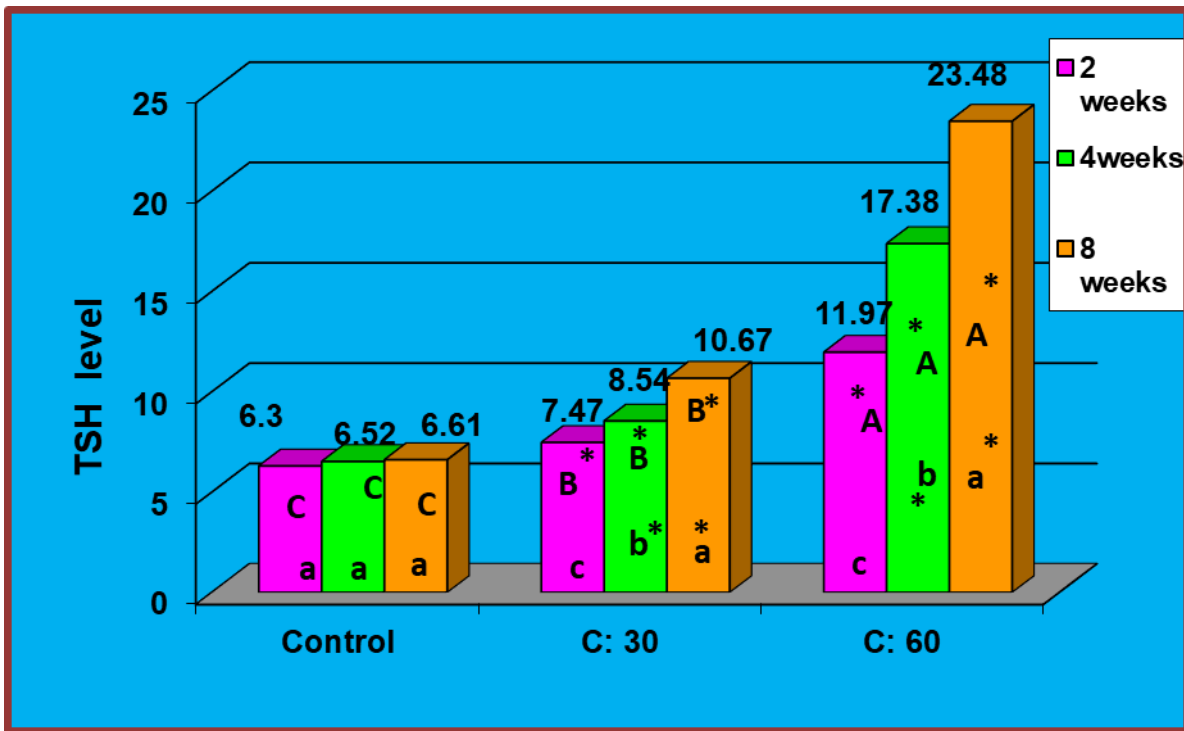


Fig. 2: Effect of different concentrations of MSG (30 ,60)gm/kg on T3levels of rats with different periods of time (2,4,8) weeks in comparison with control groups.

* high Significant increase ($P \leq 0.05$).

(A,B,C) Using days as a fixed factor and concentrations as a variable factor ,represent the meaningful difference between groups.

(a,b,c) show the significant difference between groups when concentrations are fixed and days .are variable

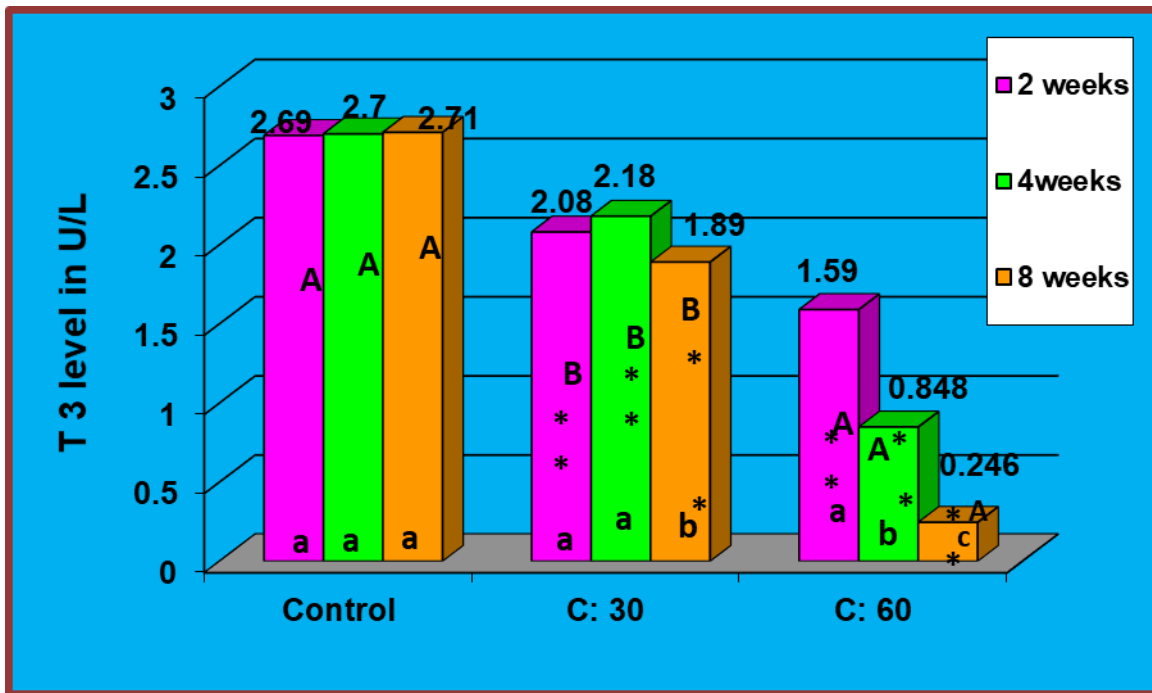


Fig. 3: Effect of different concentrations of MSG (30 ,60)gm/kg on T3levels of rats with different periods of time (2,4,8) weeks in comparison with control groups.

* Significant decrease ($P \leq 0.05$).

(A,B,C) Using days as a fixed factor and concentrations as a variable factor ,represent the meaningful difference between groups.

(a,b,c) show the significant difference between groups when concentrations are fixed and days .are variable

-the values of serum T4 display a high significant decrease ($p \leq 0.05$) of both dose (30 and 60) mg/kg (55.73 ± 0.83), (32.04 ± 0.58) (mg/dl) respectively at 2 weeks in comparison to control groups (75.01 ± 1.13) (mg/dl) . At 4 weeks showed high significant decrease in level of T4 in both dose (30 and 60) mg/kg (43.35 ± 0.63), (19.32 ± 0.34) (mg/dl) respectively compare to control groups (75.29 ± 1.04) (mg/dl) .as well as the 8 weeks showed high significant decrease in level of T4 in both dose (30 and 60) mg/kg (34.23 ± 0.72), (7.26 ± 0.34) mg/dl in comparsion to control groups (75.42 ± 0.94) mg/dl figure 4.

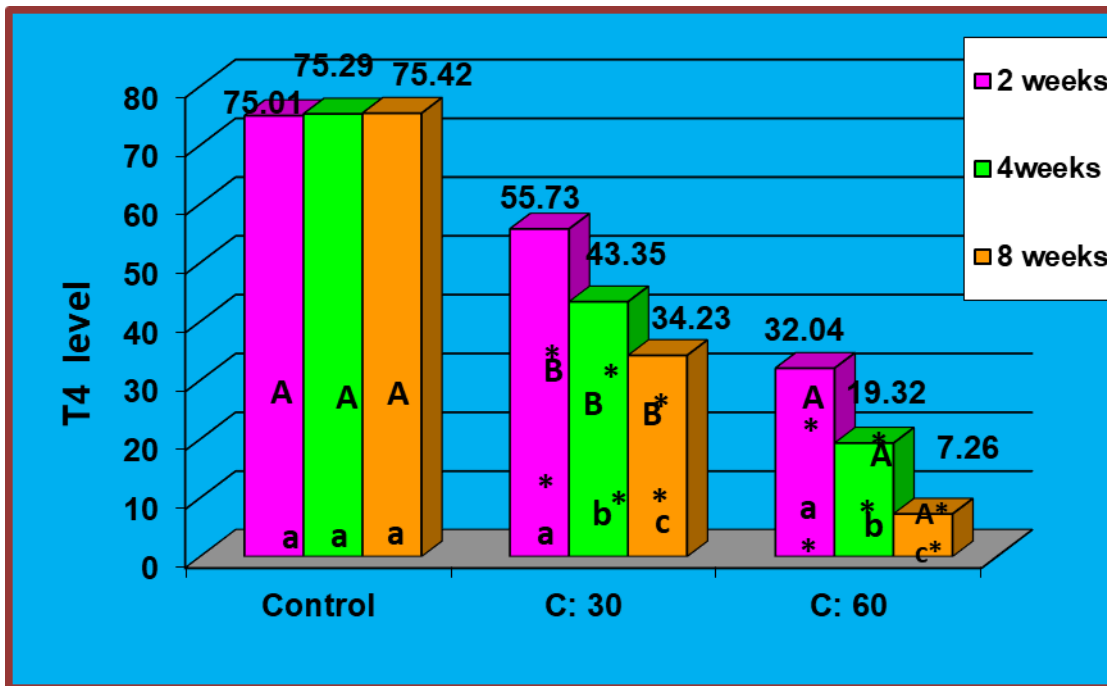


Fig. 4: Effect of different concentrations of MSG (30 ,60)gm/kg on T4 levels of rats with different periods of time (2,4,8) weeks in comparison with control groups.

*high Significant decrease ($P \leq 0.05$).

(A,B,C) Using days as a fixed factor and concentrations as a variable factor ,represent the meaningful difference between groups.

(a,b,c) show the significant difference between groups when concentrations are fixed and days .are variable

A study by Bakke *et al .*, (1978) which dis- agree with present study , they were used the animals (rats, mice) exposure to MSG (dose varying from 2.2 to 4 mg / kg of body wt.) showed, there were reduction in weight of thyroid , also disagree with present stud by reduced in Serum level of (TSH) in the males , but agree with present study that showed decrease in Serum T₄ in females. The current study's findings are consistent with prior reports of MSG causing thyroid weight gain

The preceding Studies on male Wistar strain rats treated with MSG at 4 mg/g body weight on days 2, 4, 6, 8, and 10 of life revealed a substantial rise

in experimental rat thyroid weight that agree with present study but were highest in the group of 12-month-old rats is agree to new study by decrease the serum T4 level. But is disagree with present study by observed an increase in the serum T3 level (Waer & Edress ,2006). A previous study Miskowiak & Partyka . (1993) , agree with present study by increase in body weight also is agree by decrease in serum level of T4 . but previous study disagree with current study by increase in serum level of T3 .

Abd Allah. (2021) conducted a previous study in which rats were divided into five groups: control (G1), MSG (60 mg/kg b.wt./day) group (G2), MSG+ 0.5% Sp group (G3), MSG+ 1% Sp group (G4), and MSG+ 2% Sp group (G5). The experiment lasted 28 days. Thyroid gland was studied, and there was a large increase in thyroid-stimulating hormone (TSH) in rats given MSG, which agrees with the current study, as well as a significant decrease in Tri-iodothyronine (T3) and thyroxine (T4) hormone levels, which also agrees with the current study. A recent study contradicted a prior study by Helal *et al.*, (2019), in which the animals were placed into four ;groups .

Khalaf and Arafat , (2015) conducted a study in which rats were separated into four groups: group I control, group II, III, and IV treated with MSG (0.25 g/kg, 3 g/kg, and 6 g/kg daily for one month), respectively. The serum levels of T3 and T4 were non-significantly higher in the low dose MSG treated group and considerably higher in the high and toxic doses treated groups compared to the control group, which contradicts the current study .

n a prior study, Helal *et al.*, (2017) utilized thirty young male albino rats separated into three groups: Group I served as the control group, Group II was given a mixture of sodium nitrite (NaNO₂ 0.1 mg/kg b.wt/day), annatto (0.065 mg/kg b.wt/day), and monosodium glutamate (MSG 15 mg/kg b.wt/day), and Group III was given the previous mixture and then royal jelly

(14.28 mg/kg b.wt/day soluble in maize oil). When compared to control rats, rats given the food additive mixture ((consisting of sodium nitrite+ annatto+ monosodium glutamate)) showed a significantly significant rise in T3 and T4 levels. That contradicts the current study.

2.8.3 Histological Changes of thyroid

- ❖ The following are the primary histological changes on thyroid tissues in all treated rats with MSG across different time periods when compared to control groups: Thyroid sections showed several histological alterations after 4 days of treatment with MSG at a concentration of 30gm/kg body weight, including: a large area of thyroid follicular necrosis (death) with uncommon follicles the existence of a lock similar to a typical follicle containing colloid particles ,figure (6) in comparison with the histological sections of thyroid from control groups of rats Figure (5) . Figure (7) shows that after 8 weeks, there is still the same follicle damage with rare follicles having colloid material and bordered by columnar epithelial cells but no scalloping and non-functional in comparison to histological sections of thyroid from control groups of rats. Fig. (5). Figure (8) depicts histological alterations following MSG administration at a dosage of 60 mg/kg body weight. for 4 weeks on thyroid sections showed: wide area of necrosis ,few follicles showing scalloping activity of colloid material in comparison with the histological sections of thyroid from control groups of rats Figure (5). In figure (9) ,The experimental group of 8 weeks showed , very wide area of damage (necrosis) and few follicles with colloid material but no scalloping (non- functioning)and lined by flat epithelial cells in comparison with the histological sections of thyroid from control groups of rats Figure (5).

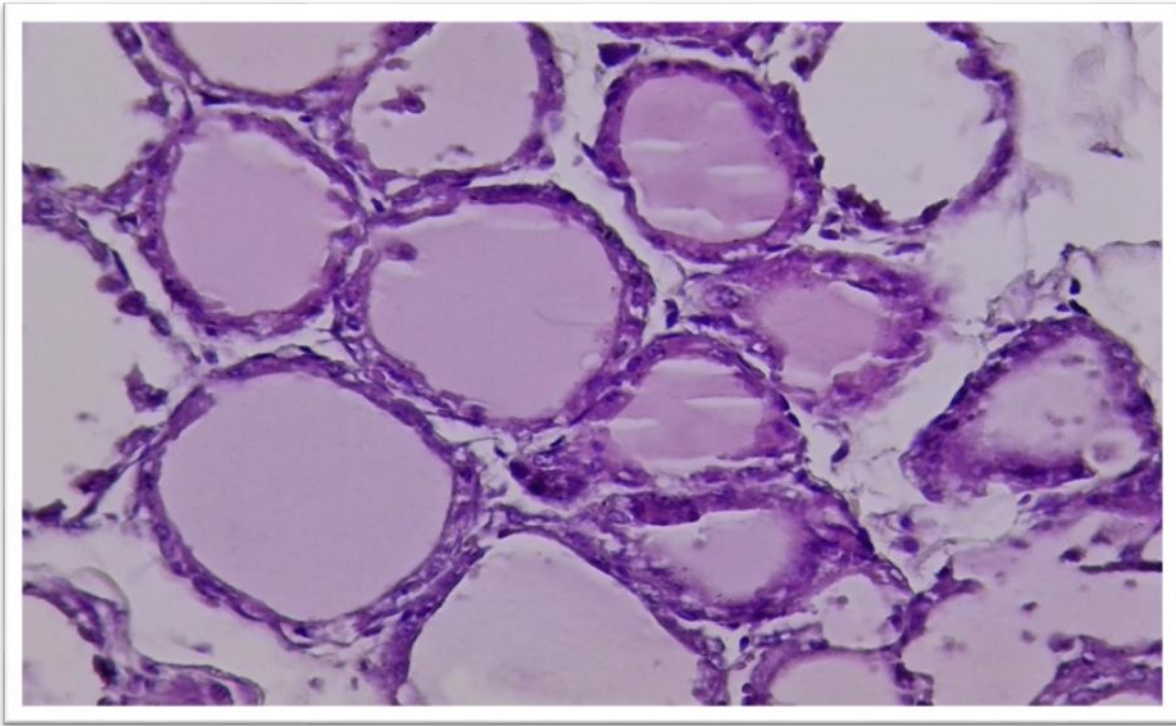


Figure (5) : Section of the normal structure of thyroid from rat control Groups with different size and shape showing : normal histological structure of thyroid follicles containing colloid material H XE (40x) .

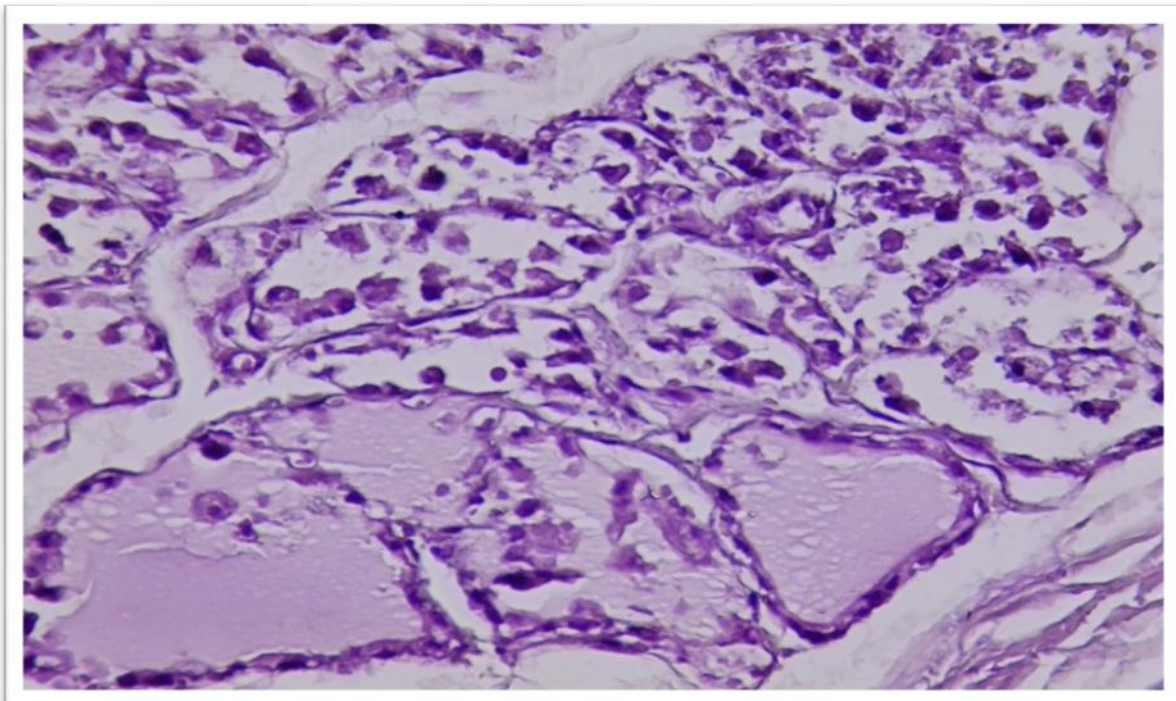


Figure (6) :Section of thyroid of rat group treated with 30 mg/kg of MSG for 4 weeks showing: wide area of thyroid follicle damage (necrosis) with rare follicles presence of lock like normal follicle containing colloid material .

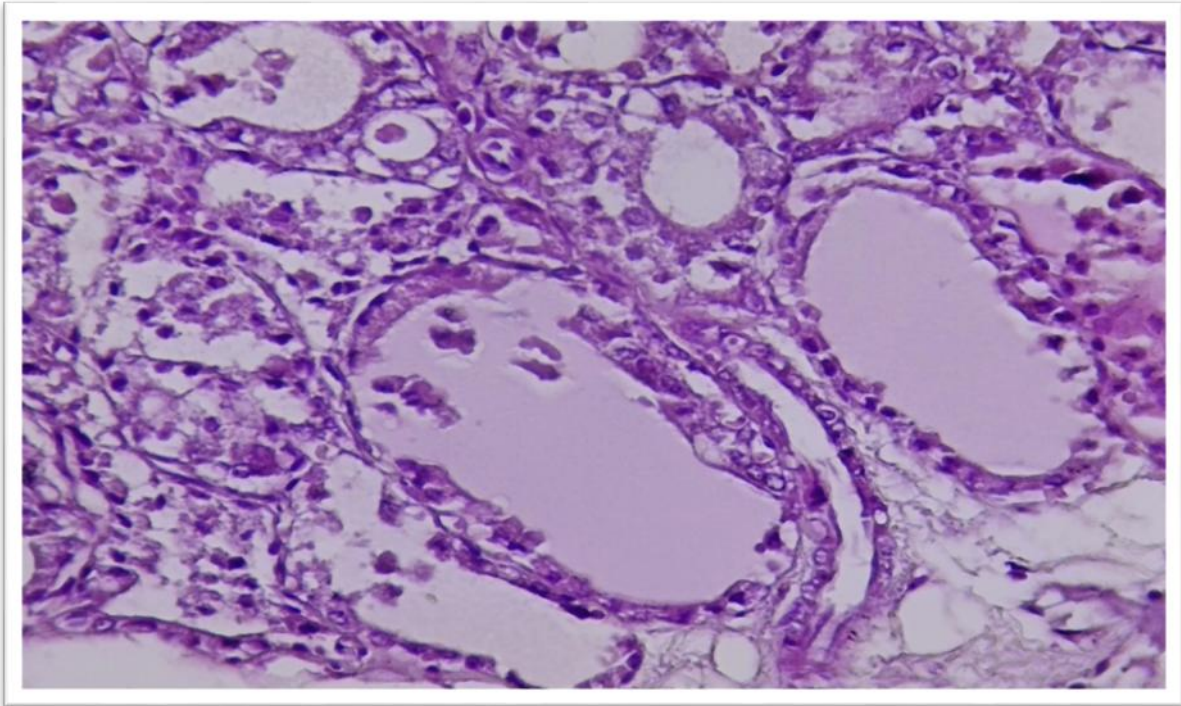


Figure (7) :Section of thyroid of rat group treated with 30 mg/kg of MSG for 8 weeks showing : still there is the same damage of follicles with rare follicles containing colloid material and lined by columnar epithelial cells but no scalloping and non-functional

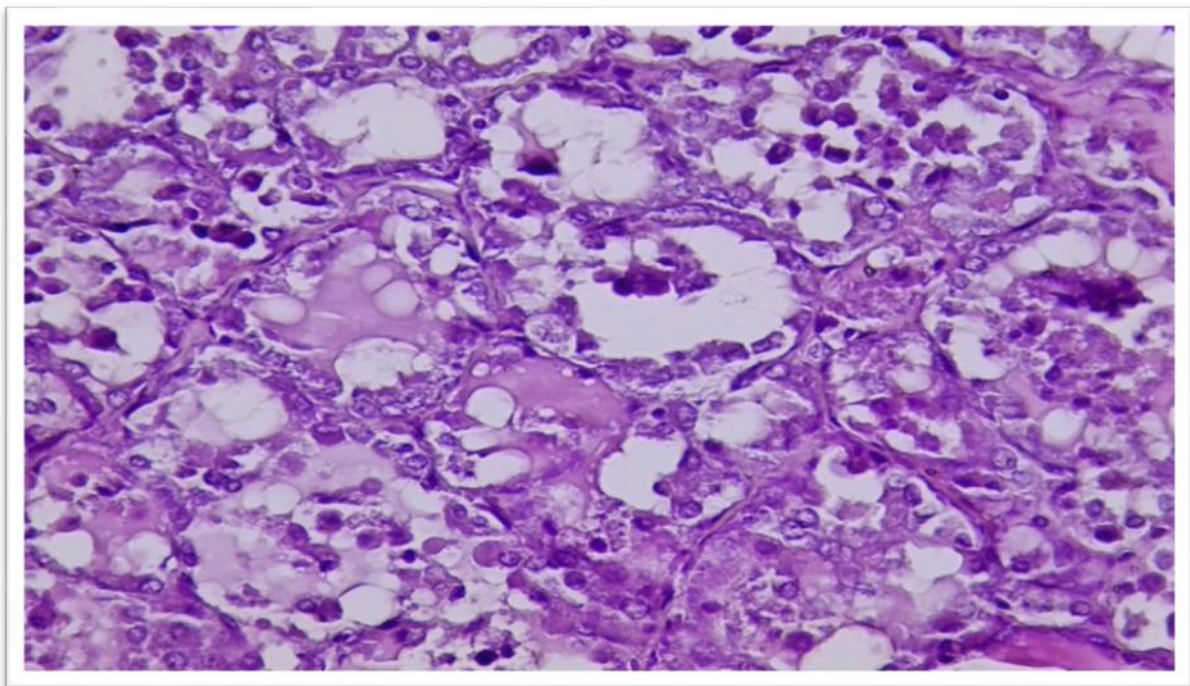
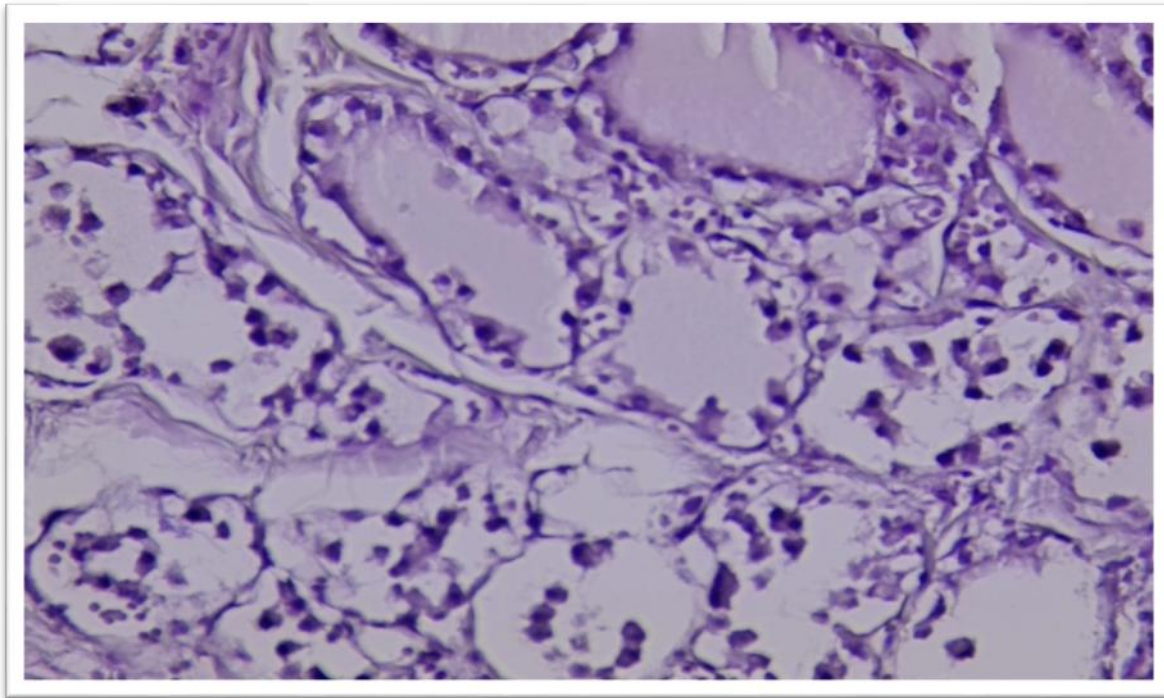


Figure (8): section of thyroid of rat groups treated with 60 mg/kg of MSG for 4 weeks showed wide area of necrosis ,few follicles showing scalloping activity of colloid material .



Figure(9) : section of thyroid of rat groups treated with 60 mg/kg of MSG for 8 weeks showed : very wide area of damage (necrosis) and few follicles with colloid material but no scalloping (non- functioning)and lined by flat epithelial cells .

The findings revealed that MSG, even at modest dosages, can alter thyroid tissue function and histology. and body weights that are consistent with the current investigation. According to a recent study (Khalaf & Arafat, 2015), different MSG doses had different effects on the thyroid gland's morphometric and histological changes. The experiment used 28 male albino rats. The rats were divided into four groups: group I was the control group, group II received MSG daily at doses of 0.25g/kg, 3g/kg, and 6g/kg, and group III received the same treatment. They had a decrease in follicular diameter, abnormalities in the morphologies of some follicles, and a discontinuity in the basement membrane. Follicular hyperplasia was

observed in some follicles, which was characterized by the development of multiple pyknotic nuclei in follicular and inter-follicular cells, as well as numerous exfoliated cells in the colloid. The results showed that MSG, even at modest doses, can cause follicular pattern loss and body weights that are consistent with the current study. A recent study found that when young female mice were given MSG at different doses (2, 4, and 6 mg/g) for seven days, large follicles inflated with colloid accumulation and surrounded by squamous cells remained after 13 and 52 weeks (Miskowiak and Partyka, 2000).

Thus, depending on the amount, mode of administration, and species, MSG appears to have varying effects on the pituitary-thyroid axis. The current study lends credence to the idea that excessive consumption of food additives (MSG) as a result of iodine deficiency may lead to the development of hypothyroidism and goiter, as well as thyroid hormone production suppression .

2.9 liver weight

- ❖ The statistical analysis of current study showed high significant increase ($P \leq 0.05$) in liver weight treated with MSG at both dose (30 and 60)mg/kg (7.92 ± 0.04), (10.76 ± 0.08) gm with period 2 weeks compare to control groups (7.01 ± 0.03) gm ,also there was high significant increase ($P \leq 0.05$) in liver weight of experimental groups at 4weeks treated with MSG at different doses(30 and 60) mg/kg (8.97 ± 0.32), (11.27 ± 0.25)gm in comparison to control groups (7.01 ± 0.04)gm ,the liver of experimental groups at 8weeks treated with MSG at doses (30 and 60)mg/kg showed high significant increase ($P \leq 0.05$) (10.43 ± 0.19) ,(13.25 ± 0.20) gm compare to control groups (7.01 ± 0.04) gm showed in figure (10) .

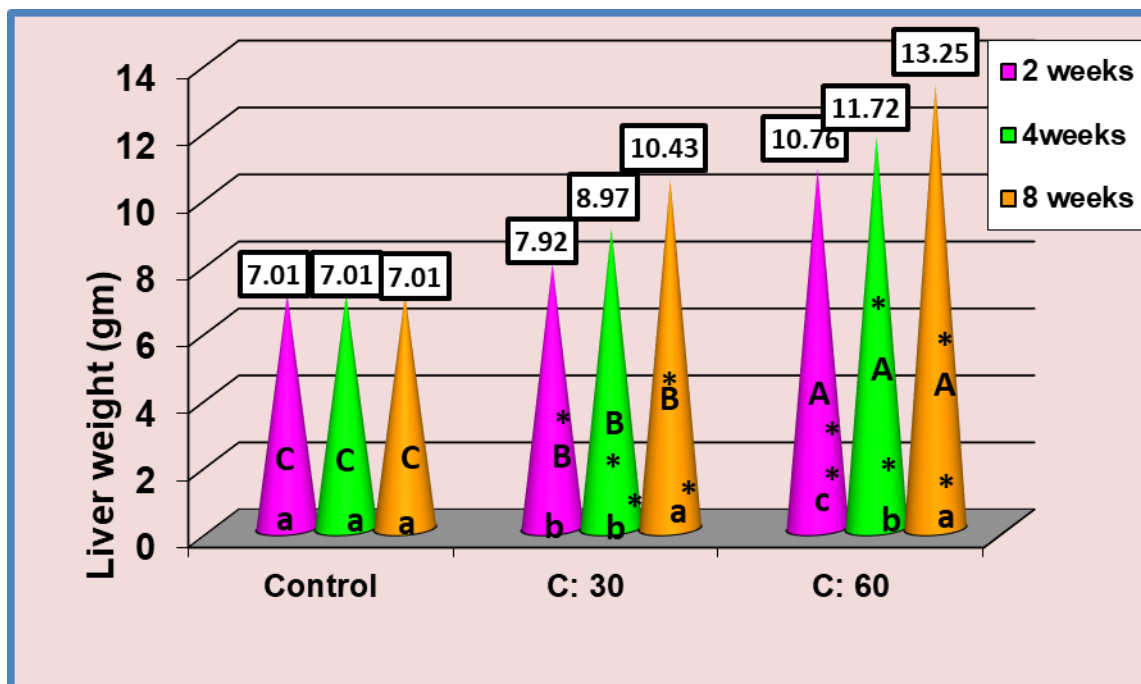


Figure (10) : Effect of two different concentrations (30 and 60 mg/kg) of MSG during different periods of exposure on Liver weight of rats compared with the control groups.

(*) highly significant increase ($P \leq 0.05$).

(A,B,C) represent the significant difference between groups with days as a fixed factor and concentrations as a variable factor.

(a,b,c) represent the significant difference between groups with concentrations as a fixed factor and days as a variable factor .

A study performed by Kumbhare *et al.*, (2015) showed Significant increase in the liver weight of the rats cause increase of the number of hepatocytes with large nuclei and there are degeneration of hepatocytes with numerous vacuolations in liver of albino rats treated with monosodium glutamate .

They were Mohamed *et al.*, (2021). Forty mature male albino rats were used in this study. They were divided into four equal groups of ten rats each.

Group I served as the control group, followed by Group II, which received TA (100 mg/kg) by oral gavage, Group III, which received MSG (2g/kg) by oral gavage, and Group IV, which received both TA and MSG by oral

gavage for four weeks. Differences in relative liver weight that are not statistically significant and contradict the findings of the current study.

A prior study that dealt with the current investigation found a significant rise in the number of hepatocytes with big nuclei and degeneration of hepatocytes with many vacuolations in the liver of albino rats treated with mono sodium (Kumbhare *et al.*, 2015) . AL-Khatawi *et al.*, (2019) found that administration of MSG at two doses (100,200 mg.kg b. w) resulted in a non-significant rise in liver weight of the rats. This could be related to an increase in inflammatory agent activity, which could result in inflammation of liver tissues.

This study found that MSG use at various doses and times causes a significant rise in liver weight.

2.9.1 Effect of MSG on Liver Functions

Statistical analysis of GPT levels showed high significant increase($p \leq 0.05$) demonstrated in figure (11) at period 2 weeks treated with different doses (30 and 60)mg/kg (52.13+0.77),(77.10+0.57) u/l respectively in comparison to control groups (40.58+0.13)u/l , also there was a high significant increase ($p \leq 0.05$) at period 4weeks in GPT levels at both doses (30 and 60)mg/kg (58.06+0.31),(83.35+1.03) u/l respectively in comparison to control groups (40.81+0.12) u/l . and there was high significant increase ($p \leq 0.05$) in GPT levels at period 8 weeks at doses (30 and 60) mg/kg (67.62+0.73) ,(92.03+0.56) u/l respectively compare to control groups (41.16+0.26) u/l .

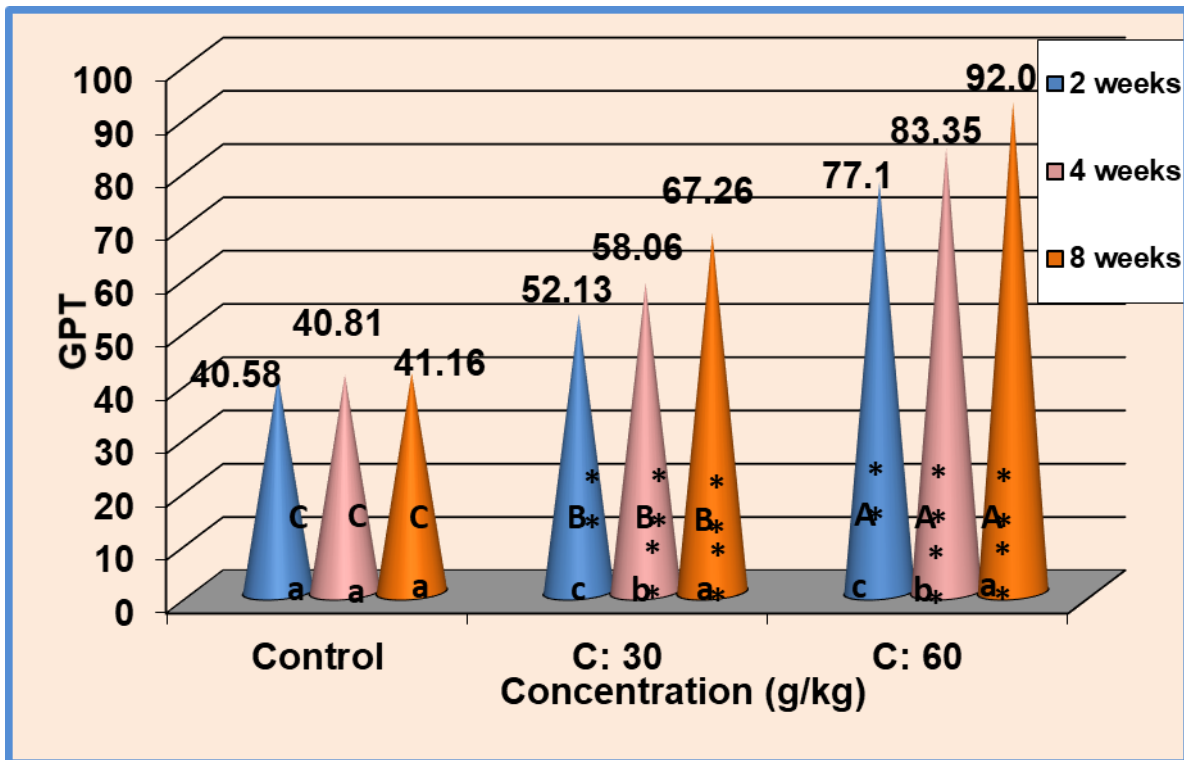


Figure (11) : Effect of two different concentrations (30 and 60 mg/kg) of MSG during different periods of exposure on GPT of rats compared with the control groups.

(*) highly significant increase ($P \leq 0.05$).

(A,B,C) represent the significant difference between groups with days as a fixed factor and concentrations as a variable factor.

(a,b,c) represent the significant difference between groups with concentrations as a fixed factor and days as a variable factor

The statistical analysis showed also MSG effected in ALP level demonstrated in figure (12) at 2 weeks showed high significant increase ($p \leq 0.05$) in ALP levels with doses (30 and 60) mg/kg (139.33±1.02),(284.00±1.06) u/l respectively in comparison to control groups (106.16±1.14 u/l) . as well as ALP showed a high significant increase ($p \leq 0.05$) at 4 weeks with doses (30 and 60) mg/kg (181.33±1.05), (306.16±1.42) u/l respectively compare to control groups (106.50±0.99 u/l) . and there was a high significant increase ($p \leq 0.05$) in ALP level at doses (30 and 60)mg/kg at 8 weeks (206.50±1.08),(450 .33±2.49) u/l in comparison to control groups (105.66±1.25 U/L).

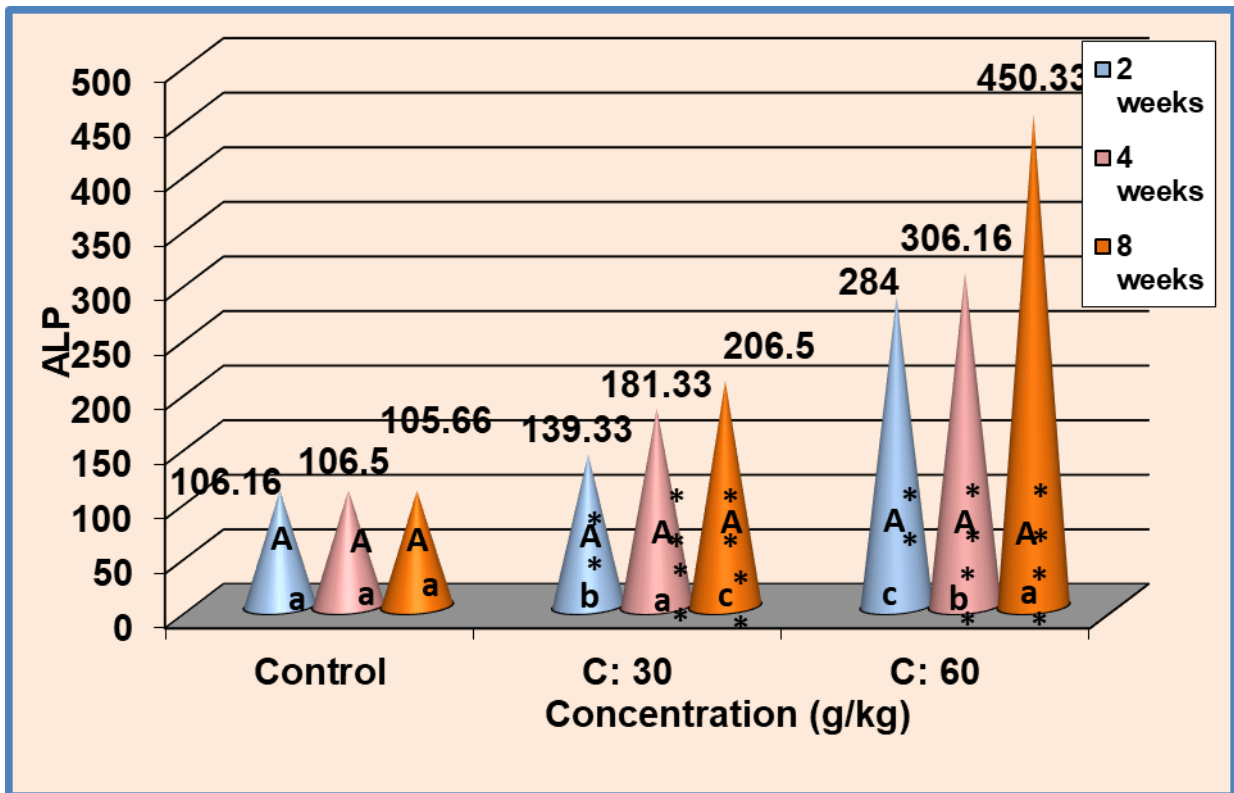


Figure (12) : Effect of two different concentrations (30 and 60 mg/kg) of MSG during different periods of exposure on ALP of rats compared with the control groups.

(*) highly significant increase ($P \leq 0.05$).

(A,B,C) represent the significant difference between groups with days as a fixed factor and concentrations as a variable factor.

(a,b,c) represent the significant difference between groups with concentrations as a fixed factor and days as a variable factor

-MSG also altered GOT level as showed in figure (13) showed high significant increase ($p \leq 0.05$) in GOT levels for different period of treatment (2, 4, 8) weeks at different doses of MSG (30 and 60) mg/kg (50.96±0.39), (64.68±1.88) U/L respectively at 2 weeks in comparison to control groups (39.06±0.28 U/L), also result showed a high significant increase in GOT levels at period 4 weeks treated with different dose of MSG (30 and 60) mg/kg (56.15±0.28), (71.65±0.29) U/L respectively when compare to control groups (39.28±0.23 U/L). as well as there

was a high significant increase in GOT levels at period 8 weeks treated with different doses (30 and 60)mg/kg (63.70+0.37),(85.80+0.55) U/L respectively compare to control groups (39.26+0.27 U/L) .

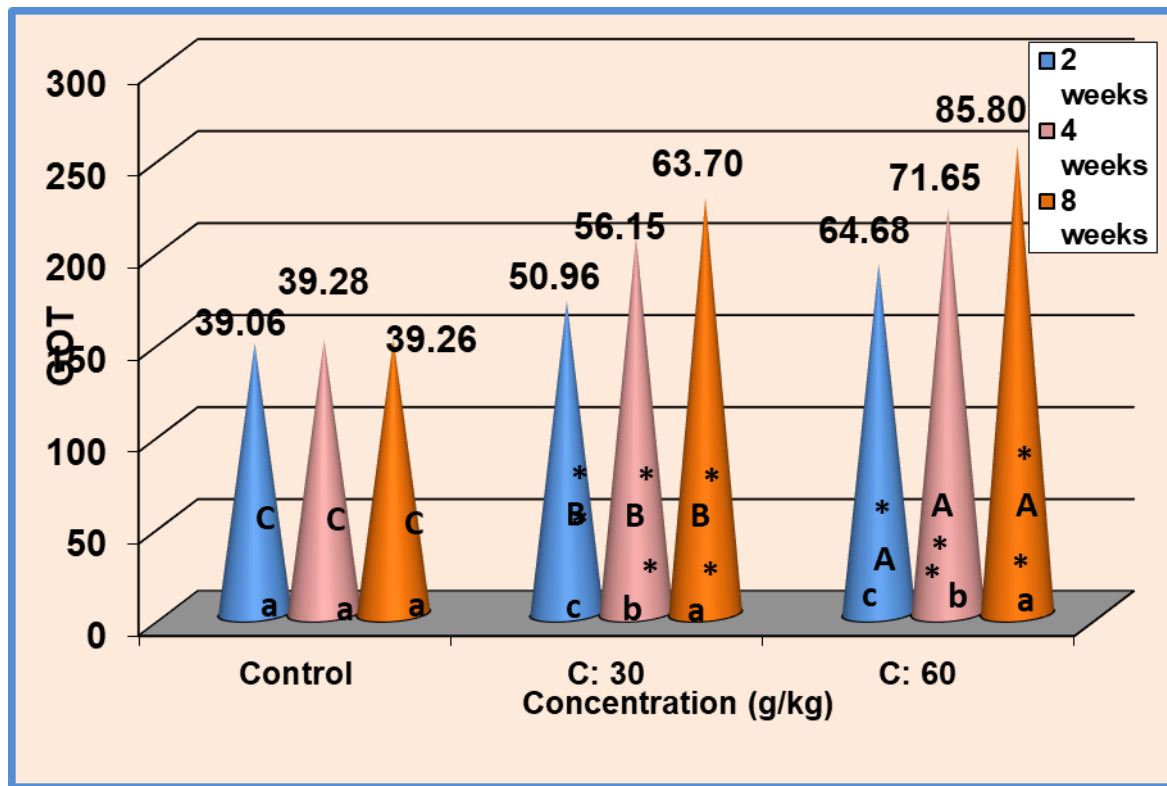


Figure (13) : Effect of two different concentrations (30and 60 mg/kg) of MSG during different periods of exposure on GOT of rats compared with the control groups.

(*) highly significant increase ($P \leq 0.05$).

(A,B,C) represent the significant difference between groups with days as a fixed factor and concentrations as a variable factor.

(a,b,c) represent the significant difference between groups with concentrations as a fixed factor and days as a variable factor

- statistical analysis of date showed high significant increase ($p \leq 0.05$) in total bilirubin levels at doses (30 and 60)mg/kg at 2 weeks (1.14+0.02),(2.26+0.05) respectively when compare to control groups (0.770+0.01) .

And there was a high significant increase ($p \leq 0.05$) in total bilirubin levels at 4 weeks treated with both doses (30 and 60)mg/kg

(1.52+0.02),(2.81+0.06) respectively in comparison to control groups (0.770+0.01) . also at 8 weeks period of time showed high significant increase ($p \leq 0.05$) in total bilirubin levels at different doses (30 and 60)mg/kg (1.87+0.04),(3.97+0.04) respectively in comparison to control groups (0.773+0.01) showed in figure (14) .

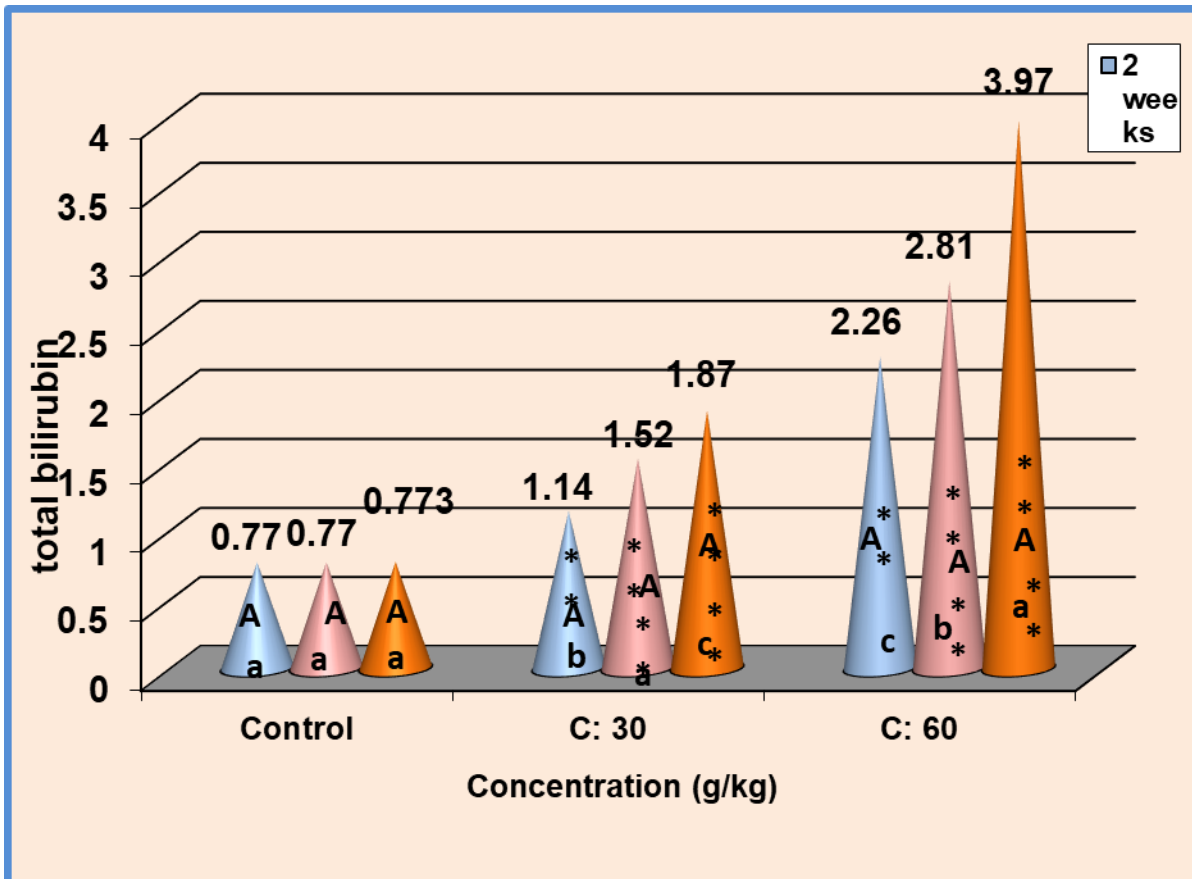


Figure (14) : Effect of two different concentrations (30 and 60 mg/kg) of MSG during different periods of exposure on total bilirubin of rats compared with the control groups.

(*) highly significant increase ($P \leq 0.05$).

(A,B,C) represent the significant difference between groups with days as a fixed factor and concentrations as a variable factor.

(a,b,c) represent the significant difference between groups with concentrations as a fixed factor and days as a variable factor

The results of this study about liver function agree with other studies by Manal Said & Nawal. (2012) , the showed that was administrated to rats at doses of 0.6 and 1.6 mg/g body weight for 14 day , liver functions, the activities of alanine aminotransferase (ALT) and γ glutamyle transferase (GGT) significantly increased when the MSG administration, while disagree with the this study by serum total bilirubin significantly decreased. the increased activity of GGT in serum of MSG treated animals might have caused from the liver injury caused by the MSG that induced oxidative stress. The increased serum AST and ALT values are also reported similarly by Egbuonu *et al.*, (2010) ,who suggested that the increased AST and ALT values could be attributed to acute toxicity of MSG leading to enhancing hepato-cellular activity and it could be reflected to possible treatment-induced damage to the metabolically active organ including the liver. In another investigation by Onyema *et al.*, (2006) given MSG to rats (by gavage) at a dose of (0.6 mg/g) for 10 days. The activities of (ALT), (AST), and (GGT) were likewise significantly enhanced in serum after MSG intake. the current study's findings on a rise in liver enzymes 48 male rats were treated with MSG (97 mg/kg bw) daily for 6 weeks by Ibrahim *et al.*, (2019). The results showed that MSG significantly elevated the levels of ALT, AST, and ALP in rats, indicating that MSG-induced liver damage.

The thyroid and the liver are linked, and the liver is involved in the metabolism, transport, and inactivation of thyroid hormones. Thyroid hormones influence hepatocyte activity and metabolism. Impaired lipid metabolism in hypothyroidism may be linked to elevated blood liver enzyme levels (Piantanida *et al.*, 2020).

The serum concentration of aminotransferases rises as a result of cellular membrane collapse and leakage to the tissues that produce them, which is a biochemical sign of hepatocellular necrosis. Because the increase in liver

enzymes reflects the congestion in the hepatic vein and the damage to the hepatocytes that resulted in necrosis, MSG supplementation may have produced these alterations, which may have led to an imbalance in the liver's activities.

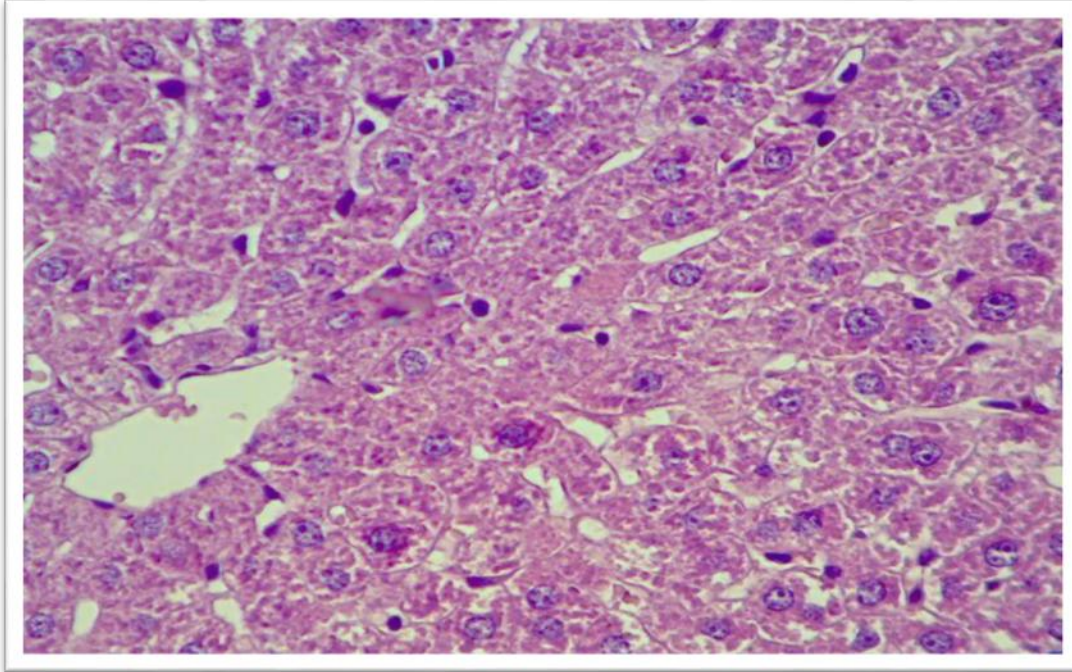


Figure (15): Section of liver from rat control groups showing:

1. Appearance of central vein, 2. Arrangement of hepatocytes as a cord around central vein, 3. Sinusoids 4. Kupffer cells, 5. Endothelial cell. (40x) H&E.

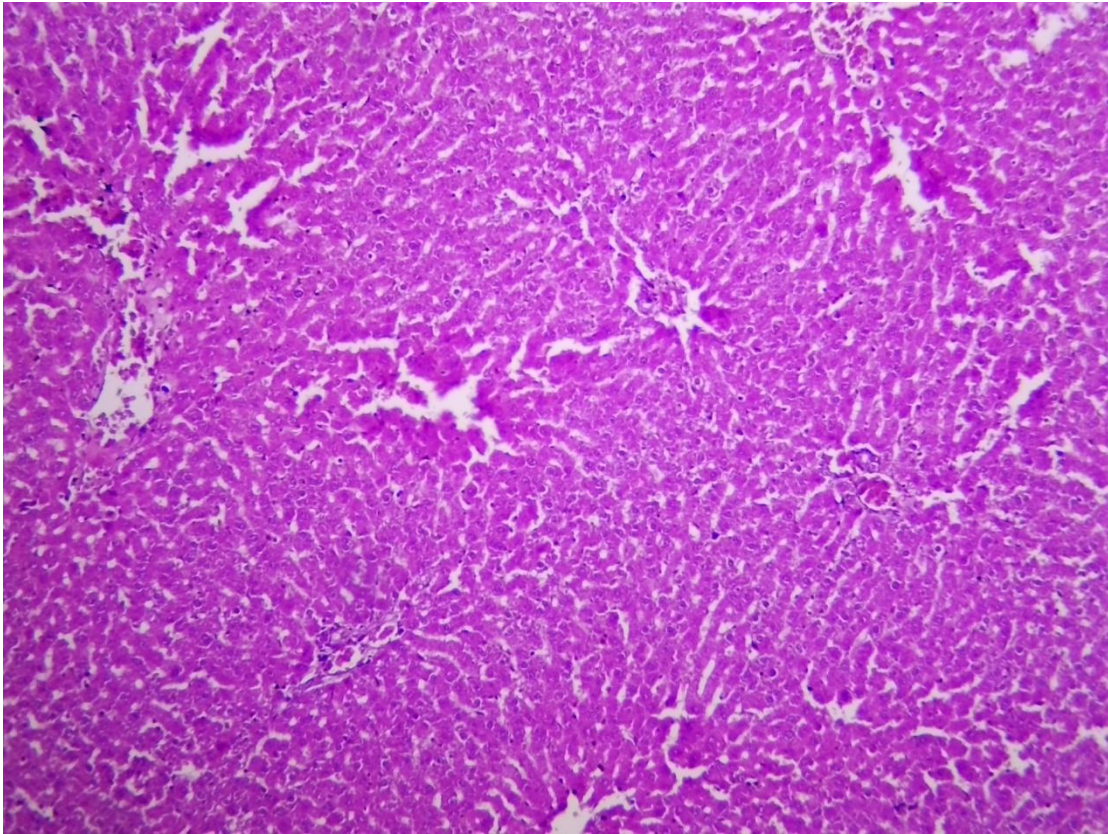


Figure (16) : section of liver of rat groups treated with 30 mg/kg of MSG for 4 weeks showing lock like normal but there is sinusoid of dilation (X 40)

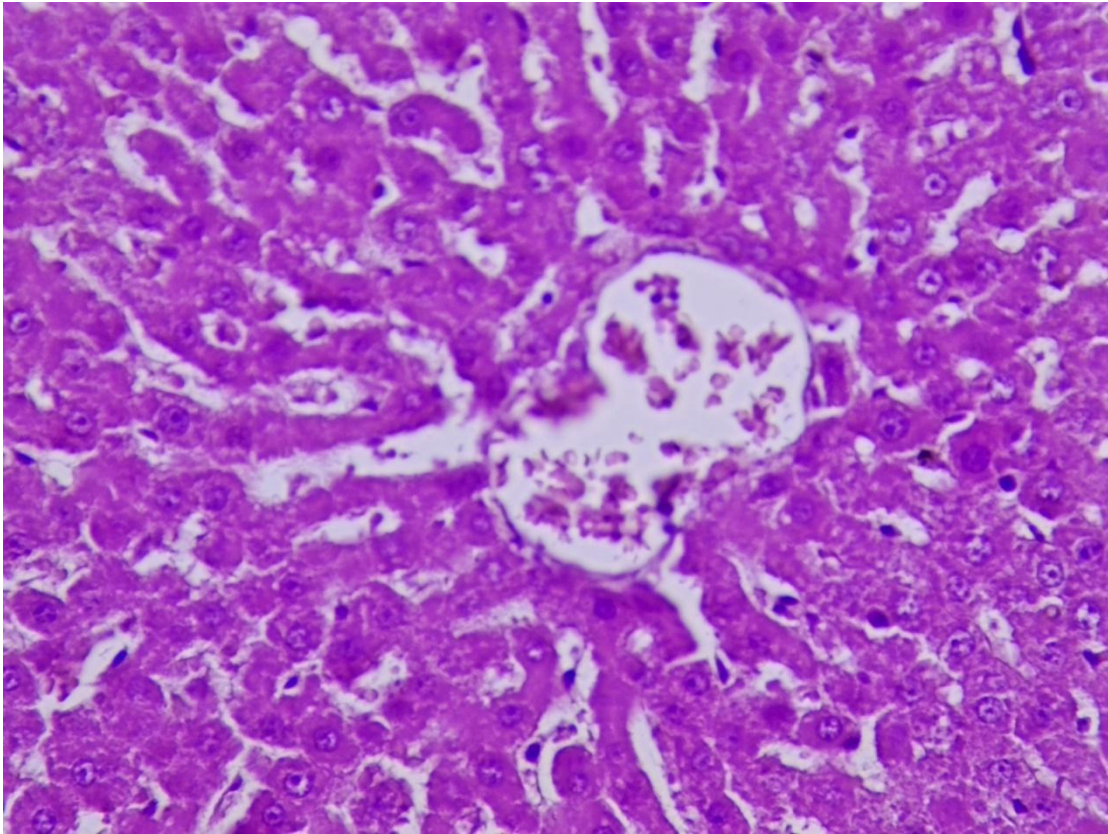


Figure (17) : section of liver of rat groups treated with 30 mg/kg of MSG for 8 weeks showing lock like normal of hepatocyte cells but there is dilation of sinusoid with few apoptotic cell (X40)

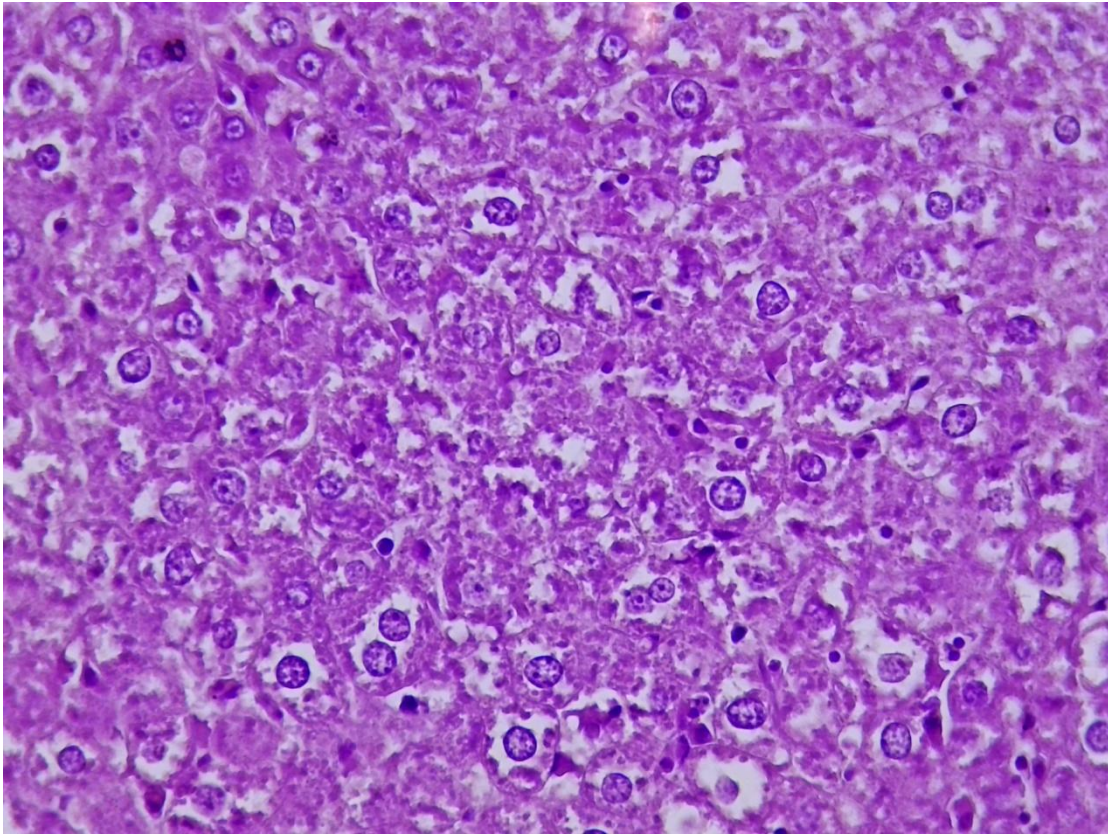


Figure (18) : section of liver of rat groups treated with 60 mg/kg of MSG for 4 weeks showing depletion of glycoprotein with accumulation of cholesterol material and few apoptotic cell (X 40)

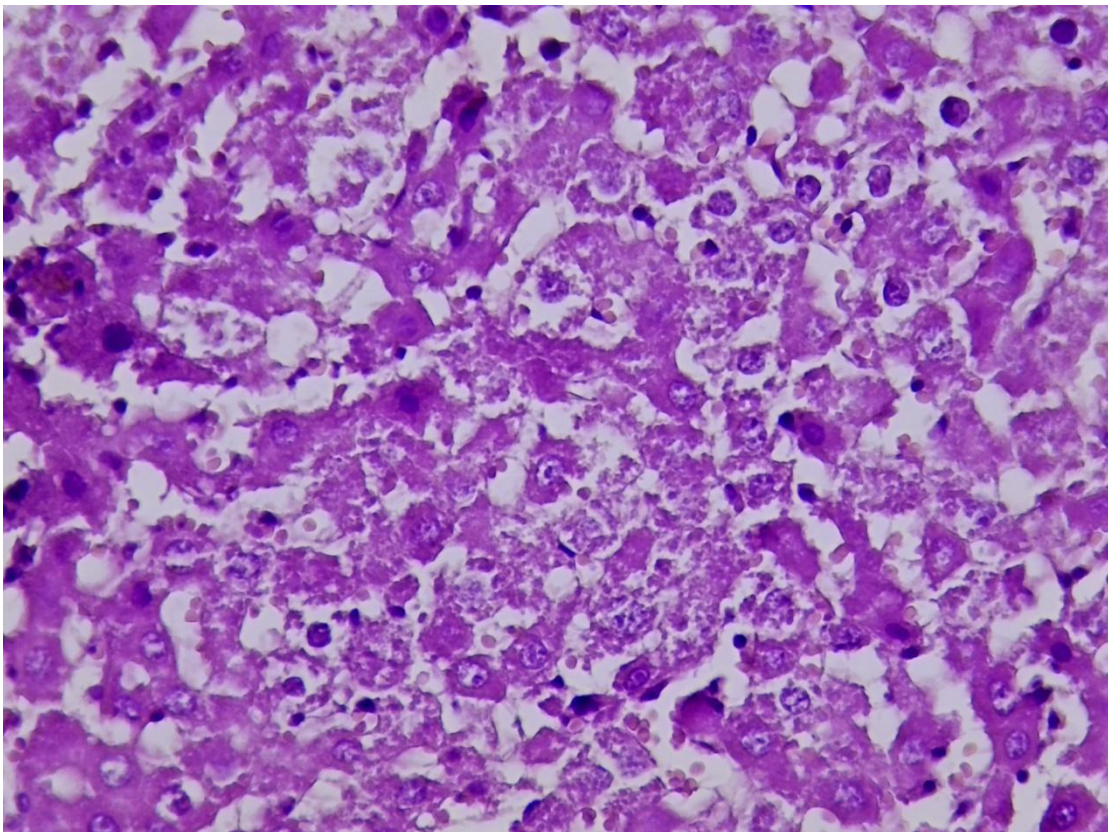


Figure (19) : section of liver of rat groups treated with 60 mg/kg of MSG for 8 weeks showing dispersed focal area of hepatocyte cell damage sinusoid dilation .

2.9.2 Histological changes

The main histological changes in all treated rats with MSG liver tissues in different periods of time compared to control groups is shown as follows: Liver sections showed different histological changes after treatment with MSG in concentration of 30gm/kg of body weight for 4 weeks showing lock like normal but there is sinusoid of dilation figure (16) . in a dose of 30gm/kg. and in a period of 8 weeks, liver sections showed lock like normal of hepatocyte cells but there is dilation of sinusoid with few apoptotic cell figure (17) compared with the histological sections of liver from control groups of rats figure (15) , Histological changes after treatment with fennel in concentration of 60 gm/kg of body weight for 4 weeks on liver sections showed depletion of glycoprotein with accumulation of cholesterol material and few apoptotic cell figure (18) , while in experimental group of 8 weeks treatment with MSG showed dispersed focal area of hepatocyte cell damage sinusoid dilation figure (19) compared with the histological sections of liver from control groups of rats figure (19).

The liver is a crucial organ in the body that is responsible for hazardous chemical and drug detoxification, and it is a target organ for all toxic substances (Rabeh and Aboraya, 2014). Shangloo *et al.*, (2021) used 18 inbred adult albino rats in their study, with the control group (A) receiving only standard diet with distilled water, the group (B) rats receiving 0.5 mg/kg of MSG dissolved in distilled water, and the group (C) rats receiving 1.5 mg/kg of MSG dissolved

in distilled water per orally for 28 days. Control group liver tissue slices revealed typical hepatic architecture with central veins positioned in the center of the hepatic lobule and portal areas comprising portal triad constituted by portal venule, hepatic vein, and portal vein. In group (B) exhibited pathological changes in the form of dilated and congested central vein with sinusoidal dilatation. In group (C) marked more pathological changes seen in group B along with dilatation of the portal vein .

recent study by Mohamed *et al.*, (2021) gavage rats of MSG (2g/kg) by oral gavage indicated a significant complete loss in hepatic architecture such as congestion and dilatation in blood vessels with various cellular alterations such as necrosis and apoptosis when compared to the control group. AL-Khatawi *et al.*, (2019) reported that rats exposed to MSG (100mg/kg b.w) showed loss of normal liver architecture, areas of coagulative necrosis, dilated sinusoidal spaces, and degeneration of hepatocytes with varying shapes and sizes of nuclei with regard to the current study. Hammoud *et al.*, (2018) shown that treating rats with MSG at two dose levels (3 and 6 g/kg b.w) resulted in hepatic necrosis accompanied with inflammatory cell infiltration.

Congestion of blood vessels alludes to advanced liver tissue damage that might affect liver activities; The liver is a key site of biotransformation because it transforms xenobiotics into water-soluble compounds that may be eliminated successfully. Liver cells and kidneys contain several enzymes that oxidize xenobiotics to form metabolites; enzymes conjugate to these metabolites to form a larger and more polar molecule to facilitate excretion and prevent accumulation of harmful substances in the body; however, biotransformation may induce toxicity when metabolites are not

conjugated to enzymes and thus bind to and damage cellular structures (binding to DNA induces mutation, resulting in genetic toxicology) (Luaibi and Shafiq , 2016)

overloaded biotransformation causes massive destruction of essential proteins or lipid membranes and cause cell death

References

- 1- MOORE K.L.: Congenital malformations due to environmental factors: Developing Humans. W.B. Saunders co. Ltd Philadelphia, 2 nd ed. pp. 173-183, 2003.
 - 2- NHIC (Natural Health Information Center): [http://www. Natural-Health-Information-Center.com](http://www.Natural-Health-Information-Center.com) ., 2008.
 - 3- SAMUELS A.: The Toxicity/Safety of MSG: A Study in Suppression of Information. *Accountability in Research*, 6 (4): 259-310, 1999.
 4. Giannini, E. G., Testa, R., and Savarino, V. (2005). Liver enzyme alteration: a guide for clinicians. *Canadian medical association journal*, 172(3), 367-379.
 5. Nordmann, R., Ribière, C., and Rouach, H. (1992). Implication of free radical mechanisms in ethanol-induced cellular injury. *Free Radical Biology*.
 - 6- BHATTACHARYA T., BHAKTA A. and GHOSH S.K.: Long term effect of monosodium glutamate in liver of albino mice after neonatal exposure, *Nepal Medical College Journal*, 13 (1): 11-16, 2011.
- Manal Said, T., & Nawal, A. B. (2012). Adverse effects of monosodium glutamate on liver and kidney functions in adult rats and potential protective effect of vitamins C and E. *Food and Nutrition Sciences*, 2012.
- Ortiz, G. G., Bitzer-Quintero, O. K., Zárate, C. B., Rodríguez-Reynoso, S., Larios-Arceo, F., Velázquez-Brizuela, I. E., ... & Rosales-Corral, S. A. (2006). Monosodium glutamate-induced damage in liver and kidney: a

morphological and biochemical approach. *Biomedicine & pharmacotherapy*, 60(2), 86-91.

IFIC. Review of Monosodium glutamate, Examining the Myths.1994. 2.

Zia MS, Qamar KRH, Moazzam K. Effect of monosodium glutamate on the serum estrogen and progesterone levels in female rat and prevention of this effect with diltiazem. *Ayub med Coll Abbottabad*. 2014;26(1):18-20.

Egbonu, A. C. C., Ezeanyika, L.U.S. Ejikeme, P.M. and Obidoa , O. (2010) Histomorphologic alterations in the liver of male wistar rats treated with L- arginine glutamate and monosodium glutamate. *Res. J. Environ.Toxicol*. 4: 205-213

3. Samuels A. The toxicity/safety of processed free glutamic acid (MSG). A study in suppression of information. *Acc in Res*. 1999;6(4):259-310 .

Miskowiak, B. and Partyka, M. (1993). Effects of neonatal treatment with MSG (monosodium glutamate) on hypothalamo-pituitary-thyroid axis in adult male rats. *Histology and histopathology*

Luaibi, N. M., and Shafiq, A. A. (2016). Study of Biochemical and Histological effects of fennel seeds (*Foeniculum vulgare*) on Liver in Male Rats. *journal of the college of basic education*, 22(96), 1-24.

Bakke, J. L.; Lawrence, N.; Bennett, J.; Robinson, S. and Bowers, C. Y. (1978). Late endocrine effects of administering monosodium glutamate to neonatal rats. *Neuroendocrinology*, 26(4): 220-228.

Waer, H.F .and Edress,S .(2006) The Effect of Monosodium Glutamate (MSG) On Rat Liver And The Ameliorating Effect Of “Guanidino Ethane Sulfonic acid (GES)” (Histological, Histochemical and Electron Microscopy Studies) *The Egyptian Journal of Hospital Medicine* Vol., 24: pp524 – 538.

Abd Allah, A. L. (2021). Prophylactic Effect of Spirulina Versus Monosodium Glutamate Induced Thyroid Disorders in Experimental Rats. *Egyptian Journal of Nutrition and Health*, 16(1): 45-59.

Khalaf, H. A. and Arafat, E. A. (2015). Effect of different doses of monosodium glutamate on the thyroid follicular cells of adult male albino rats: a histological study. *International journal of clinical and experimental pathology*, 8(12), 15498.

Miskowiak, B. and Partyka, M. (2000). Neonatal treatment with monosodium glutamate (MSG): structure of the TSH-immunoreactive pituitary cells. *Histology and histopathology*, 15(2), 415-420.

Mohamed, P.; Radwan, R.; Mohamed, S. A. and Mohamed, S. (2021). Toxicity of monosodium glutamate on liver and body weight with the protective effect of tannic acid in adult male rats. *Mansoura Journal of Forensic Medicine and Clinical Toxicology*, 29(2): 23-32.

AL-Khatawi, G. M. G.; AL-Attabi, M. R. and Bargooth, A. F. (2019). Physiological and Histological Study to the Effects of Monosodium Glutamate in Laboratory male Rats and the protective role of vitamin E. *International Journal of Pharmaceutical Quality Assurance*, 10 (2), 272-279.

Kumbhare, V.; Gajbe, U.; Singh, B. R.; Reddy, A. K. and Shukla, S. (2015). Histological and histochemical changes in liver of adult rats treated with monosodium glutamate: a light microscopic study. *World Journal of Pharmacy and Pharmaceutical Sciences*, 4(4), p898-911.

Piantanida, E., Ippolito, S., Gallo, D., Masiello, E., Premoli, P., Cusini, C., . and Tanda, M. L. (2020). The interplay between thyroid and liver: implications for clinical practice. *Journal of endocrinological investigation*, 43, 885-899.

Onyema, O. O., Farombi, E. O., Emerole, G. O., Ukoha, A. I., and Onyeze, G. O. (2006). Effect of vitamin E on monosodium glutamate induced hepatotoxicity and oxidative stress in rats.

Ibrahim, M.; Khalifa, A.; Saleh, A. and Tammam, H. (2019). Histopathological and Histochemical Assessment of Monosodium Glutamate-Induced Hepatic Toxicity and the Amelioration with Propolis. *Ain Shams Journal of Forensic Medicine and Clinical Toxicology*, 33(2), 24-36.

Rabeh, N. M. and Aboraya, A. O. (2014). Hepatoprotective effect of Dill (*Anethium graveolens*) and fennel (*Foeniculum vulgare*) oil on hepatotoxic rats. *Pakistan Journal of Nutrition*, 13(6): 303-309.

Shangloo, P., Syed, M., and Gupta, S. (2021). Effect of monosodium glutamate on liver of adult albino rats: a light microscopic study. *International Journal of Research in Medical Sciences*, 9(5), 1442.

Hammoud, G. M.; Salem, A. A.; ELSawy, K. M. and Abd El-Shafea, Y. M. (2018). Influence of ferulic acid on monosodium glutamate toxicity in rats: hematological, clinopathological and histopathological studies. *J. Chem. Bio. Phy. Sci. Sec. B*, 8(1): 224-242.