

# Depakine drug effects on some reproductive embryonic parameters and hepatic -histological changes during pregnancy of albino female rats.

Dalal Abdel-Hussein Kadhim AL– Essawi<sup>1</sup>, Shiamaa Jaber Ghiadh<sup>2</sup>, Assel Said Ismael Alhadad<sup>3</sup>

*1,3, Department of Biology, Faculty of Education for Girls, University of Kufa, Iraq.*

*2, Pharmacy Faculty, University of Kufa, Iraq.*

*[dalala.alesawi@uokufa.edu.iq](mailto:dalala.alesawi@uokufa.edu.iq) AL-Najaf AL-Ashraf-Iraq.1*

**Abstract** *The effects of the antiepileptic drug depakine on some embryonic reproductive parameters and hepatic- histopathological changes of the embryos of pregnant female rats treated with this drug during pregnancy were investigated. 10 female albino rats of the Sprague dawley strain were divided into two groups, each group contained 5 pregnant female rats: group 1 was as control group and treated with the normal saline, while group 2 was treated with the drug depakine with the therapeutic dose (1.78 mg / kg of body weight) from the 4th day of pregnancy to the 18th day of it, on the 19th day of pregnancy the pregnant rats were sacrificed , the livers and uterine horns were removed from the body to study the embryonic reproductive parameters, then the embryos were sacrificed and their livers extracted, the livers of pregnant female rats and embryos were fixed with formaline for histological processing and the assessment of stimulating histopathological effects by this drug.*

*The results from present study showed a significant decrease ( $P < 0.05$ ) in weight gain of pregnant female rats , numbers of total and living embryos and the weights of the body and placenta and lengths of total body and limbs (hands and feet) of embryos , while the results pointed to a significant increase ( $P < 0.05$ ) in the absorbed and dead embryos and the skeletal system of embryos suffered from many malformations during pregnancy period of 18 days in treated rats group with depakine drug comparing with control group, and the hepatic- histological study of the pregnant female rats and embryos indicated normal hepatic-histological structure of animal rats during pregnancy period of 18 days in control group , while experimental rat group treated with depakine drug signified various patho-histological changes in livers of the pregnant female rats and embryos of the same pregnancy period .*

## **Introduction**

Epilepsy is one of the oldest brain disorders that the humans was known it ,and it is a chronic disorder that affects the brain and results from a defect in the transmission of electrical signals within it which it is accompanied by a seizure of involuntary movements, loss of control of intestinal and / or bladder functions, and a lack of consciousness, and these seizures occur from the increase in electrical charges which were released by a group of brain cells (Cheng *et al.*, 2020 ), the causes of epilepsy may be

hereditary or acquired which were in 60% of them were unknown, and the most important acquired reasons were serious brain trauma or problems in the brain such as stroke or tumors, epileptic seizures may range from short-term seizures and almost cannot its detection to long-term seizures with severe spasticity that may sometimes cause fractures of the body bones in addition to various physical injuries (Cho and Kim, 2019).

Epilepsy is initially treated by medical drugs that were used alone or patients may need to take more than one of anti-seizure drugs to control epileptic seizures, as about 70% of epilepsy cases were treated with antiepileptic drugs, but in certain cases that did not respond to treatment with these drugs, the resort was to the surgery for controlling these the seizures and there are many types of drugs to dominate this disease, which are often available in pharmacies (Ghodke-Puranik et al., 2013).

Depakine drug is one of the most important anti-seizure drugs that is widely used in the world because it has a therapeutic properties of many types of epilepsy, depakine is also called sodium valproate which is one of the brand names of valproic acid which is a branched short chain fatty acid which is derived from naturally occurring valeric acid and is the scientific name of this drug (Tolou-Ghamri and Palizaban, 2015), depakine stops epileptic seizures and did not permanently cure this disease but helps to combat and reduce the frequency of seizures by controlling the excessive brain electricity, depakine is also used in treatment of characterized bipolar depression with seizures of alternately mania and depression, prevents migraine seizures and may also be used to treat aggressive attacks in children who were shown disturbances of increased activity and decreased attention and focus (Ayano, 2016), although the action of depakine drug is not fully understood, its anti-convulsive effect in epilepsy may be due to the blocking of sodium channels that have an electrical voltage causing a decrease in the discharge of electrical charges in the brain, and also an increase in the concentrations of the chemical known as gamma-aminobutyric acid (GABA) in the brain which is main substance in stopping or preventing epileptic seizures and this the increase in GABA may be either by increasing the brain concentrations of the GABA neurotransmitter, inhibiting the re-uptake of GABA by neurons, and inhibiting the enzymes responsible for the degradation of GABA (Cook and Bensalem-Owen, 2011).

This drug can be used for long periods and continuously because it did not have any narcotic effect, but may cause a number of unwanted side effects such as nose and mouth bleeding, vomiting, constipation, loss of appetite, insomnia, stomach ache, blurred vision, itching, rash, drowsiness, headache and hair loss (Nagalakshmi et al., 2010), depakine should not be used in people who have hypersensitivity against this drug or those with hepatic disorders or pancreatic diseases and should also be avoided in the pregnancy because it causes harmful effects on embryos such as fetal valproate syndrome especially during the first trimester of pregnancy which is characterized by deformities, congenital defects and sometimes the death (Macfarlane and Greenhalgh, 2018).

**Keywords:-** *depakine*, pregnancy, histological parameters, *fetal* parameters.

### **Materials and Methods**

Study was performed for 20/8/2020 up to 27/10/2020 in the Labs of College of Education for Girls / University of Kufa.

### **Animals**

In present study 10 female albino rats (*Rattus rattus*) with body weight 236 kg and age 12 weeks were used, 10 male rats (of the same type) also were used in this study for only mating, the animals were placed under similar conditions in laboratory of temperature (21-24) C°, ventilation, lighting and humidity and given freely the food and water.

### **Animals copulating**

One female was placed with one male of rats in copulating cage in an evening, after that, in morning the female rats were examined to look for the copulating plug in the female rat vagina or on floor of the cages, and for the purpose of making sure of mating between animals, vaginal smears were made of married females to notice sperms, these smears were stained with blue methylene stain, and the day when a vaginal plug and/ or sperms were noticed, it is the zero day of pregnancy (Yaping *et al.*, 2006).

### **Depakine drug**

Tablets of depakine drug with therapeutical dose of 500 mg were used in this study which brought from pharmacy, then the required concentration (1.78 mg / kg of body weight) was prepared.

### **Animal treatment**

After getting 10 pregnant rats, they divided into 2 groups, each group include 5 pregnant female rats, group 1 was injected with a normal saline and represented the control group, while and group 2 was injected with depakine drug with a concentration of 1.78 mg / kg of body weight, all pregnant female rats were injected with clean and sterile medical syringes from the 4 day of pregnancy to the 18 day of it with one dose per day.

### **Dissection**

The body weight of female rats were prerecorded before the pregnancy and at the 18 day of the pregnancy by balance of the weight, then at the 19 day of the pregnancy the pregnant female rats were scamed by chloroform and the animals were fixed on the dissection dish, abdominal cavity opened, the livers and the two uterine horns eradicated from the body and the numbers of total, living, absorbed and dead embryos were calculated, after that the embryos were derogated by opening the uterine horns and washing them with normal saline and drying them by filter papers, the weights of body and placenta were enrolled by weight balance and the lengths of total body and limbs (hans and feet) were recorded by using the length scaling ribbon, these embryos were anesthetized by chloroform and vivisected by abdominal cavity opening and the livers removed, then the livers of the pregnant female rats and embryos were placed in formalin fixative with concentration of 10% for 48 hours for preparing histological sections.

### **Histological study**

Hepatic histological sections of the pregnant female rats and embryos for pregnancy period of 18 days were civilized dependig on the method of Suvarna *et al* (2013), the sections of liver tissue of the pregnant female rats and embryos were examined and then photographed by compound microscope which contains camera for photography.

### **Statistical analysis**

Results were absolved by using by student test (T-tes), values represented the mean and standered error ( $M \pm SE$ ), least significant diffefences (L.S.D) was used for existing the significant diffefences between the two study groups at probability level ( $p < 0.05$ ).

### **Results and discusstion**

#### **- Depakine drug effect on weight gain of pregnant female rats .**

The weight gain of pregnant female rat bodies significantly decreased ( $P < 0.05$ ) in treated group with depakine drug during pregnancy of 18 days compared with untreated pregnant female rats (control group) for 18 days of pregnancy as signified in table 1, and this result may be back to the increase in the numbers of absorbed and dead embryos, the delayed growth and development of embryos in addition to the decrease in the body weights of the embryos and their placenta which results from the oxidative stress

stimulating by the biosynthesis of oxygen free radicals by the this drug which cause the superoxidation of lipids in the vital cellular membranes as well as the internal cellular basic biological molecules such as proteins and nucleic acids (DNA) and others in the cells of the maternal and embryonic tissues causing their breakdown which leads to the dead and absorbed of the embryos and development failure of the growing embryos inducing the decrease in the weights of the body of embryos and placenta and this leads to the decrease in weight gain of pregnant rats during pregnancy for a period of 18 days (Tung and Winn,2011),or this result may be due to absence and immaturity of the embryonic antioxidant defense mechanisms especially glutathion reductase ,superoxydedismutase and catalase whose their levels were low in the various organs of the embryos and stimulating harmful effects in them (Ornoy,2009).

**Table 1: Depakine drug effect on weight gain of pregnant female rats .**

The group	The Weight Gain (gm)
Control	138.56±0.02
Drug	67.79±0.03 *
L.S.D	13.75
The significant level	P <0.05

Values: represents mean ± standard error .

\*:represents a significant difference with control group.

L.S.D: represents least significant difference.

#### - Depakine drug effect on some embryonic parameters.

The results pointed to a significant decrease ( $P < 0.05$ ) in numbers of total and living embryos while significantly increased ( $P < 0.05$ ) the absorbed and dead embryos in treated animals group with depakine drug when compared with control animal rats, as shown in table 2, and in figures(1,2,3,4) respectively, some studies have shown that the depakine drug has the ability to pass from the mother's circulation across the placenta to the embryos and accumulates in their blood and stimulates embryonic pharmacological poisoning that leads to the absorption and death of the embryos, delayed development of the growing embryos and the various embryonic distortions (Kumar *et al.*,2000), several mechanisms have been assumed to explain embryonic malformations that depakine drug were stimulated , including that this drug helps to proliferate peroxisomes which represent important source for generating free oxygen radicals in the body (Werling *et al.*,2000),or it also inhibits the addition of methyle groups to the homocysteine compound causing an increase in its levels that help to synthesize a number of toxic oxygen free radicals especially H<sub>2</sub>O<sub>2</sub> and O<sub>2</sub>-that stimulate embryonic malformations especially in the neural tube (Wu *et al.*,2012), as well as this drug inhibits transcription and translation processes of the self antioxidant enzymes especially GPx and SOD in the body(Van Mil *et al.*,2010), also this antiepileptic drug induces apoptosis and fragmentation of DNA molecules in the cells of the maternal and embryonic tissues by the synthesis of reactive oxygen species(ROS) which cause adsorption ,death and loss the growth and development of embryos (Tung and Winn,2011), or this result may be due to this drug causes a defect in the genes that control cartilage formation in embryonic vertebrae and also the genes which stimulate the development of the nerve cord by inhibiting nerve cells leading to embryos absorption, stopping their growth and finally the death(Wu *et al.*,2012).

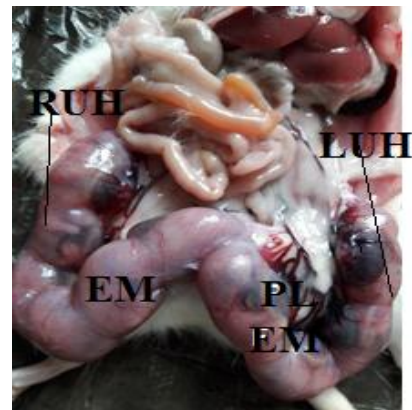
**Table 2: Depakine drug effect on some embryonic parameters.**

The Group	Numbers of embryos			
	Total	Living	Absorbed	Dead
Control	9 . 9 5 ± 0 . 0 1	9 . 9 5 ± 0 . 0 1	0 . 0 0 ± 0 . 0 0	0 . 0 0 ± 0 . 0 0
Drug	9 . 1 2 ± 0 . 0 4 *	7 . 7 5 ± 0 . 0 5 *	1 . 8 5 ± 0 . 0 4 *	1 . 6 7 ± 0 . 0 1
L.S.D	0 . 6 5	0 . 7 5	0 . 8 6	
The significant level	P <0.05	P <0.05	P <0.05	P <0.05

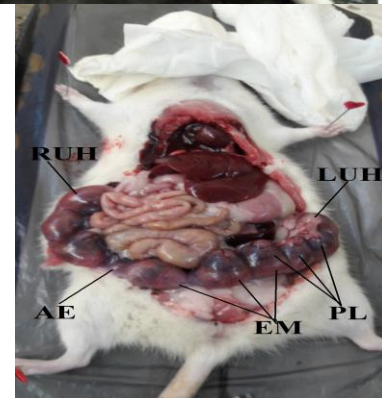
Values: represents mean ± standard error

\*:represents a significant difference with control group.

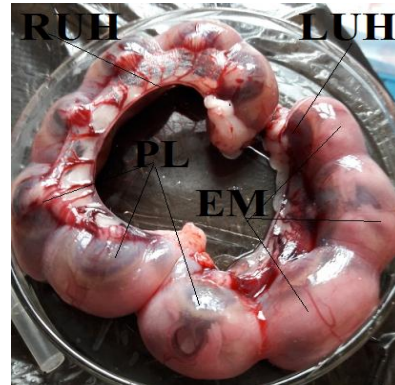
L.S.D: represents least significant difference.



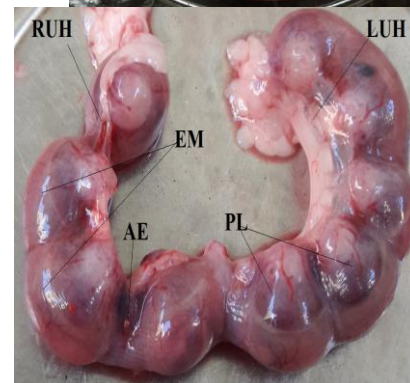**Fig(1):** pregnant female rats of control group for 18 days of pregnancy noticed: Total number of embryos in uterine horns : Left uterine horn (LUH) and right uterine horn (RUH), Normal embryos(EM) in the uterine horns, Normal placenta(PL).



**Fig(2):** pregnant female rat of treated group with depakine drug for 18 days of pregnancy noticed: Total number of embryos in uterine horns :Left uterine horn (LUH) and right uterine horn (RUH), Small embryos(EM) in the uterine horns, Small placenta(PL) ,Absorbed embryo(AE).



**Fig(3): Uterine horns of control group for 18 days of pregnancy noticed: Left uterine horn (LUH) and Right uterine horn (RUH), Normal embryos(EM) in the uterine horns, Normal placenta(PL) .**



**Fig(4): Uterine horns of treated group with depakine drug for 18 days of pregnancy noticed: Left uterine horn (LUH) and Right uterine horn (RUH), Few number and small embryos(EM) in the uterine horns, small placenta(PL) ,Absorbed embryo(AE).**

### **- Depakine drug effect on weights of body and placenta and lengths of total body and limbs of the embryos .**

The results of this study demonstrated that the weights of body and placenta and lengths of total body and limbs of the embryos for a pregnancy period of 18 days significantly decreased ( $P < 0.05$ ) in group that was injected with depakine drug as shown in figures (6,7) compared with group that was injected with normal saline of the same pregnancy period (Figure 5), and as shown in table 3, the transparencies of the skeletal structures of the fetuses revealed various structural deformities such as the survival of the structural elements in the form of cartilage and the lack of ossification of the skeletal system in general as in the figure (9), while there was little ossification of the skeletal elements, skull bone deformation, loss of tail vertebrae, some feet bones and some hand bones figure (10).

The reasons of results of low body and placenta weights may be back to the antiepileptic depakine drug stimulates the synthesis and production of free oxygen radicals especially the reactive oxygen species (ROS) that increase the oxidation of the lipids in the cellular membranes and the other cellular biomolecules as proteins, nucleic acids and carbohydrates in the tissues of pregnant animals and embryos causing increased oxidative stress that leads to oxidative breakdown and preventing or reducing the growth

and development of the various organs in them and thus their weights were reduced (Tung and Winn,2011),as well as this drug affects the processes of replication and translation of genes that form the embryonic vertebrae and inhibit the genes that stimulate development of the neural tube by discouraging the proliferation of embryonic neurons (Wu *et al.*,2012),or the reason for that may be attribute to the pathological changes in histological structure that were generated by this drug in the developing embryonic organs by the synthesis of toxic free radicals that interact with the molecules of cellular membranes and other vital cellular particles causing the damage and destruction of the histological structure of the embryonic organs and this enhances the decrease in the body weights of the embryos (Eldin *et al.*,2016), as for the decrease in the weights of the placenta may be due to the fact that the drug depakine stimulated the local death of cytotrophoblaste of the placenta by increasing of the oxidative stress which arises from the production of free oxygen radicals that cause the oxidation of the lipids in the membranes of cells and large molecules in the placental cells which enhances the oxidative breakdown of their cells and reduces the their weights,and these harmful effects of this drug on the placenta negatively affected the development and growth of the embryos because the placenta plays a major and important role in the nutrition of the embryos during pregnancy (Khera *at al.*,1993),while the decrease in total body length, limb lengths( hands and feet) and fetal skeletal deformities may be due to that although there are no adequate studies that explain the causes of these pathological changes in the skeleton of the embryos during pregnancy, so these results can be attributed to several mechanisms that were suggested to explain the effect of this drug on the skeleton which are still unconfirmed until now(Pitetzis *et al.*,2017), and the most important of them is the role of the drug depakine in the rapid destroying of vitamin D which is a fat-soluble vitamin and playd main role in bone formation , so this drug stimulates enzymes that undermine vitamin D and leading to decrease its vital action despite it is believed that this drug inhibits the enzymes responsible for drug metabolism(Perucca,2006), other studies have suggested that this drug has direct activity on osteoblasts through its effect on some bone proteins, such ascollagen type 1 and osteonectin, which perform important functions in bone formation and its mineralization stimulating the maturation of osteoblasts, therefore, the mutations in thses proteins cause deficient osteogenesis in most cases (Rauch and Glorieux,2004), while some studies (Walmod *et al.*,1999)have shown that the drug depakine affects cell morphology in fibroblasts and bone tumor which indicates the possibility of rearranging the cytoskeleton of various types of cells,as well as study of Massa *et al* (2005) showed that this drug stimulated changes in the actin filaments and the fine cytoskeleton in the embryonic somatic cells of mice that accompanied it malformations in the embryo skeleton, or vitamin D deficiency, secondary hyperparathyroidism and decreased intestinal absorption of calcium due to depakine may affect bone metabolism causing loss or less bone formation (Pack *et al.*,2003).

**Table3: Depakine drug effect on body and placenta weights and Lengths of total body and limbs(Hands and Feet ) of embryos .**

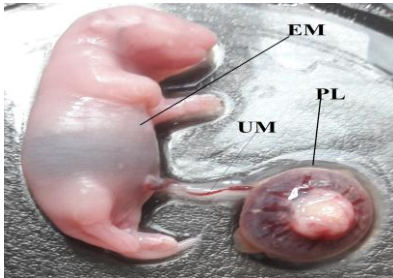
Parameters The group	Weights(gm) of		Lengths(cm) of		
	Body	Placenta	Total body	Limbs	
				hands	feet
Control	5.38±0.01	2.14±0.02	5.76±0.01	1.44±0.02	2.00±0.01
Drug	2.29±0.05*	1.01±0.03*	*0±0.003	0.99±0.04*	1.42±0.02*
L.S.D	1 . 0 2	0 . 5 5	1 . 2 1	0 . 3 3	0 . 2 5

The significant level	P <0.05	P <0.05	P <0.05	P <0.05	P <0.05
-----------------------	---------	---------	---------	---------	---------

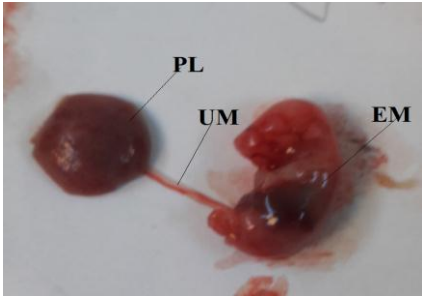
Values: represents mean ± standard error

\*:represents a significant difference about control group.

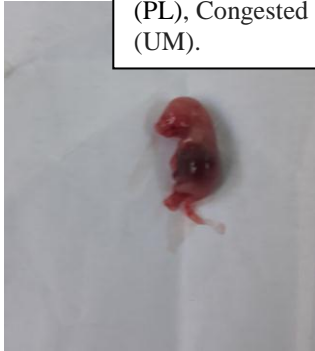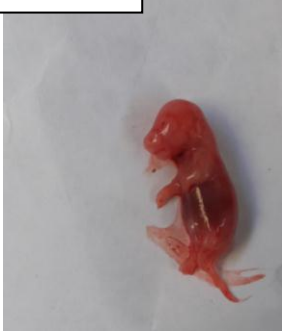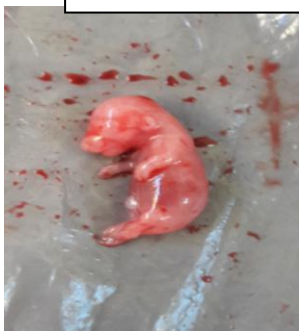L.S.D: represents least significant difference.



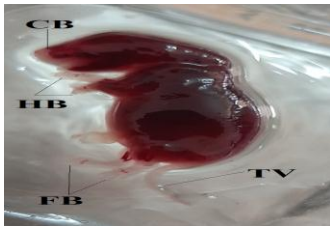
Figure(5) showing : A normal rat embryo of control group during 18-day pregnancy period (EM) , Normal placenta (PL), Normal umbilical cord(UM).



Figure(6) showing : Small and congested rat embryo of treated group with depakine drug during an 18-day pregnancy period(EM) , Small and congested placenta (PL), Congested umbilical cord (UM).

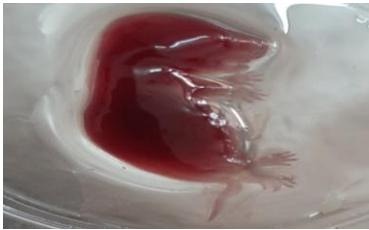


Figure(7)- showing : Small and congested rat embryos of treated group with depakine drug during 18-day pregnancy period.



Figure(8)- Embryo of control group during an 18-day pregnancy period **showing:Normal skeletal system.**

Figure(9)- Embryo of treated group with depakine drug during an 18-day pregnancy period **showing:**Loss of complete ossification of skeletal system .

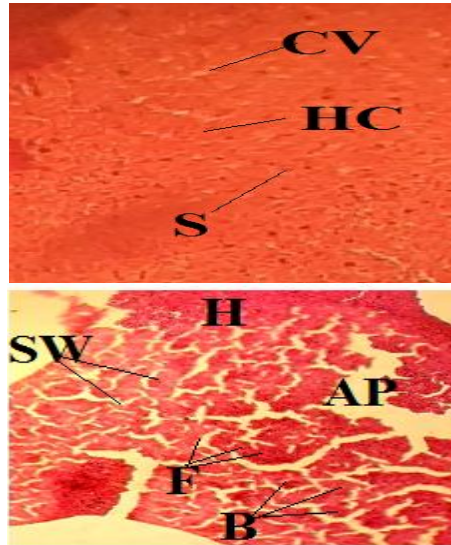


**Figure(10)- Embryo of treated group with depakine drug during an 18-day pregnancy period showing: Little ossification of the skeletal elements , Loss tail vertebrae(TV),Loss of some feet bones(HB), Loss of some hand bones(FB), Deformation of the bones of the skull(CB).**



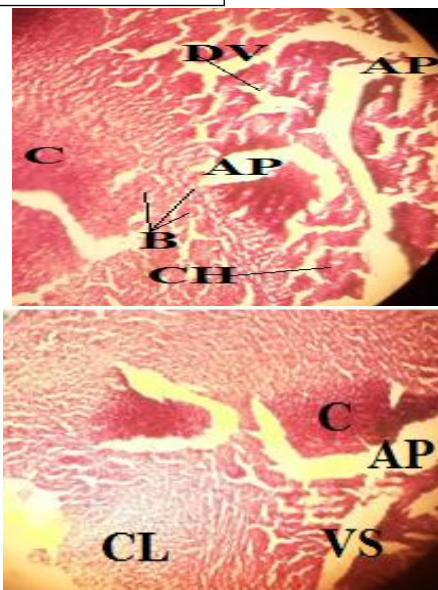
**-Depakine drug effect on hepatic -histological structure of pregnant female rats and the embryos.**

The histological sections of this study demonstrated patho-histological effects of hepatic structure which represented with expansion and vascular congestion, ballooning of liver cells, infiltration of inflammatory cells, necrosis of liver tissue, hepatic congestion, congestion and hemorrhage of central vein, damage of central vein, clearing of liver cells and sinusoids widening in livers of the pregnant female rats as shown in figures(12,13,14,15,16,17,18,19,20,21,22,23,24) and in embryos as shown in figures(26,27,28,29,30,31,32,33,34,35,36,37,38) for a pregnancy period of 18 days in treated group with depakine drug when compared with control group as shown in figures(11,25)respectively, and because of the lack of studies on the effect of the drug depakine on the histological structure on the livers of the embryos during pregnancy, therefore these results can be interpreted depending on what some studies have indicated that pointed to that the hepatotoxicity of pregnant female rats which was induced by the antiepileptic drug (depakine) is still not completely clear, but may be due to the fact that this drug affects the defense means of hepatocytes by raising the oxidative stress in the hepatic tissue through the biosynthesis of free radicals of oxygen that oxidize the lipids in cell membranes and other important cellular compounds in hepatocytes causing oxidative breakdown stimulating pathohistological changes (Pourahamad *et al.*,2012),or these hepatic- histological effects may be back to depakine drug is metabolized to toxic compounds in the liver such as 4-ene-valproate and E-2,4-diene valproate which have the ability to bind with hepatic antioxidants such as GSH and N-acetylcysteine in the hepatic cells and then they were excreted in the bile causing a decrease in self antioxidant levels (Vidya and Subramanian,2006), and the reason this result may be return to this drug and its various metabolites stimulate the stimulant factor of the proliferation of peroxisomes which were an important source for generating free oxygen radicals that cause the oxidative breakdown of hepatic tissue (Werling *et al.*,2000), or this result may be due to that depakine or its metabolic derivatives stimulate the synthesis of hydrogen peroxide (H<sub>2</sub>O<sub>2</sub>) in the hepatocyte microsomes which can pass the cell membrane to interact with iron in the cells to produce the toxic reactive hydroxyl radicals that cause adverse histopathological effects on the hepatic structure of the embryos during pregnancy (Tabatabaei and Abott,1999), or that may be attributed to the fact that antiepileptic drugs such as depakine reduce the levels of some basic elements as zinc, copper and selenium that are involved in building some antioxidants leading to a reduction in the concentrations of enzymatic antioxidants that interact with free radicals of oxygen especially glutathion reductase and GPx inducing oxidative stress as a result of a loss of balance between antioxidants and oxidant factors that create free radicals in embryonic hepatocytes stimulating the pathological changes in their hepatic tissues (Yuksel *et al.*,2001).



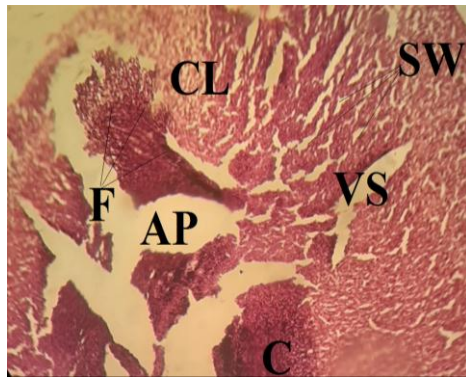
**Figure(11):-**Tissue section of pregnant female rat liver for 18 days period pregnancy of control group noticed that : Normal central vein (CV), Normal sinusoids(S), Normal hepatic cell (HC). (Hematoxylin and Eosin 100 X).

**Figure(12):-**Tissue section of pregnant female rat liver for 18 days period pregnancy of treated group with depakine drug noticed that:- Necrosis of liver tissue (AP), Sinusoids widening(SW),Ballooning of liver cells(B), infiltration of inflammatory cells (F) Hemorrhage (H), (Hematoxylin and Eosin 100 X).

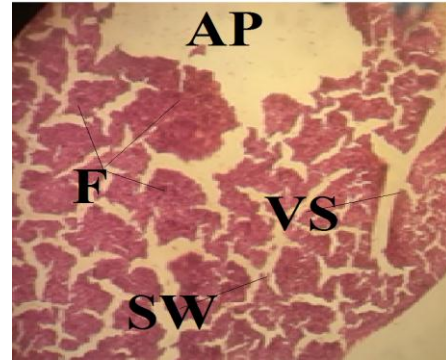


**Figure(13):-**Tissue section of pregnant female rat liver for 18 days period pregnancy of treated group with depakine drug noticed that:- Necrosis of liver tissue (AP), Ballooning of liver cells(B), Hepatic congestion (C), Congestion and Hemorrhage of central vein(CH),Damage of central vein(DV), (Hematoxylin and Eosin 100 X).

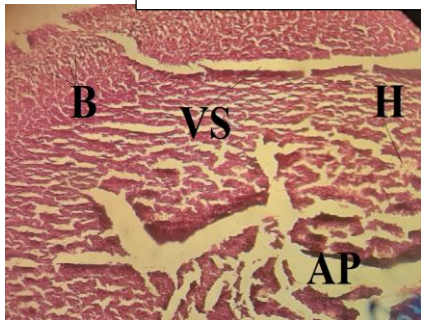
**Figure(14):-**Tissue section of pregnant female rat liver for 18 days period pregnancy of treated group with depakine drug noticed that:- Necrosis of liver tissue (AP), Hepatic congestion (C),Expansion and vascular congestion (VS),Clearing of liver cells(CL), (Hematoxylin and Eosin 100 X).



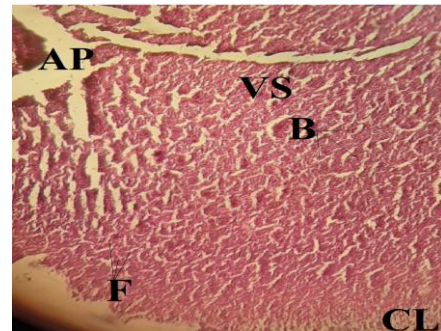
**Figure(15):-**Tissue section of pregnant female rat liver for 18 days period pregnancy of treated group with depakine drug noticed that:- Necrosis of liver tissue (AP),Expansion and vascular congestion (VS) , infiltration of inflammatory cells (F), Hepatic congestion (C), Sinusoids widening (SW), Clearing of liver cells(CL), (Hematoxylin and Eosin 100 X).



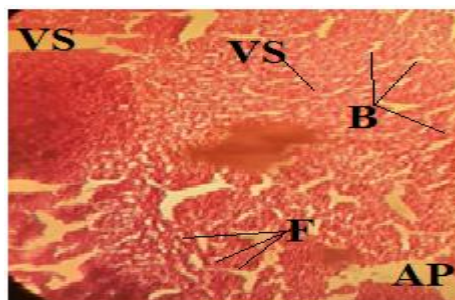
**Figure(16):-**Tissue section of pregnant female rat liver for 18 days period pregnancy of treated group with depakine drug noticed that Necrosis of liver tissue (AP),Expansion and vascular congestion (VS), infiltration of inflammatory cells (F), Sinusoids widening (SW), (Hematoxylin and Eosin 100 X).

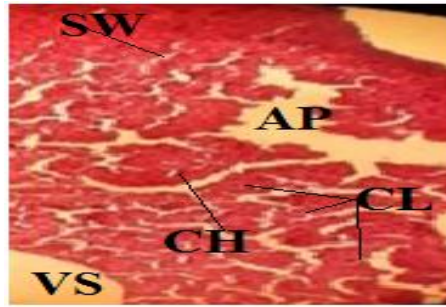


**Figure(17):-**Tissue section of pregnant female liver for 18 days period pregnancy of treated group with depakine drug noticed that:- Necrosis of liver tissue (AP), Expansion and vascular congestion (VS),Hemorrhage (H), Balooning of liver cells(B) (Hematoxylin and Eosin 100 X).



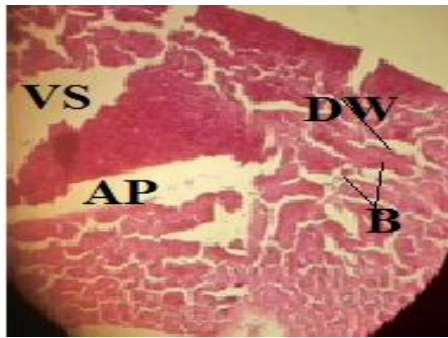
**Figure(18):-**Tissue section of pregnant female rat liver for 18 days period pregnancy of treated group with depakine drug noticed that:- Necrosis of liver tissue (AP),Expansion and vascular congestion (VS), Balooning of liver cells(B), Clearing of liver cells(CL), infiltration of inflammatory cells (F), (Hematoxylin and Eosin 100 X).



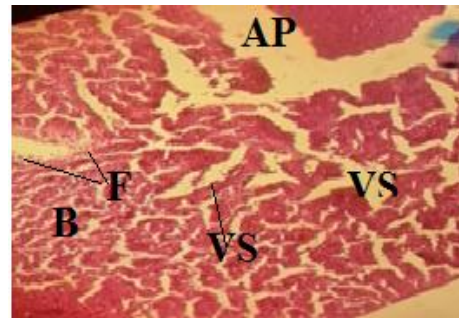


**Figure(19):-**Tissue section of pregnant female rat liver for 18 days period pregnancy of treated group with depakine drug noticed that:- Necrosis of liver tissue (AP), Expansion and vascular congestion (VS), infiltration of inflammatory cells (F), Ballooning of liver cells(B), (Hematoxylin and Eosin 100 X).

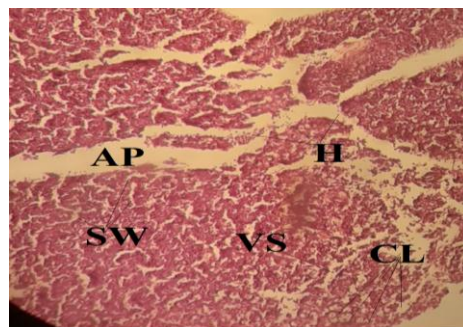
**Figure(20):-**Tissue section of pregnant female rat liver for 18 days period pregnancy of treated group with depakine drug noticed that:- Necrosis of liver tissue (AP),Expansion and vascular congestion (VS), Clearing of liver cells(CL),Sinusoids widening(SW), Congestion and hemorrhage of central vein (CH), (Hematoxylin and Eosin 100 X).



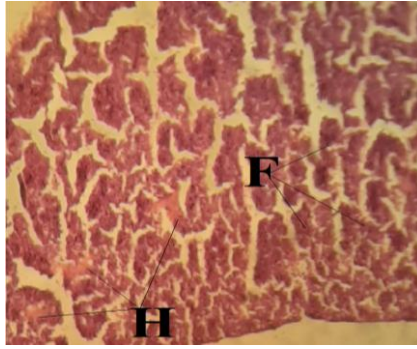
**Figure(21):-**Tissue section of pregnant female rat liver for 18 days period pregnancy of treated group with depakine drug noticed that:- Necrosis of liver tissue (AP),Expansion and vascular congestion (VS), Ballooning of liver cells(B), Damage of central vein wall (DW), (Hematoxylin and Eosin 100 X).



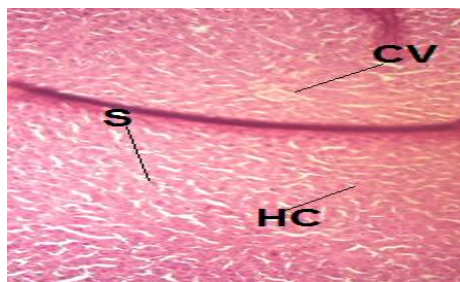
**Figure(22):-**Tissue section of pregnant female rat liver for 18 days period pregnancy of treated group with depakine drug noticed that:- Necrosis of liver tissue (AP), Expansion and vascular congestion (VS), Ballooning of liver cells(B), Infiltration of inflammatory cells (F), (Hematoxylin and Eosin 100 X).



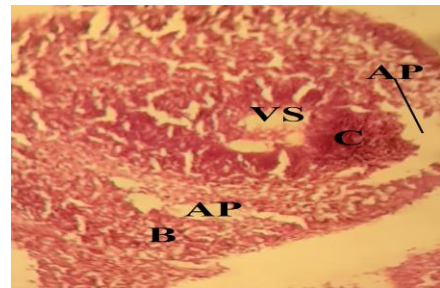
**Figure(23):-**Tissue section of pregnant female rat liver for 18 days period pregnancy of treated group with depakine drug noticed that:- Necrosis of liver tissue (AP),Expansion and vascular congestion (VS), Clearing of liver cells(CL) , Hemorrhage in liver tissue(H), Sinusoids widening (SW), (Hematoxylin and Eosin 100 X).



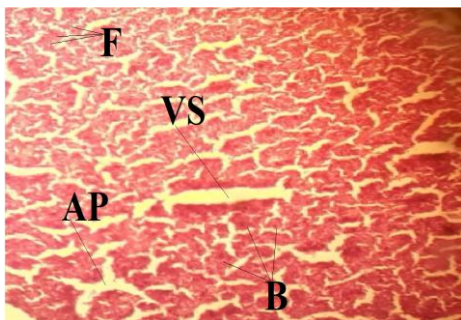
**Figure(24):-**Tissue section of pregnant female rat liver for 18 days period pregnancy of treated group with depakine drug noticed that:- Hemorrhage in liver tissue(H), Infiltration of inflammatory cells (F), (Hematoxylin and Eosin 100 X).



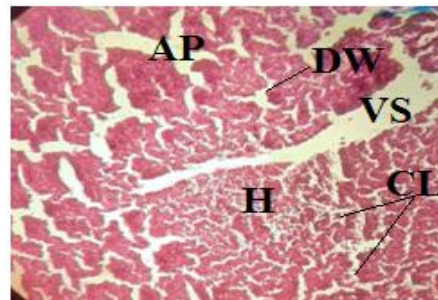
**Figure(25):-**Tissue section of embryo liver for 18 days period pregnancy of control group noticed that : Normal central vein (CV), Normal sinusoids(S), Normal hepatic cell (HC), (Hematoxylin and Eosin 100 X).



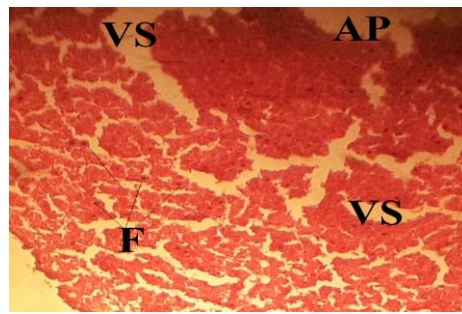
**Figure(26):-**Tissue section of embryo liver for 18 days period pregnancy of treated group with depakine drug noticed that:- Necrosis of liver tis (AP), Expantion and vascular congestion (VS),Ballooning of liver cells(B), Hepatic congestion (C), (Hematoxylin and Eosin 100 X).



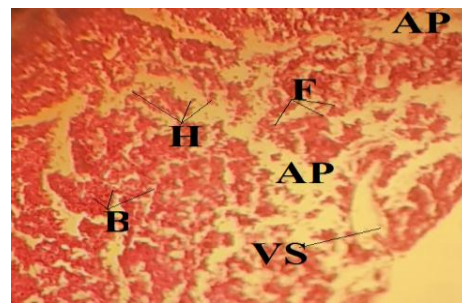
**Figure(27):-**Tissue section of embryo liver for 18 days period pregnancy of treatedgroup with depakine drug noticed that:- Necrosis of liver tissue (AP), Expantion and vascular congestion (VS), Infiltration of inflammatory cells (F),Ballooning of liver cells(B), (Hematoxylin and Eosin 100 X).



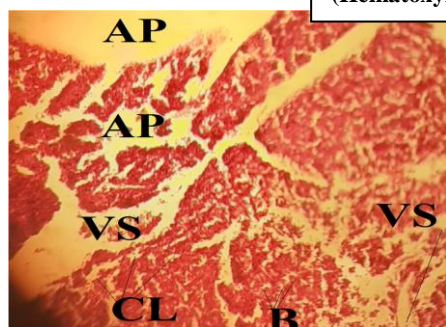
**Figure(28):-** Tissue section of embryo liver for 18 days period pregnancy of treatedgroup with depakine drug noticed that:- Necrosis of liver tissue (AP), Expantion and vascular congestion (VS), Damage of vein wall (DW), Clearing of liver cells(CL), Hemorrhage in liver tissue(H), (Hematoxylin and Eosin 100 X)



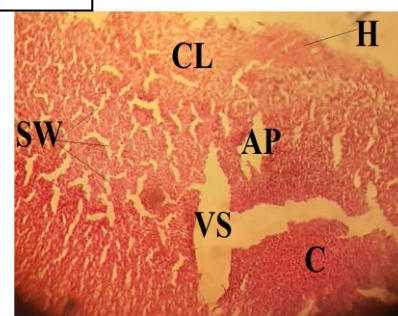
**Figure(29):-** Tissue section of embryo liver for days period pregnancy of treated group with depakine drug noticed that:- Necrosis of liver tissue (AP), Expansion and vascular congestion (VS), Infiltration of inflammatory cells (F), (Hematoxylin and Eosin 100 X).



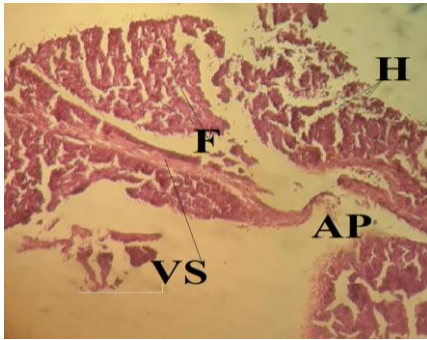
**Figure(30):-** Tissue section of embryo liver for 18 days period pregnancy of treated group with depakine drug noticed that:- Necrosis of liver tissue (AP), Expansion and vascular congestion (VS), Infiltration of inflammatory cells (F), Hemorrhage in liver tissue(H), Ballooning of liver cells(B), (Hematoxylin and Eosin 100 X).



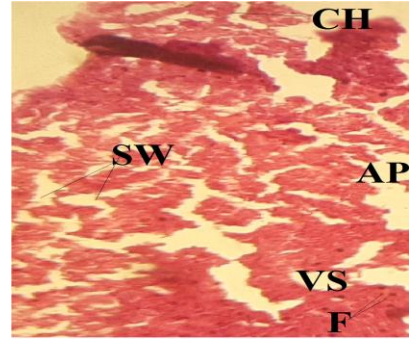
**Figure(31):-** Tissue section of embryo liver for 18 days period pregnancy of treated group with depakine drug noticed that:- Necrosis of liver tissue (AP), Expansion and vascular congestion (VS), Clearing of liver cells(CL), Ballooning of liver cells(B), (Hematoxylin and Eosin 100 X).



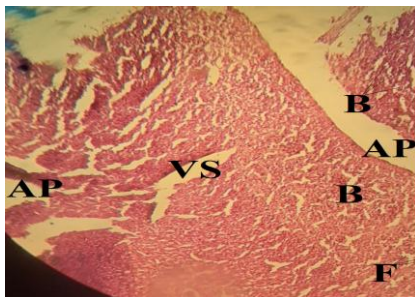
**Figure(32):-** Tissue section of embryo liver for 18 days period pregnancy of treated group with **depakine drug** noticed that:- **Necrosis** of liver tissue (AP), Expansion and vascular congestion (VS), Clearing of liver cells(CL), Hemorrhage in liver tissue (H), Sinusoids widening(SW), Hepatic congestion (C), (Hematoxylin and Eosin 100 X).



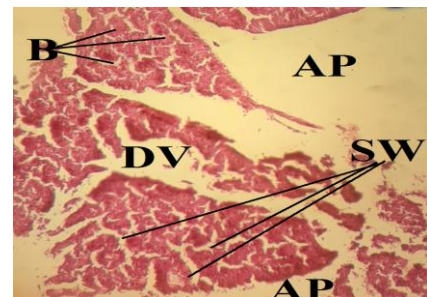
**Figure(33):-** Tissue section of embryo liver for 18 days period pregnancy of treated group with depakine drug noticed that:- Necrosis of liver tissue (AP), Expansion and vascular congestion (VS), Infiltration of inflammatory cells (F), Hemorrhage in liver tissue(H), (Hematoxylin and Eosin 100 X)



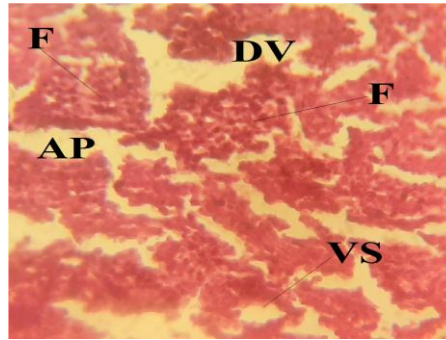
**Figure(34):-** Tissue section of embryo liver for 18 days period pregnancy of treated group with depakine drug noticed that:- Necrosis of liver tissue (AP),Expansion and vascular congestion (VS), Infiltration of inflammatory cells (F), Sinusoids widening(SW), Congestion and Hemorrhage of central vein (CH) ,(Hematoxylin and Eosin 100 X).



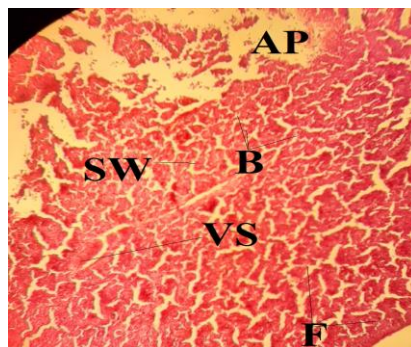
**Figure(35):-** Tissue section of embryo liver for 18 days period pregnancy of treated group with depakine drug noticed that:- Necrosis of liver tissue (AP), Expansion and vascular congestion (VS), Infiltration of inflammatory cells (F), Ballooning of liver cells(B), (Hematoxylin and Eosin 100 X).



**Figure(36):-** Tissue section of embryo liver for 18 days period pregnancy of treated group with depakine drug noticed that:- Necrosis of liver tissue (AP), Sinusoids widening(SW), Damage of central vein wall (DV), Ballooning of liver cells(B), (Hematoxylin and Eosin 100 X).



**Figure(37):-** Tissue section of embryo liver for 18 days period pregnancy of treated group with depakine drug noticed that:- Necrosis of liver tissue (AP), Expansion and vascular congestion (VS), Infiltration of inflammatory cells (F), Congestion and damage of central vein wall (DW), (Hematoxylin and Eosin 100 X).



**Figure(38):-** Tissue section of embryo liver for 18 days period pregnancy of treated group with depakine drug noticed that:- Necrosis of liver tissue (AP),Expansion and vascular congestion (VS), Infiltration of inflammatory cells (F), Ballooning of liver cells(B), Sinusoids widening(SW), (Hematoxylin and Eosin 100 X).

**- - References**

- [1]. 1-Ayano ,G.(2016). Bipolar Disorders and Valproate: Pharmacokinetics,Pharmacodynamics, Therapeutic Effects and Indications of Valproate. Bipolar. Disord.,2(2):109.
- [2]. 2 -Eldin,E.N.; Elshebiny,h.A-F. Mohamed,T.M. and Abdel-Aziz , M.A-A.(2016). The role of antiepileptic drugs in free radicals generation and antioxidant levels in epileptic patients. Intel. J . Neuro .Science .,126(2):105-115.



- [3]. **3-** Cheng,D.; Yan,X.; Yan ,X.; Xu ,K.; Zhou,X. and Chen ,Q.(2020).The effect of interictal epileptiform discharges on cognitive and academic performance in children with idiopathic epilepsy.B.M.C Neurology ., 20: 233.
- [4]. **4-** Cho,Y.W. and Kim,K.T.( 2019). The Latest Classification of Epilepsy and Clinical Significance of Electroencephalography. J. Neurointensive. Care ., 2(1): 1-3.
- 5-**Cook,A.M. and Bensalem-Owen,M.K.(2011). Mechanisms of action of .[5] antiepileptic drugs. Therapy ., 8(3): 307–313.
- [6]. **6-**Ghodke-Puranik, Y.; Thorn ,C.F.; Lamba,j.k.; Leeder,J.S.; Song,W., Birnbaum ,A.K.; Altman,R.B.and Klein,T.E.(2013). Valproic acid pathway: pharmacokinetics and pharmacodynamics. Pharmacogenet.Genomics.23(4):236-241.
- [7]. **7-**Khera, K.S. (1993). Valproic acid – induced placental and teratogenic effects in rats. Teratology, 47(1): 1-9.
- [8]. **8-**Kumar, S.; Wong, H.; Sam, A.Y.; Riggs, K.W.; Abbott, F.S.and Rurak, D.W. (2000). Disposition of valproic acid in maternal, fetal and new born sheep I: placental transfer, plasma protein binding, and clearance. Drug. Meta.Despos., 28(7):845-856.
- [9]. **9-** Macfarlane ,a. and Greenhalgh,T.(2018). Sodium valproate in pregnancy: What are the risks and should we use a shared decision-making approach? BMC Pregnancy and Childbirth., 18(1): 200-211.
- [10]. **10-** Massa, V.; Cabrera, R.M.; Menegola, E.; Giavini, E. and Finnell, R.H. (2005).Valproic acid-induced skeletal malformations: associated gene expression cascades. Pharmacogenet. Genomics ., 15(11):787–800.
- [11]. **11-** Nagalakshmi ,N.C.;Ramesh,M.;Parthassar,G.;Harugeri,A.;Christy,M.S and Keshava,B.S. (2010).Valproic acid –induced abnormalbehavior.Indian.J.Psychiatry.,52(1):71-73.
- [12]. **12-**Ornoy A. (2009). Valproic acid in pregnancy: How much are we endangering the embryo and fetus? Reproductive Toxicology, 28 : 1–10.
- [13]. **13-**Pack, A.M.;Olarate, L.S.; Morrell, M.J.; Flaster, E.; Resor, S.R. and Shane, E. (2003).Bone mineral density in an outpatient population receiving enzyme-inducing antiepileptic drugs. Epilepsy .Behav .,4(2):169–74.
- [14]. **14-** Perucca, E. (2006).Clinically relevant drug interactions with antiepileptic drugs. Br .J .Clin .Pharmacol., 61(3):246–55.
- [15]. **15-** Pitezisa ,D.A.; Spiliotia,M.G.; Yovosb,J.G. and Yavropouloub,M.Y.(2017). The effect of VPA on bone: From clinical studies to cell cultures—The molecular mechanisms revisited.Seizure.,48:63-43.
- [16]. **16-**Pourahmad, J.; Eskandari, M.R.; Kaghazi, A.; Shaki, F.; Shahraki, J. and Fard, J. K. (2012). A new approach on valproic acid induced hepatotoxicity: Involvement of lysosomal membrane leakiness and cellular proteolysis. Toxicology in Vitro., 26: 545–551.
- [17]. **17-**Rauch, F. and Glorieux, F.H.( 2004). Osteogenesis imperfecta. Lancet.,363(9418):1377– 85.
- [18]. **18-** Suvarna,S.K.;Lyaton,C. and Bancroft,J.D.(2013). Bancrofts theory and practice of histological technique.7ed .Elsevier.Limited . , China.Xiv\_604.
- [19]. **19-**Tabatabaei, A.R. and Abbott, F.S. (1999). Assessing the mechanism of metabolism dependent valproic acid induced in vitro cytotoxicity. Chem. Res. Toxicol, 12(4): 323-330.

- [20]. **20-**Tung, E.W.Y.and Winn, L.M. (2011). Valproic acid increases formation of reactive oxygen species and induces apoptosis in postimplantation embryos: a role for oxidative stress in valproic acid-induced neural tube defects. *Molecular Pharmacology*, 80 (6): 979-987.
- [21]. **21-** Tolou-Ghamari, Z. and Palizban,A.A.(2015). Review of Sodium Valproate Clinical and Biochemical Properties. *Zahedan. J. Res. Med Sci.* ,2015 ,17(8): 2207.
- [22]. **22-**Walmod, P.S.; Skladchikova, G.; Kawa, A.; Berezin, V. and Bock, E.(1999). Antiepileptic teratogen valproic acid (VPA) modulates organisation and dynamics of the actin cytoskeleton. *Cell Motil, Cytoskelet.*,42(3):241–55.
- [23]. **23-**Van Mil, N. H.; Oosterbaana, A. M. and Steegers-Theunissen, R. P (2010). Teratogenicity and underlying mechanisms of homocysteine in animal models: A review. *Reproductive Toxicology*, 30: 520–531.
- [24]. **24-**Vidya, M.and Subramanian, P. (2006). Effects of  $\alpha$ -ketoglutarate on antioxidants and lipid peroxidation products in rats treated with sodium valproate. *J. Appl. Biomed.*, 4: 141–146.
- [25]. **25-**Werling, U.; Siehler, S.; Litfin, M.; Nau, H.; Gottlicher, M. (2001). Induction of differentiation in F9 cells and activation of peroxisome proliferator-activated receptor delta by valproic acid and its teratogenic derivatives. *Mol. Pharmacol.*, 59(5):1269-76.
- [26]. **26-**Wu, M.; Khan, I.A. and Dasmahapatra, A. K. (2012). Valproate-induced teratogenesis in Japanese rice fish (*Oryzias latipes*) embryogenesis. *Comparative Biochemistry and Physiology, Part C* 155: 528–537.
- [27]. **27-**Yaping,J.;Shuhua,X.;Xin,L.;Chunwei,L.;Gexin, L.;Yuanyuan,X.;Chunqing,Q.;Yuhong,N. and Guifan,S .(2006).Arsenic speciation transported through the placenta from mother mice to their newborn pups.*Environmental.Research.*,(101):349-355.
- [28]. **28-**Yukserl, A.; Cengiz, M.; Seven, M. and Ulutin, T. (2000). Erythrocyte glutathion, glutathion peroxidase, super oxide dismutase and serum lipid peroxidation in epileptic children with valproate and carbamazepine. *J. Basic. Clin. Physiol. Pharmacol.*, 11(1):62-64.