

Perosseous Osteosynthesis Andbone Plasty During The Treatment Of The Patients Opens Fractures Of Long Bones With The Extensive Defects Of Bone Tissue

Davirov Sharof Mazhidovich¹, Urinboev Payzulla Urinboevich²

¹Orthopedic traumatologist, Samarkand branch of the Republican Specialized Scientific and Practical Medical Center for Traumatology and Orthopedics, Samarkand, Uzbekistan.

²Doctor of Medicine, professor, Samarkand State Medical Institute, “Traumatology and Orthopedics”Department.

E-mail: sharofd1976@mail.ru

Abstract: Introduction. In practice, an open comminuted fracture treatment severity of long bones, with an extensive defect in the diaphysis bone tissue, the bone metadiaphyseal part, is due to an increased risk combination of developing infectious complications due to an open infected wound, with the need to restore a significant volume of bone tissue, to connect the proximal and distal fragments of long bones. Internal osteosynthesis of bone fragments is impossible due to the lack of the required diaphysis bone tissue volume, the bone meta-diaphyseal part, necessary to restore the normal bones length, and performing open reduction, immediately after trauma, negatively affects blood supply, leads to the complications development such as soft tissue necrosis, infection, and suppuration. The article describes the staged fracture treatment method with the defect replacement with autobone, while maintaining the limb length, reducing the developing pathological risk processes.

Purpose of the study – to study the open double comminuted fractures treatment effectiveness of the patient's long bones, with an extensive defect in the diaphysis bone tissue or bone meta-diaphyseal part, by staging the transosseous fixation use with Ilizarov or the rod-rod apparatus, bone grafting with a fibula graft according to the classical technique and intramedullary osteosynthesis.

Results and discussion. A temporary transosseous extrafocal limb fixation was performed with Ilizarov or the wire-rod apparatus until the acute period subsided, edema decreased, and blood circulation improved. The fibula was harvested with a length suitable to the defect site. Intramedullary metal osteosynthesis or internal osteosynthesis with smooth wires and an apparatus for external fixation of long bones with the bone defect replacement with an autologous bone from the fibula was performed. After bone fusion, external fixators, metal intramedullary implants and internal wires were removed. Achieved preservation of

the anatomical segment length, satisfactory restoration of limb function, all fixing structures were removed, and the limb does not contain foreign bodies.

Conclusion. The various techniques and technical facilities combination, external fixation, autotransplantation using the classical technique and intramedullary fixation, made it possible to completely restore the injured limb, reduce the complications risk, and obtain good clinical results.

Key words: trauma, open fractures, bone tissue defect, autobone, combination of techniques.

1. INTRODUCTION

One of the most important tasks in modern osteoplastic surgery is the question of replacing extensive defects in long bones that have arisen after open fractures of long bones with a defect in bone tissue. The restoration of bone tissue in the area of the defect is an urgent medical and social problem. According to A. V. Sklifosovskiy research institute of emergency medicine, open fractures in 5.9% cases are complicated by the osteomyelitis occurrence, and in combined case, multiple injuries, its frequency increases to 18-61% [1].

According to N.M. Klyushin (2019), osteomyelitis develops with open fractures consequences in 5.3-75.4%, after gunshot fractures in 34.2-82.3%, after planned orthopedic and traumatological operations in 1.5 -33.2%. In more than 87% cases, the chronic purulent process is combined with various orthopedic and traumatological pathologies, which in 97% are accompanied by bone defects as a result of bone loss due to trauma, surgical accommodations and its destruction [2].

With extensive diaphyseal or metadiaphyseal defects of long bones, the implementation of internal osteosynthesis of the remaining fragments is impossible, due to the lack of the required volume of bone tissue of the diaphysis or metadiaphyseal part of the long bones, and the implementation of open reduction, immediately after an open injury, negatively affects the blood supply, leads to the development of complications such as soft tissue necrosis, infection, suppuration.

There is no single standard definition of a critical size defect. Defects can be assessed in both relative and absolute terms, and they can vary depending on the animal or human model. In general, a "critical size" defect is considered a defect that does not heal spontaneously despite surgical stabilization and requires further surgical intervention [3].

It is generally accepted that a "bone defect" is the absence of bone for more than 2 cm. According to V.I. Shevsov and co-authors (1996), any bone defect is considered a bone defect, regardless of the size and size of the defect.

In clinical practice, post-traumatic (loss of bone fragments at the time of injury, resection of contaminated ends, after removal of free-lying contaminated or sequestered fragments of various sections) bone defects are formed in 60% of cases [4,5,6,7,8,9].

Treatment of long bone defects remains a serious clinical and socioeconomic problem. There are no agreed guidelines and treatments for such defects vary greatly. Therefore, clinicians

and researchers are currently exploring ways to treat large bone defects based on tissue engineering approaches. Tissue engineering strategies for bone regeneration seem to be a promising option for regenerative medicine [10].

Bone defects associated with non-union are the result of initial damage or as a consequence of the excision of the bone after the development of non-union. Historically, the management of this clinical scenario has been largely amputation, which provides a short recovery period but significant loss of limb function. Today, therapies have evolved and there are now many options available to repair a bone defect. In a broad sense, these are: shortening of the bone followed by lengthening or transportation and "docking" of the bone (methods based on distraction osteogenesis); the use of vascularized and non-vascularized bone grafts; bone substitutes; stem cells; growth factors; scaffolds and gene therapy. [11].

Studies by E.A. Anastasiev et al (2017) showed that in the course of treatment tactics, it is first necessary to determine: whether the size of the defect and its shape allow the use of an autograft. The most preferred option is to use your own tissue to fill the bone defect. In the absence of autologous material in the required amount, its combination with an allograft is permissible [12].

Research by Logan M. Lawrence (2019) with co-authors proves that isolation and culture of bone marrow mesenchymal stem cells will have a positive effect, where conditions arise for filling significant bone defects and nonunion fractures [13].

A unique feature of distant osteogenesis is the ability to fully induce the formation of new bone at the site of the defect. This procedure consists of three successive phases: latent phase after osteotomy and external fixation; distraction phase; and the phase of consolidation. [14] Traumatologists-orthopedists, as the most effective and alternative method, prefer non-free bone grafting according to G.A. Ilizarov and replantation of a vascularized or free autograft into the defect [15].

Various technologies are used to replace defects in the tibial shaft. When replacing extensive defects in the diaphysis of the long bones of the extremities, Ilizarov method is widely used, which implies lengthening the proximal fragment, distal fragment, or two fragments of the tibia at once [16].

The method of perosseous distraction osteosynthesis, the fundamental substantiation and practical development of which was performed by G.A. Ilizarov, allows achieving significant values of elongation of long bones with simultaneous elimination of their deformities [17-18].

The disadvantages of the method for replacing a bone defect in long tubular bones with lengthening of a fragment according to G.A. Ilizarov include the duration of the patient's treatment, the inconvenience for the patient and the need for constant monitoring of the patient. The lack of the inpatient observation possibility due to the long term lengthening, on average 3-4 months in patients with extensive diaphyseal bone defects. Therefore, various other methods and their combination are used in order to provide quality treatment, but with

less time. However, this technique is considered the most biological method for replacing defects.

Based on experience, Ilizarov grafts and peroneal vascular grafts are not an alternative, as is often reported in the literature. Their combined use, especially in lesions classified as Wingquist IV B, may represent an effective tool in the surgeon's hands for dealing with the most difficult cases of acute bone loss caused by severe high-energy trauma [19].

Currently, there are two main approaches to the reconstruction of extensive bone defects - the use of bone grafts (auto-, allo-, and xenografts) or tissue-engineered constructions. A tissue engineering strategy of incorporating cells into the matrix represents a promising alternative for the treatment of bone damage. This strategy consists of three main blocks: cells, matrices (scaffolds) and osteoinductive growth factors. [20].

It is known the methods of replacing long bone defects, involving the auto-, allo-, xenografts, as well as explants use.

A freely vascularized peroneal graft is a widely used source of viable bone for covering skeletal defects larger than 6 cm and has important advantages over other donor sites of vascularized bone tissue [21].

According to A.P. Barabash (2014), operations with the bone grafting or prostheses use make it possible to provide the supporting limb function for up to 20 days. However, the use of metal implants also has several disadvantages. First of all, titanium implants and prostheses in their mechanical properties do not correspond to the mechanical properties of the bone, to restore the integrity of which they are used. A metal implant, the prosthesis is more rigid, is not able to elastically deform when the load is perceived and is not able to naturally transfer forces from the proximal fragment of the tibia to the distal fragment of the tibia and vice versa. Metal implants are superior in hardness to bone tissue; as a result, bone tissue resorption is observed in the metal-to-bone contact zone, which can lead to loosening of the metal prosthesis, implant and loss of fixation stability [22].

The article describes the patients' staged treatment with open double comminuted fractures of long bones with an extensive defect replacement with a various sizes in length, preserving the limb segment length, and reducing the developing pathological risk processes during treatment.

Objective: Study of patients' treatment effectiveness with open double comminuted fractures of long bones in patients with an extensive defect in the diaphysis bone tissue or bone metadiaphyseal part, by staging the perosseous fixation use with Ilizarov or a spoke-rod apparatus, bone grafting with a fibular graft according to the classical technique and intramedullary osteosynthesis.

2. MATERIALS AND METHODS.

It was studied 22 patients' treatment results who were treated in a specialized department of bone-purulent complications in 2015-2020. The patients were divided into two groups. The first group consisted of 16 patients treated for open fractures with a long bones defect, in whom bone grafting was applied. From these, 6 patients had fractures of the humerus, 3 patients with fractures of the forearm bones, 2 patients with fractures of the femur and 5

patients with fractures of the shin bones. From 16 sick there were 7 women (43.8%), 9 men (56.2%). Distribution of patients by age: 18-25 years old - 3 patients (18.8%), 26-35 years old 7 patients (43.8%), 36-49 years old 4 patients (25%), over 50 years old 2 patients (12.5%). The second group consisted of 6 patients who were treated without the use of bone grafting. Among them, 1 patient had fractures of the humerus, 5 patients had open fractures of the shin bones with a bone defect. Out of 6 sick patients women were 1 (16.7%), men were 5 (83.3%). Distribution of patients by age: 18-25 years old 3 patients (50%), 26-35 years old also 3 patients (50%). Most of the patients were men (14) of working age (18-50 years). The main causes of damage to the long bones were road traffic accidents (high-energy direct mechanism of injury). Anatomical and functional changes, dangling mobility and axial deformity of the segment were determined in all patients. Fractures of other segments of the skeleton were noted in two patients, and concomitant injury was noted in one patient.

So far, many different classifications of open fractures have been proposed by different authors. We assigned patients according to Gustilio-Anderson classification of open fractures. [23].

Distribution of the first group patients according to open fractures classification as Gustilio-Anderson.

Type	Number of patients, people	Patient percentage%
I	0	0
II	3	18,75
IIIA	11	68,75
IIIB	2	12,75
IIIC	0	0

Distribution of the second group patients according to open fractures classification as Gustilio-Anderson.

Type	Number of patients, people	Patient percentage%
I	0	0
II	1	16,7
IIIA	4	66,7
IIIB	1	16,7
IIIC	0	0

This classification was acceptable for us and gave us the opportunity to assess the open injuries severity and the choice of rational treatment methods.

The great importance in the treatment of an open comminuted fracture of long bones, with a general defect in the bone tissue of the diaphysis or metadiaphyseal part of the bone, is a full-fledged surgical treatment of soft tissue and bone wounds carried out at the earliest possible date after the injury. It should be radical, end with stable external fixation of fragments of

long bones with the creation of favorable conditions for microcirculation in the tissues of the injured limb.

For patients with fractures of the humerus and forearm bones, a plaster cast was applied; preoperative preparation was carried out for 5-7 days. Skeletal traction system was applied to patients with fractures of the femur and lower leg bones, and preoperative preparation was carried out for 10-12 days. After preliminary preparation, the first stage of the operation was carried out.

At the first stage, extrafocal perosseous fixation of long bones was performed using Ilizarov apparatus or the wire-rod apparatus (Fig. 2 Fig. 8) without eliminating the defect according to a known technique while maintaining the anatomical length of the segment. With the support and apparatus pins, minimally invasive closed reposition of fragments of long bones was performed, the normal anatomical length of the segment was restored, and the curvature of the longitudinal axis of the limb segment was eliminated. Surgical treatment of soft tissue wounds was performed. The patient was activated and monitored.

When an infectious process signs appear in the wound, after laboratory tests, an antibiotic therapy course is prescribed, infectious processes are arrested.

After the wound healed, which, depending on the wound size and condition, took from 3 weeks to 10 weeks, the second stage of surgical treatment was performed. On average, after 7 weeks, the bone defect was replaced with an autologous bone of the fibula, with ends fixation with a fragment with crossing needles, fixation with an external fixation apparatus.

Clinical example. №1. Patient Z.M. 1989 year of birth was injured as a result of a fall from a height, 08.15.2016. The patient underwent radiation and clinical examination. An open comminuted double fracture of the forearm bones was diagnosed, with an extensive bone defect in the bone tissue of the shaft of the ulna. Type II according to the classification of open fractures according to Gustilio-Anderson, with the length of the bone tissue defect exceeding 11 cm (Fig. 1) The first stage was extrafocal perosseous fixation of the forearm bones with Ilizarov apparatus (Fig. 2) after injury on 3 day without removing the defect according to a known technique, while maintaining the anatomical length of the segment. With the support and pins of the apparatus, minimally invasive closed reduction of fragments of long bones was performed, the normal anatomical length of the segment was restored, and the curvature of the longitudinal axis of the forearm was eliminated.

To replace the bone defect of the ulna, an 11 cm was made a long fibula 73 days after the first stage of the operation. On the larger surface of the graft, the periosteum and muscle segments attached to it were preserved. The surfaces of bone fragments touching the graft are cleaned and refreshed to bleed. We think these details contribute to the improvement and restoration of the nutrition of the graft. Ilizarov apparatus was dismantled from the forearm, intramedullary metal osteosynthesis of the forearm bones was performed, and a fragment of the fibula was fixed in the area of the bone defect. To fix the position of the autograft and mechanical connection of the proximal and distal fragments of the ulna, a smooth Bogdanov pin was used. The post was passed retrogradely through the olecranon into the intramedullary

canal of the autograft and the distal fragment of the ulna. Stable fixation of the ulna fragments and the graft was achieved by intramedullary osteosynthesis. (fig. 3.)

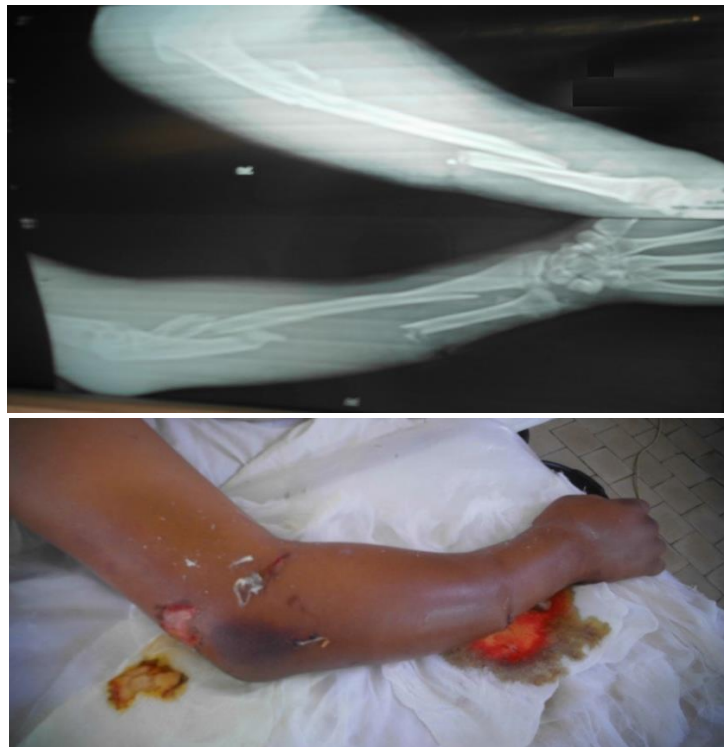

Figure: 1 Radiographs and photos of the right forearm, patient Z.M., 27 years old, on admission day. 15.08.2016.




Figure: 2 X-ray of the right forearm of patient Z.M., 27 years old, after the first stage of the operation, the use of Ilizarov apparatus. 08/18/2016

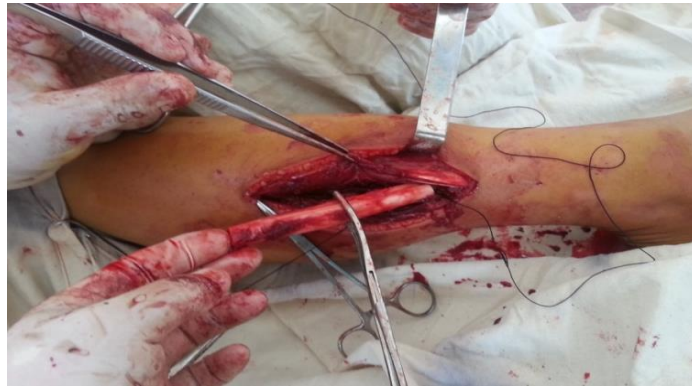

Figure: 3. The second stage of the operation. Photo of 11 cm long autologous bone from the fibula taken from patient Z.M, 27 years old. 30.10.2016

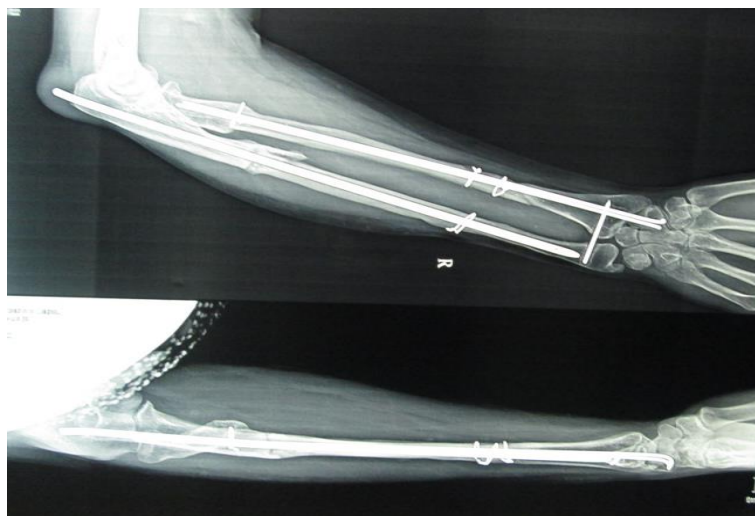


Figure: 4. Radiographs of the right forearm of the patient Z.M., 27 years old, after intramedullary osteosynthesis, in dynamics, 08.26.2018.

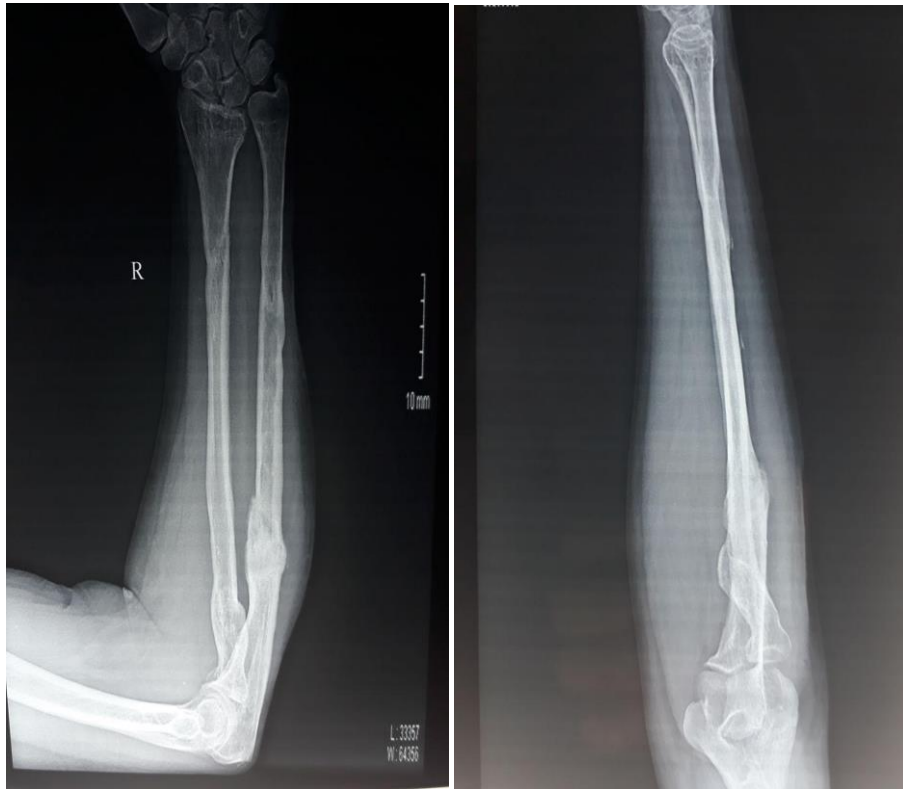
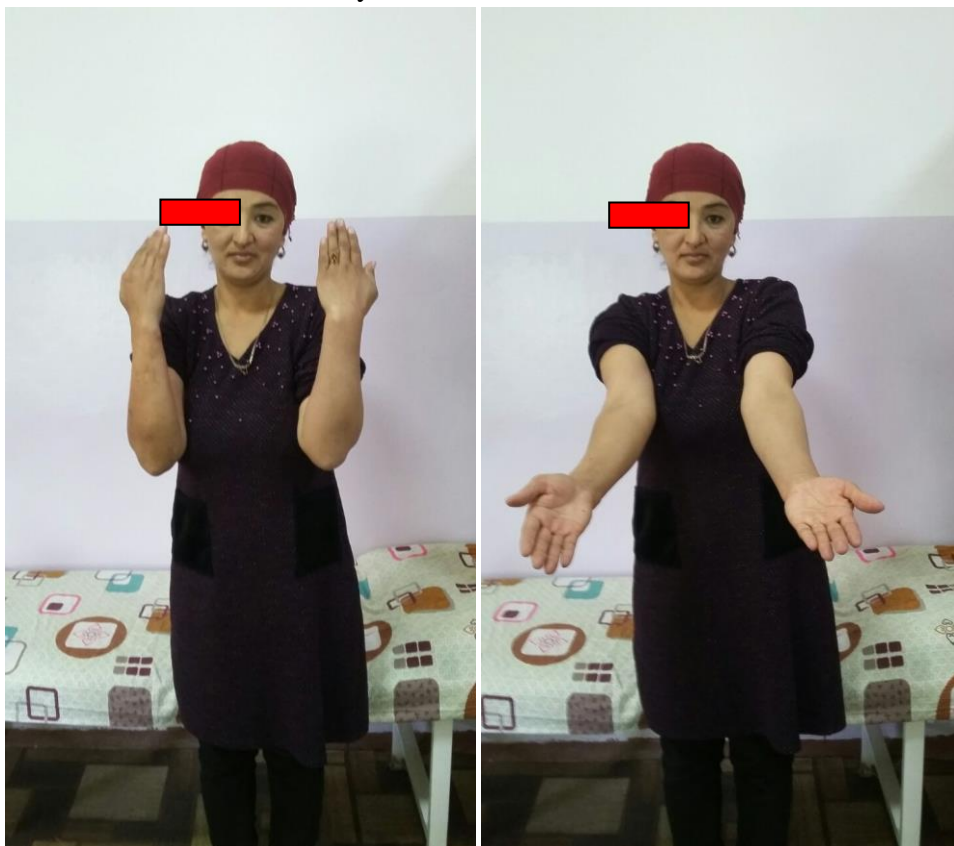
Figure: 5. Radiographs of the right forearm of patient Z.M., 27 years old after treatment, in dynamics 12.25.2019.



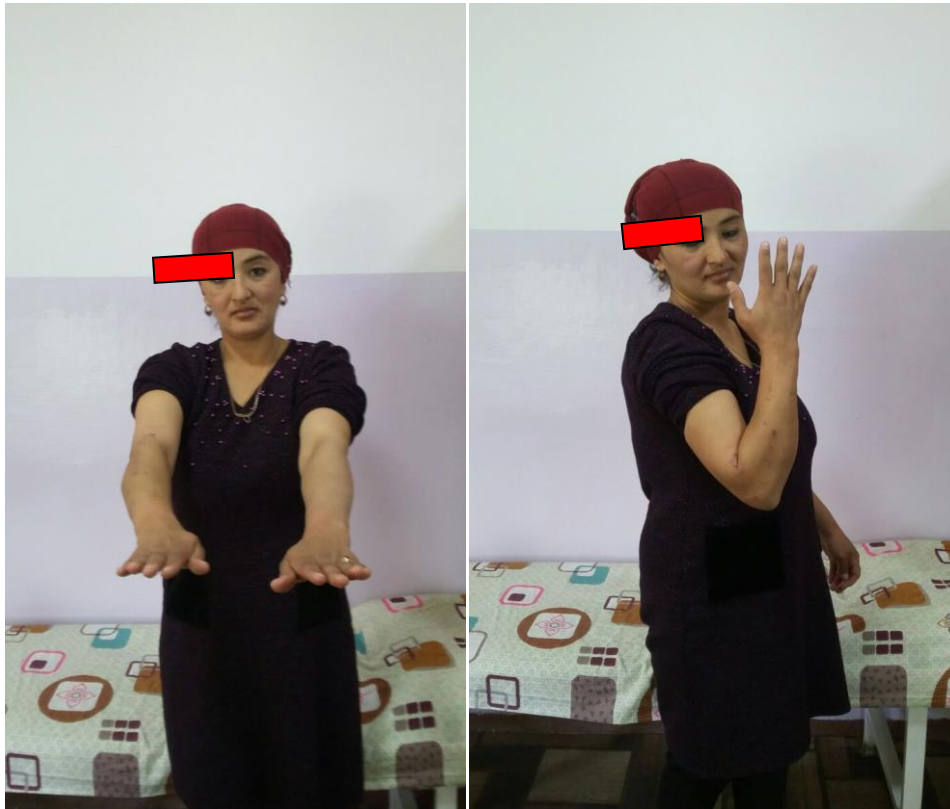

Fig. 6. The appearance of the patient Z.M., 27 years old and the function of the limb - 25.12.2019

Clinical example. №2. We present a clinical observation with a long-term 4 years result. Patient S.K. who was born in 1994, was injured as a result of a road traffic accident on 29.09.2016. She received on 10.10.2016. The patient underwent radiation and clinical examination. An open comminuted double fracture of the left humerus with a large defect of the meta-diaphysis of the humerus was diagnosed. An open fracture of the left olecranon and an open comminuted fracture of the ulna in the middle third. Sutured wound on the back of the left forearm, with signs of inflammation. Type II according to the classification of open fractures according to Gustilio-Anderson (Fig. 7)

In the first stage of treatment, extrafocal perosseous fixation with a wire-rod apparatus was performed, while maintaining the length of the limb without eliminating the defect in 10.12.2016. Minimally invasive closed reposition of bone fragments was performed with the rods and pins of the apparatus, the normal length of the segment was restored, and the curvature of the longitudinal axis of the limb segment was eliminated (Fig. 8). To replace the bone defect of the humerus, 7 weeks after the first stage, the operation was performed: transplantation of the fibula 24 cm long, according to the classical technique, replacement of the bone defect.

Fixation of the ends with a fragment was carried out with crossing needles, external fixation with Ilizarov apparatus and a rod (Fig. 9A, Fig. 9B). After fusion of the autograft and bone fragments, the wire-rod apparatus was dismantled, the wires were removed through mini-incisions (Fig. 10).

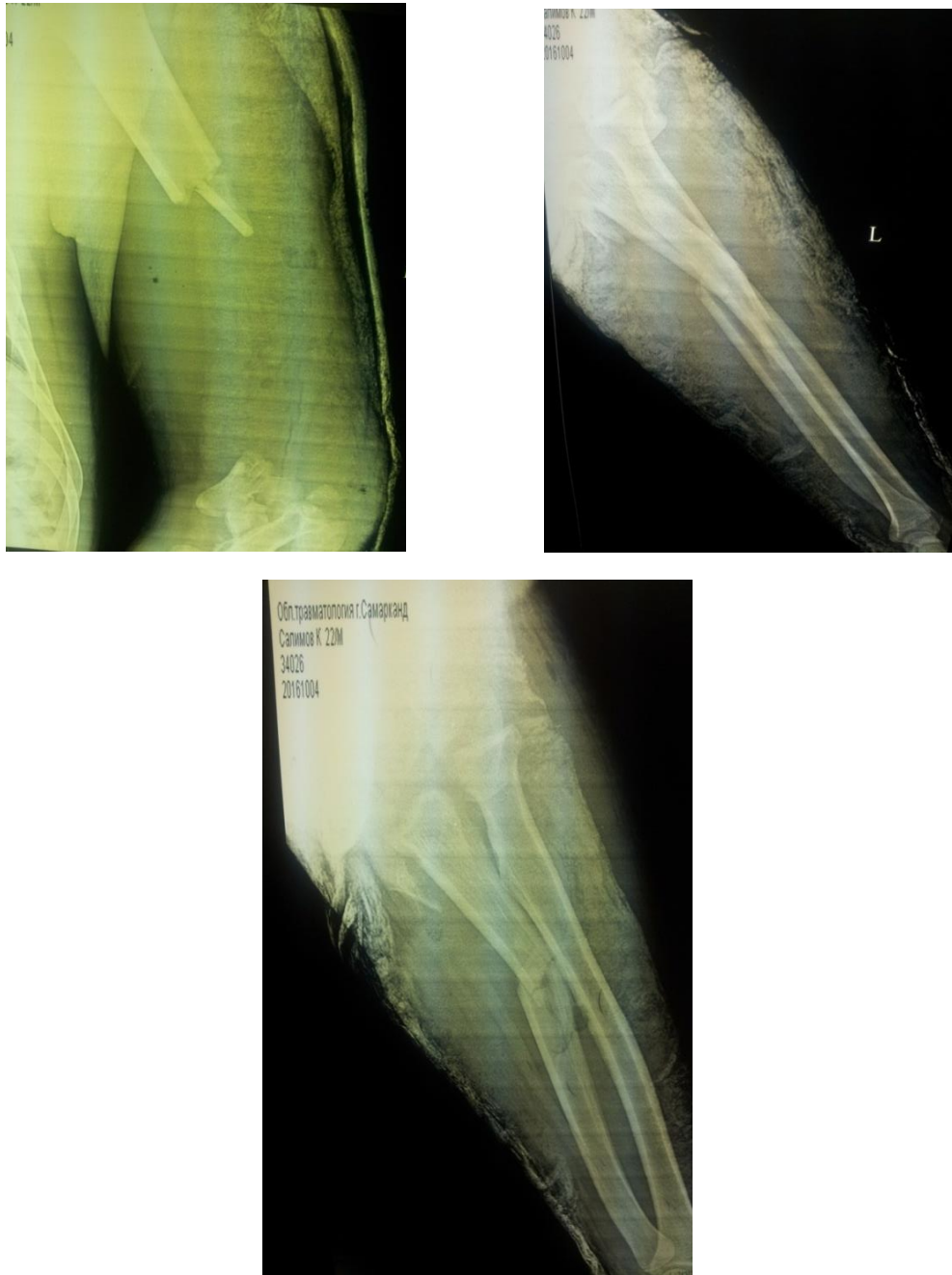


Fig. 7. Radiographs of the left humerus and bones of the left forearm, patient S., born in 1994, upon admission on 10.10.2016.

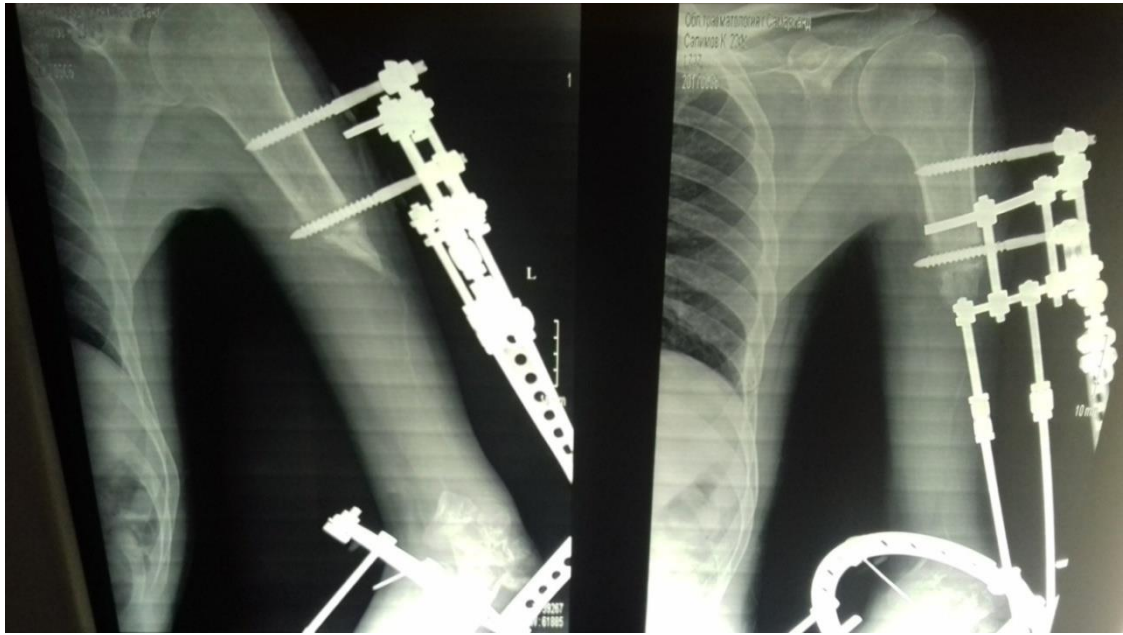
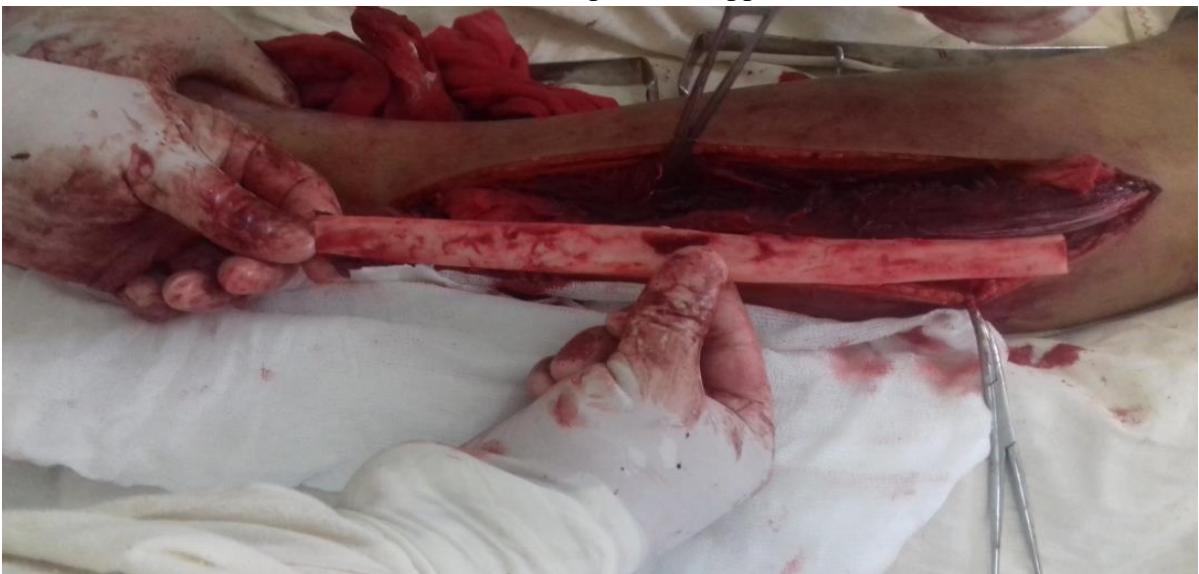

Fig. 8. Radiographs of the left humerus and left forearm bones of the patient S.K. 1994 year of birth, after installation of the spoke-rod apparatus. 12.10.2016



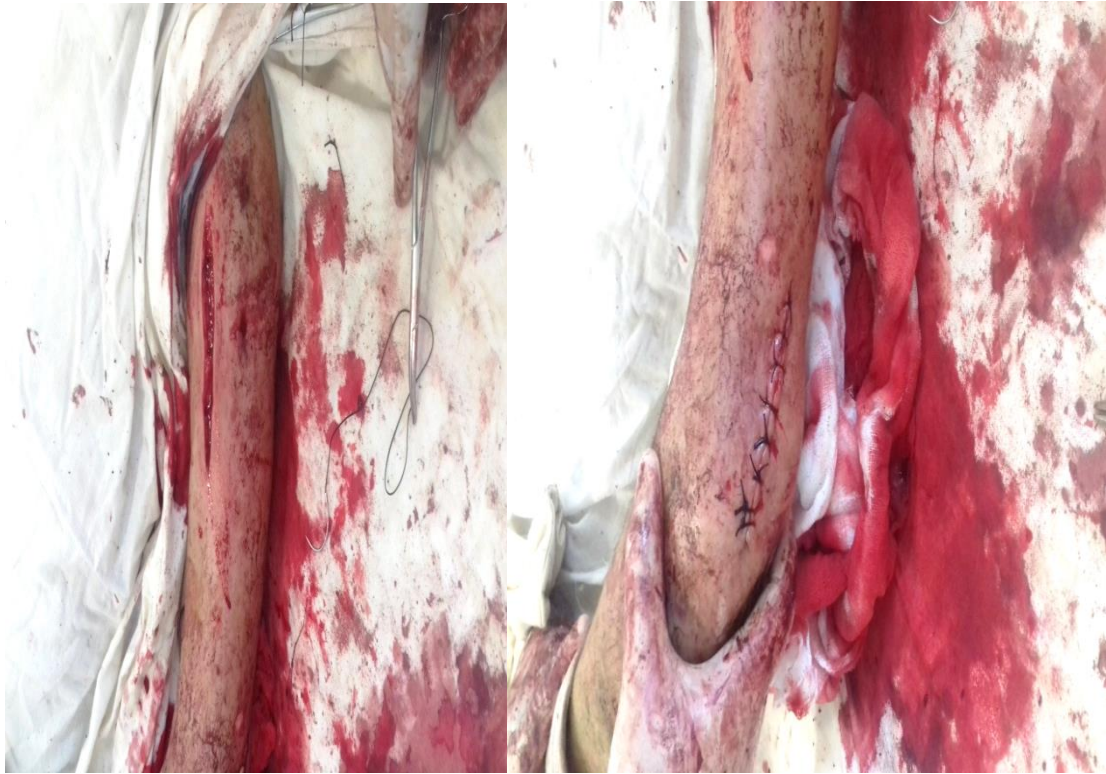

Figure 9A. The second stage of the operation, taking the graft and inserting it into the area of the defect of the humerus. Patient S.K., 1994

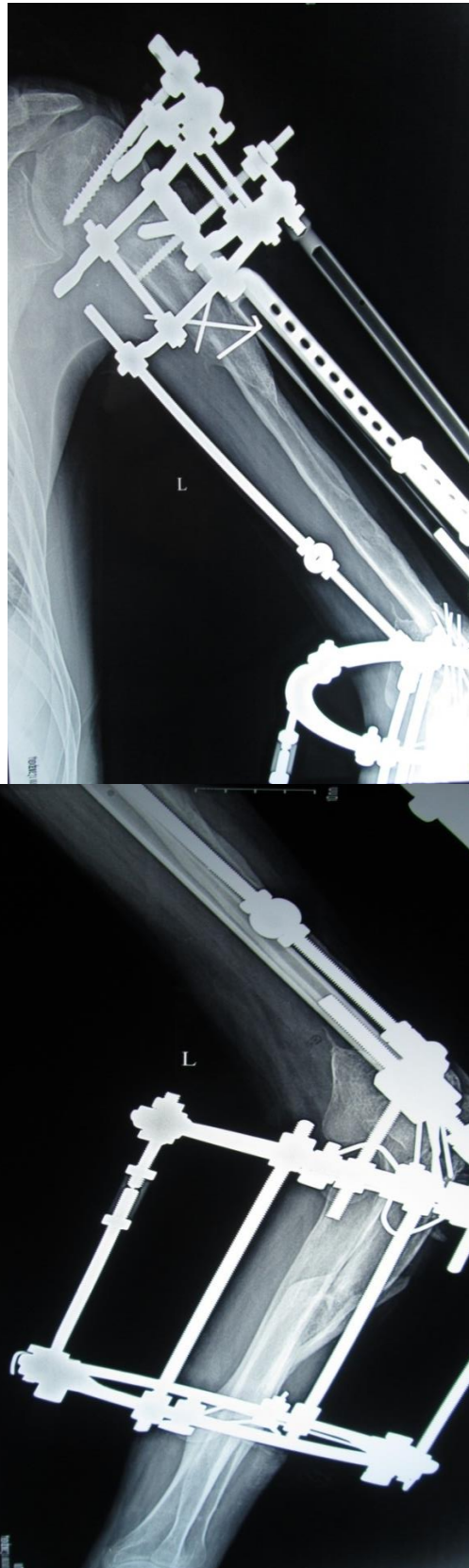

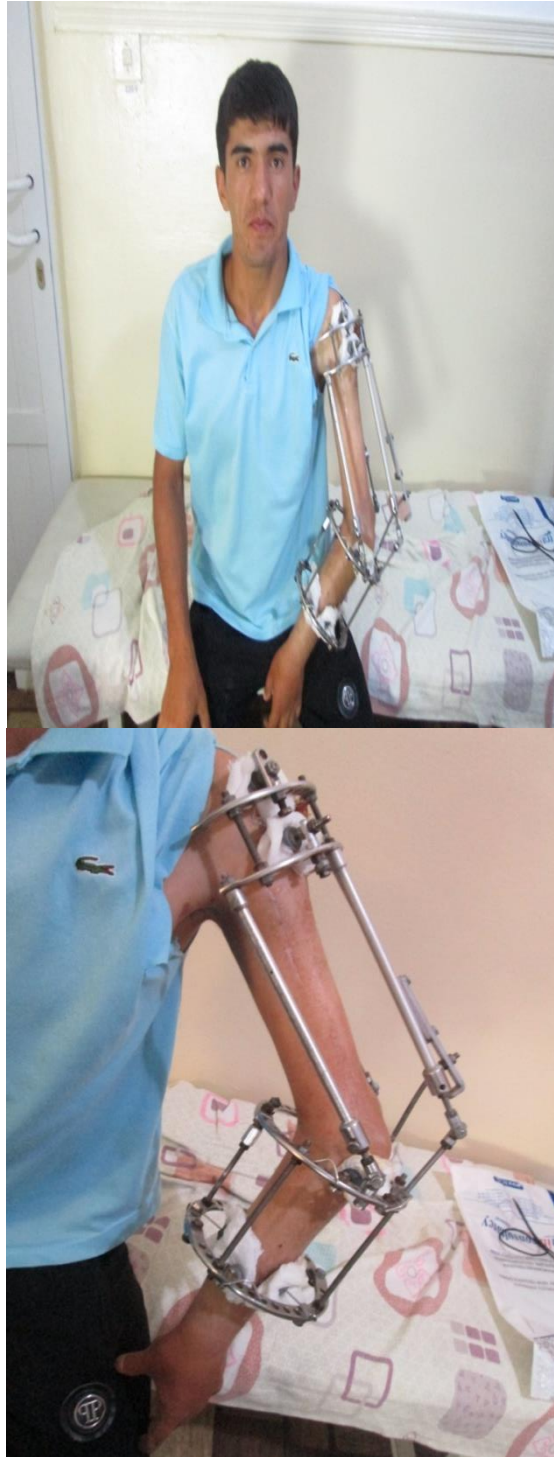


Figure 9B. Appearance and control radiograph of patient S.K., 1994, in dynamics after the second stage of the operation.

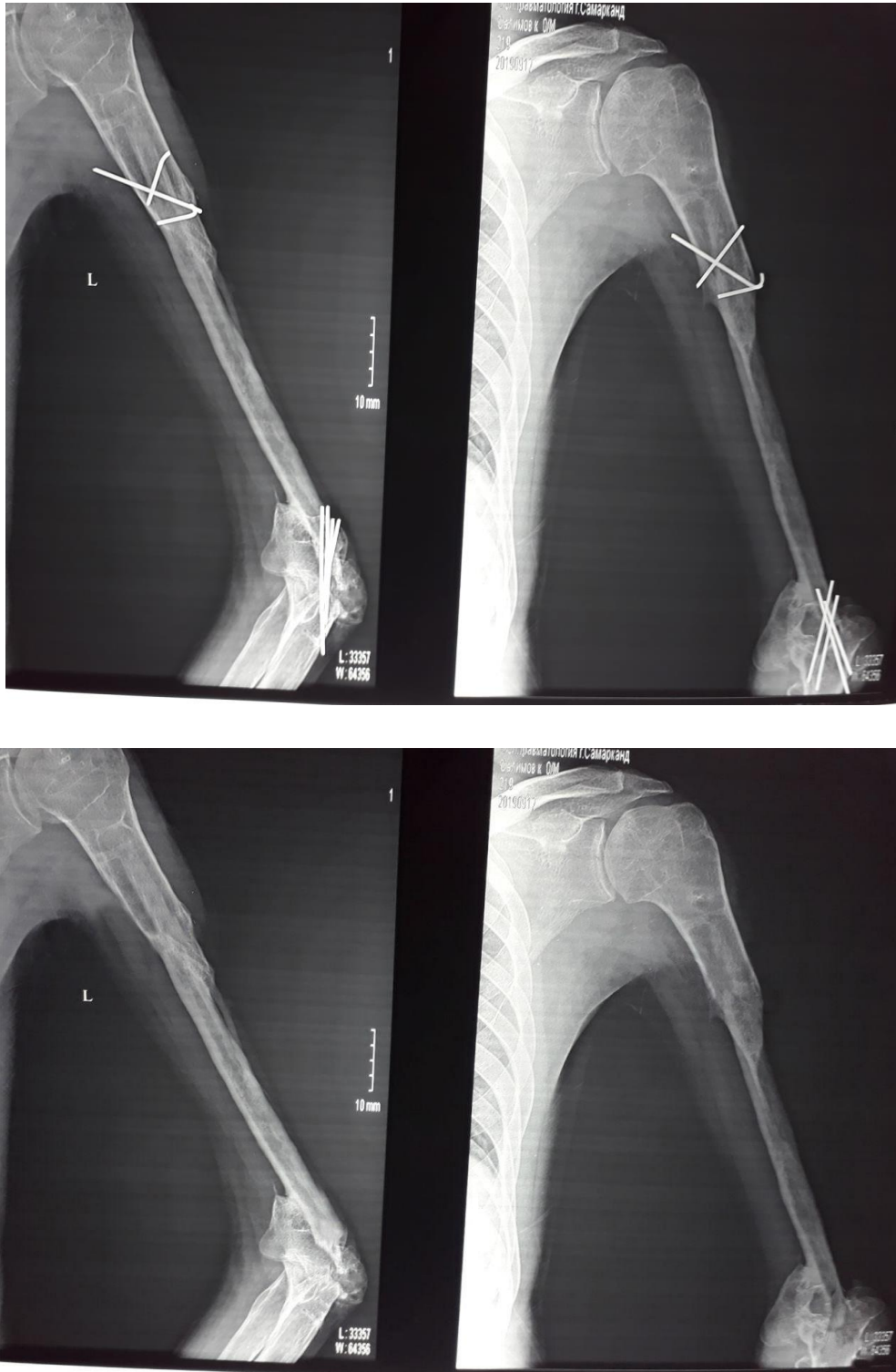


Figure 10A. Radiographs of the patient's left shoulder after treatment. 12.09.2019y.

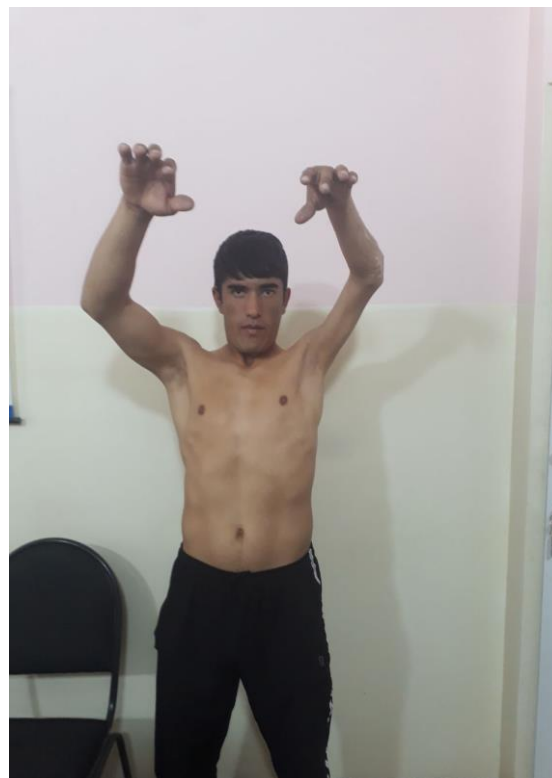
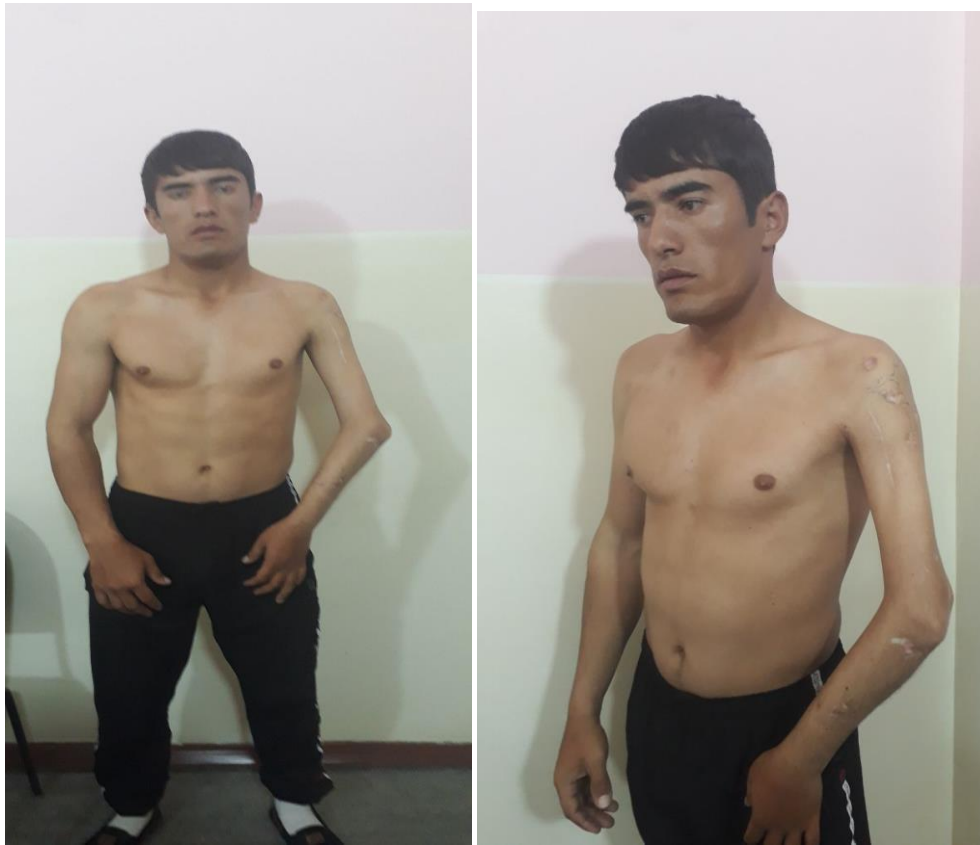
Figure 10B. The appearance of the patient S.K., 1994, after 4 years. 10.012020y.

The second group consisted of 6 patients. One patient had a humerus open fracture with a defect; on the seventh day, an operation was performed without restoring the anatomical limb length, with matching bone fragments. Another 5 patients had an open fracture of the leg bones with a defect. Preoperative preparation was performed using the skeletal traction system. On 10-12 days, an operation was performed to apply an external fixation apparatus without restoring the anatomical length of the segment, since the length of the defect was no more than 3 cm. The result was fusion with anatomical shortening.

3. TREATMENT RESULTS.

Good results were achieved in 12 patients from the main group, which amounted to 75%. These patients returned to their daily work activities. Satisfactory results were achieved in two patients (12.5%), they had fusion of bone fragments, contracture of the elbow and knee joints developed. One patient developed chronic osteomyelitis, the patient is observed. Another patient had an autologous bone fracture at the fusion site. This patient underwent a second operation.

In 4 patients (66.7%) of the control group, fusion with anatomical shortening occurred; these patients were offered limb lengthening. Patients refused lengthening, shortening was compensated by orthopedic shoes, and patients are satisfied with the result of treatment. Two patients (33.3%) developed chronic osteomyelitis, the patients are being observed.

4. DISCUSSION.

We evaluated the treatment results in patients with open fractures of the humerus and forearm bones with an extensive defect in bone tissue using the "Evaluation of elbow surgery" scale. (Richards R.R. et al. 1994). This scale allows you to determine the motion range in the elbow joint, the joint condition, the pain syndrome severity, arm strength and the degree of daily everyday activity. A healthy elbow joint receives the highest score on this scale (100). Our result after 24 months corresponds to a good grade (> 70 points) [24]. In the wrist joint, the function is complete. Patients are satisfied with the treatment (Fig. 6)

We believe that in any case, in fresh open case comminuted fractures with a defect in the bone tissue of long bones, it is desirable to know the exact size of the bone tissue defect in order to apply a specific treatment strategy.

With proper treatment, good results can be achieved in the open fractures treatment of long bones with a bone defect. The most favorable results are observed in a two-stage surgical treatment with restoration of the anatomical limb length. When replacing a defect in the humerus and forearm bones, the displaced fibula engrafts, replaces the lost part of the bone, and is more suitable for the bed in size and properties.

5. CONCLUSIONS:

1. The multistage treatment of patients with long bone fractures using extrafocal perosseous fixation in the acute period of trauma, and with subsequent replacement of the bone defect with an autograft from the fibula in combination with intramedullary fixation with a pin, wires or with repeated application of an external fixation apparatus, allowed to obtain autologous limb with fragments, restoration of the length and limb function.

2. The anatomical segment shape was preserved, and all fixation structures were removed, the limb contains natural biological tissues and does not have foreign bodies (Fig. 10A.10B).
3. In 75% patients, we achieved good results, in 12.5%, satisfactory, in 12.5%, unsatisfactory results.
4. We hope that our scientific article, which reflects our modest experience in treating these category patients, serves to confirm or deny some tactics views in the such patients treatment.

6. REFERENCES

- [1] Khasanov A.G., Nuritdinov M.G., S.S. Nigmatzyanov, R.Sh., Sakaev, R.F., Karamova. Experience of using plasma ducts in the complex treatment of chronic osteomyelitis. *Surgery* 2010.-№10.-p.59-61.
- [2] Klyushin N.M. Ilizarov's method in purulent osteology. *Kurgan*.2019.p-7.
- [3] Keating JF, Simpson AH, Robinson CM. The management of fractures with bone loss. *J Bone Joint Surg Br*.2005;87:142-150.
- [4] Nesbakken. Open tibial fracture with Hoffman external fixation/ *Arch. Orthop. Traumat. Surg.*- 1988.-Vol-107,№ 4.-P/248-252.
- [5] Shevsov V.I. Lower limb bone defects / Shevsov V.I., V.D. Makushin, L.M. Kuftyrov.- *Kurhan: IPP «Trans-Urals »*, 1996.-504p.
- [6] Efgarov A.V. Replacement of defects and pseudoarthrosis of the upper limb bones with vascularized autografts / A.V.Efgarov, A.Yu. Mikhailov // *Herald of traumatology and orthopedics named after N.N. Priorov*.-1998.-№4.-C.29-36.
- [7] Plasty of extensive defects of long bones with vascularized peroneal grafts / I.G. Grishin [et al] // *Priorov Bulletin of Traumatology and Orthopedics*.-2001.-No.2.-P.61-65.
- [8] Shevtsov V.I. The method of perosseous osteosynthesis in the treatment of patients with chronic osteomyelitis / V.I. Shevtsov, A. I. Lapynin, N. M. Klyushin.-*Kurgan: IPP "Trans-Urals"*, 2001.- 221p.
- [9] Complex one-stage treatment of incomplete fractures, false joints and defects of long bones of the extremities complicated by osteomyelitis/Z.I. Urazgeldiev [and others] // *Herald of traumatology and orthopedics named after N.N. Priorov*.-2002.-№4.-p.33-38.
- [10] Berner A, Reichert JC, Muller MB, Zellner J, Pfeifer C, Dienstknecht T, Nerlich M, Sommerwille S, Dickinson IC, Schutz MA, Fuchtmeier B. Treatment of long bone defects and non-unions: from research to clinical practice. *Cell Tissue Res*. 2012 Mar;347(3):501-19. doi: 10.1007/s00441-011-1184-8. Epub 2011 May 17. PMID: 21574059. (Muller. Schutz. Fuchtmeier лардагиустида 2тануктасибор)
- [11] Ashman O, Phillips AM. Treatment of non-unions which bone defects: which option and why? *Injury*.2013 Jan; 44 Suppl 1: S43-5. doi: 10.1016/S0020-1383(13)70010-X. PMID: 23351870.
- [12] Anastasieva E.A., Sadovoy M.A., Voropaeva A.A., Kirilova I.A. The use of auto- and allotransplantation for the bone defects replacement during resection of bone tumors. *Traumatology and Orthopedics of Russia*.2017. V 23,№3.p-148-155.
- [13] Logan M. Lawrence., Andrew Cottrill ., Amrita Valluri., Gaetano Marenzi., Krista L. Denning., Jagan Valluri., Pier Paolo Claudio., James B. Day. *International Journal of Molecular Sciences*. 2019,20(3),612; // <https://doi.org/10.3390/igms20030612>
- [14] Li W, Zhu S, Hu J. Bone regeneration is promoted by orally administered bovine lactoferrin in a rabbit tibial distraction osteogenesis model. *Clin Orthop Relat Res*. 2015; 473: 2383-93.

- [15] Shevtsov V.I., Borzunov D.Yu. Rehabilitation of patients with defects and false joints of long bones, the current state of the problem//Genius of Orthopedics. 2008.No 4.p 48-54.
- [16] Ilizarov G.A., Shved S.I., Martel I.I. Perosseous osteosynthesis of severe open fractures of the leg bones:Methodrecommended /Ministry of Health of the RSFSR; VKNC «WTO». Kurgan,1990.29p
- [17] Gubin A., Borzunov D., Malkova T. Ilizarov method for bone lengthening and defect management. Review of contemporary literature// Bull. Hosp. Jt. Dis. 2016.Vol.74,№ 2. P. 145-154.
- [18] Contribution of G.A. Ilizarov to bone reconstruction: historical achievements and state of the art/ A.V.Gubin, D.Y. Borzunov, L.O.Marchenkova, T.A. Malkova, I.L.Smirnova// Strategies Trauma Limb Reconstr.2016.Vol.11,№3. P. 145-152.DOI: 10.1007/s11751-016-0261-7.
- [19] Battiston B, Santoro D, Lo Baido R, Pasguero F. Treatment of acute bone defects in severe lower limb Trauma. Injury.Voliume 50, Supplement5,December 2019,Pages S40-S45. <https://doi.org/10.1016/j.injury.2019.10.046>
- [20] Sadovoy M.A., Larionov P.M., Samokhin A.G., Rojnova O.M. Cellular matrices (scaffolds) for the purposes of bone regeneration: the current state of the problem // Spine Surgery 2014.No.2.P.79-86.
- [21] Beris AE, Lykissas MG, Korompilias AV, Verkis MD, Mitsionis GI, Malizos KN, Soucacos PN. Vascularized fibula transfer for lower limb reconstruction. Microsurgery.2011 Mar;31(3):205-11.doi: 10.1002/micr.20841. Epub 2011 Feb 25. PMID: 21360586.
- [22] A.P. Barabash, L.A. Kesov, Yu.A. Barabash, S.P. Shpinyak. Replacement of extensive diaphyseal defects in the long bones of the limbs. Traumatology and Orthopedics of Russia. 2014. № 2. page 93.
- [23] Paul H. Kim MD, Seth S. Leopold MD. Gustilo-Anderson Classification. Clin Orthop Relat Res(2012) 470: 3270-3274.
- [24] Merkulov V.N., Dergachev D.A., Dorokhin A.I. Arthroplasty in the treatment of post-traumatic contractures and ankylosis of the elbow joint in children. Pediatric surgery. No. 4.2014. p-34-38.