

Curative Effect of Alpha Lipoic Acid on Parotid Gland Histopathological Changes in Adult Male Rats with Experimentally Induced Hypothyroidism

Marwa Mahmoud Ahmed ⁽¹⁾, Manal M. S. El - Meligy ⁽²⁾, Norhan Nasser Mohamed ⁽²⁾,
Nancy Hussieny Hassan ⁽¹⁾

(1) Human Anatomy & Embryology Department Faculty of Medicine, Zagazig University, Egypt (44519)

(2) Human Anatomy & Embryology Department Faculty of Medicine, Suez University, Egypt
Corresponding Author: Nancy Hussieny Hassan **Email:** nancyhusseiny@gmail.com

ABSTRACT

Background: One of the most frequent chronic disorders is hypothyroidism. It affects various organs including the salivary glands. It causes pathophysiological changes including xerostomia. Alpha lipoic acid (ALA) can provide health benefits through its role as a potent antioxidant, metal chelator and reducing agent of the oxidized forms of other antioxidants such as vitamins C and E. **Aim:** To estimate the influence of hypothyroidism on rat's parotid gland and to illuminate the possible curative role of alpha lipoic acid (ALA). **Methodology:** Thirty-six adult male rats were haphazardly arranged into four groups; nine animals in each as follows: Group 1 (control group): 4 rats were given purified water (vehicle of carbimazole) for three weeks, the other 5 rats were given a daily oral dose of 2ml /kg corn oil only (vehicle of ALA) for four weeks after initiation of hypothyroidism. Group 2 (ALA group): were given a daily oral dose of 60 mg /kg ALA dissolved in its vehicle for 4 weeks. Group 3 (hypothyroid-induced group): were given a daily oral dose of 1.35 mg/kg of carbimazole liquified in its vehicle for 3 weeks to induce hypothyroidism. Group 4 (hypothyroid- ALA group): were given a daily oral dose of 1.35 mg/kg of carbimazole for 3 weeks followed by a daily oral dose of 60 mg /kg ALA treatment for the consecutive 4 weeks. The animals were anaesthetized and slaughtered at the end of the experiment. Parotid glands were collected, and the specimens were prepared for light microscopic examination using Hematoxylin and Eosin and Masson's trichrome stains were used, Morphometric analysis using ANOVA and Tukey's post hoc test was performed. **Results:** Hypothyroidism caused histopathological changes in the form of general cellular distortion, cytoplasmic vacuolations, cellular infiltration, blood vessels congestion and fibrosis and morphometric changes in the form of a significant increase of collagen fibres in hypothyroid group. Alpha lipoic acid succeeded to improve those changes. **Conclusion:** Hypothyroidism has destructive effects on the Parotid gland structure. Fortunately, it is recommended to take Alpha Lipoic Acid in hypothyroid cases to help in decreasing such effects.

Keywords: adult rats, parotid gland, hypothyroidism, alpha lipoic acid.

1. INTRODUCTION

Hypothyroidism is the most prevalent thyroid disorder, which can be caused by a lack of iodine, thyroid gland tumours, autoimmune disorders, or decreased pituitary gland function⁽¹⁾.

Salivary glands swelling is a common presentation in most of hypothyroid patients⁽²⁾. Many researchers have found a link between salivary gland dysfunction and autoimmune thyroiditis⁽³⁾. Moreover, impairment of thyroid function can lead to destructive aberrations in the salivary glands, so people with xerostomia should be evaluated for thyroid functions⁽⁴⁾.

Carbimazole which is a methimazole prodrug can inhibit thyroid peroxidase enzyme coupling and iodinating tyrosine deposits on thyroglobulin, lowering T3 and T4 production. The author also stated that after 2, 4, and 6 weeks of use of carbimazole, serum thyroxine, thyroid-stimulating hormone, and thyrotropin-binding inhibitory immunoglobulins were lowered⁽⁵⁾. Carbimazole was chosen to initiate experimental hypothyroidism⁽⁶⁾.

ALA is a compound of dithiol occurs naturally, which has a protective effect on radiation-induced thyroid gland, salivary gland and intestinal injury⁽⁶⁾⁽⁷⁾. ALA administration also decreases weight, thereby return blood TH levels to normal⁽⁸⁾. ALA is a co-factor for multi-enzyme complexes in mitochondria that increases glucose absorption and changes the action of numerous signaling molecules and transcript factors⁽⁹⁾.

Furthermore, ALA has a lipophilic nature that aids in crossing cell membranes, and it can effectively combat free radicals in both lipid and protein systems when combined with dihydrolipoic acid (DHLA)⁽¹⁰⁾. ALA can improve the body resistance to free radicals⁽¹¹⁾. Other essential antioxidants, such as glutathione and vitamin C, can also be recycled by ALA⁽¹²⁾.

Up to the available literature, determining the specific curative role of ALA for the lethal properties of carbimazole-induced hypothyroidism on salivary glands, particularly the parotid gland did not receive much condensation.

Therefore, this research aims at the evaluation of ALA as a treatment for the adverse effects of hypothyroidism on the parotid gland.

2. MATERIAL AND METHODS

2.1 Chemicals

Carbimazole: SML0931 (Sigma -Aldrich, St Louis Co., MO, USA), 5 mg capsules.

Alpha Lipoic Acid: (Thiotacid or Thioctic acid), 300 mg capsules.

They were purchased from Eva-Pharm Pharmaceutical Company - Egypt.

2.2 Experimental animals

Thirty-six adult male albino Sprague-Dawley rats of 195 gm body weight were bought for the experiment. The rats were purchased from the Animal House at Zagazig University's Faculty of Veterinary Medicine. The animals were kept in a lab setting under supervision. All the trials were carried out in agreement with the strategies of the Institutional Animal Care and the norms of the Ethical Committee of Faculty of Medicine; Zagazig University (ZU-IACUC/3/F/118/2020).

2.3 Experimental Plan

The animals were distributed into four groups (nine animals in each) as follows:

Control Group I: where the rats were further divided into 2 subgroups:

- *Subgroup a:* contained 4 rats were given a daily oral dosage of purified water only (the vehicle of Carbimazole) for three weeks through an intragastric tube.
- *Subgroup b:* contained 5 rats were given a daily oral dosage of 2 ml/kg/day corn oil only (the vehicle of ALA) for four weeks⁽¹³⁾ by intragastric intubation.

ALA group II: contained the rats were given a daily oral dosage of 60mg/kg ALA dissolved in its vehicle for four weeks through intragastric tube.

Hypothyroidism- induced group III: contained rats were given a daily oral dosage of 1.35 mg/kg Carbimazole dissolved in its vehicle for four weeks in order to induce hypothyroidism by intragastric intubation⁽¹⁴⁾.

Fourth (hypothyroid-ALA) group: where the rats were given a daily oral dosage of 1.35mg/kg carbimazole dissolved in purified water for three weeks followed by a daily oral dose of 60 mg/kg ALA liquefied in corn oil for the successive four weeks by using intragastric intubation.

2.4 Methods

I. Experimental Methodology:

At the beginning of the study, all the used rats were weighed and marked. In the trial termination, the animals were weighed again to be compared to their initial weights, then they were anaesthetized with thiopental (120 mg/kg intraperitoneal injection), and finally decapitated. The excised parotid glands were processed for histopathological examination.

II. Light Microscopic Examination:

After fixing the samples in 10% Formalin, paraffin blocks were formed. Sections of 4µm thickness were prepared and stained with Hematoxylin and Eosin (H & E) and Masson's trichrome stains.

III. Morphometric study and Statistical analysis:

Image J Analysis Software (Fiji image j; 1.51 n, NIH, USA) was used at the Human Anatomy and Embryology Department, faculty of medicine, Zagazig University. The Area percentage of collagen fibres (×400) was measured. In all groups, measurements were taken in 10 non-overlapping fields per rat paraffin block. The obtained information was collected, charted, statistically analyzed and represented graphically. The Values were exhibited as mean and standard deviation (SD). Multiple evaluations of the groups were performed using one-way (ANOVA) and Tukey's post hoc Tests. The obvious level was set at $p \leq 0.05$. Statistical analysis was done by statistical analysis system SAS (Cary, NC, USA).

3. RESULTS

3.1. Light Microscopic Examination

3.1.1 Hematoxylin and Eosin Stain (H&E) Results:

As no obvious difference is observed among control and Alpha Lipoic Acid groups, so, both are represented as control groups on the description of histopathological results. Accordingly, they are named: negative and positive groups respectively.

The control groups showed that the parotid gland is formed of lobules; each lobule contained regular densely packed serous acini and striated ducts with a fine network of interlobular connective tissue (Fig. 1a). One layer of high pyramidal epithelial cells around a lumen in each serous acinus, with among thin fibrous connective tissue septa. The striated ducts among the acini were lined with a single layer of low columnar epithelial cells (Fig. 1b).

In contrast, the hypothyroidism-induced group exhibit that acinar cells lose their normal arrangement with pyknosis. The striated ducts and interlobar ducts are dilated. They become lined with more than one layer of epithelial cells (hyperplasia) and surrounded with wide areas of fibrosis (Fig. 1c). Most of acinar cells shows large cytoplasmic vacuolations. Cellular infiltration is observed. There is massive congestion of these blood vessels with periductal congestion. (Fig. 1d).

On the other hand, the parotid gland tissues in the hypothyroidism-ALA group, regain most of the distinctive general acinar configuration, and acinar epithelial cell vacuolations are greatly reduced. The ducts restored their normal epithelial lining. The fibrosis around the ducts and blood vessels is decreased (Fig. 1e, 1f).

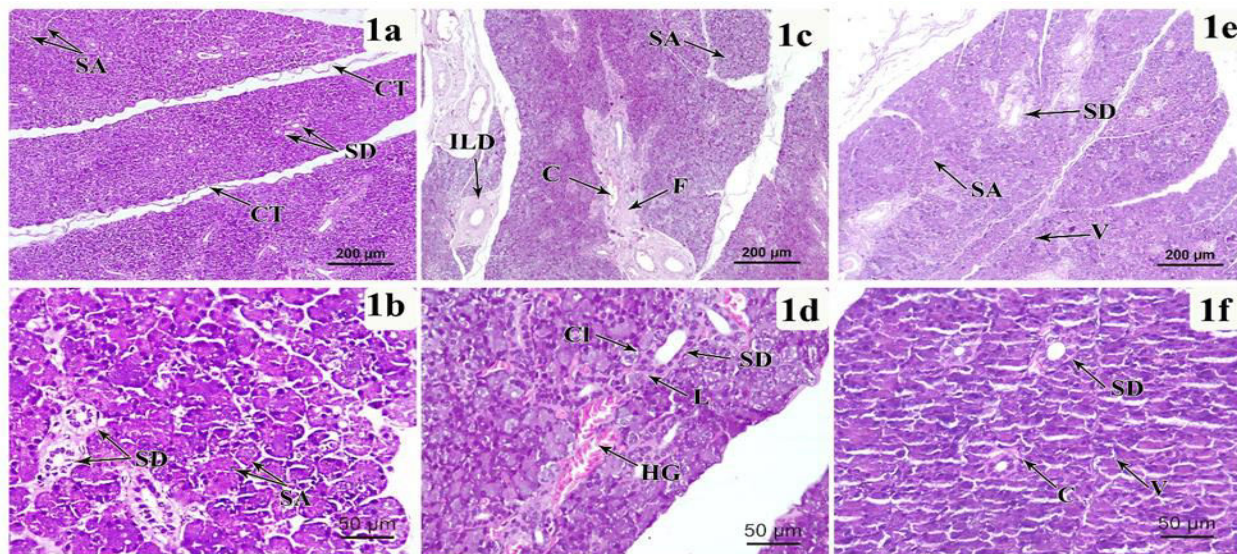


Figure (1): (1a) A Photomicrograph of a section in an adult albino rat parotid gland (control group) shows: the lobules of the gland which formed of serous acini (SA), striated ducts (SD) with a fine network of interlobular connective tissue (CT). (1b) A higher magnification of (1a) shows: normal serous acini (SA). Among the acini, striated ducts (SD) with one layer of columnar epithelium are observed. (1c): A Photomicrograph of a section in an adult albino rat parotid gland (hypothyroidism induced- group) shows: disturbed general distribution of the acini (SA), areas of widespread fibrosis (F), dilated interlobar duct (ILD) and periductal congestion (C). (1d): A magnified Photomicrograph of section in an adult albino rat parotid gland (hypothyroidism induced group) shows: striated ducts are dilated (SD) and lined by more than one layer of epithelial cells (L), cellular infiltration (CI) and hemorrhage (HG). (1e): A Photomicrograph of a section in an adult albino rat parotid gland (hypothyroid _ alpha lipoic acid group) shows: most of the acini look normally (SA), only limited acini show vacuoles in the cytoplasm (V) and most of the

striated ducts show normal character (SD). (1f): A magnified Photomicrograph of a section in an adult albino rat parotid gland (hypothyroidism -induced & alpha lipoic acid group) shows: few epithelial cytoplasmic vacuolations (V), a little periductal congestion (C) and the striated ducts appear normal shape (SD).

(H and E x 100, Scale bar 200 μ m 1a, 1c & 1e)- (x 400, Scale bar 50 μ m 1b, 1d & 1f).

3.1.2 Masson's Trichrome Stain Results:

The Control groups reveals few basophilic collagen fibres surrounding the ducts (Fig. 2a). In contrast, in hypothyroidism - induced group, abundant collagen fibres surrounding the ducts, acini and the blood vessels are observed (Fig. 2b). However, hypothyroid-ALA group exhibits few collagen fibers around the ducts and blood vessels (Fig. 2c).

Statistical analysis:

Based on Masson's Trichrome results, these findings are proved by the statistical analysis of area percentage of collagen fibres in all experiment groups (Figure 3 & Table. 1). A significant increase is observed in hypothyroidism- induced group in comparison with the control negative and control positive groups. Furthermore, there is a significant decrease in hypothyroidism- induced + ALA group in comparison with hypothyroidism- induced group. No significant differences are found comparing the hypothyroid induced + ALA with the control negative and positive groups.

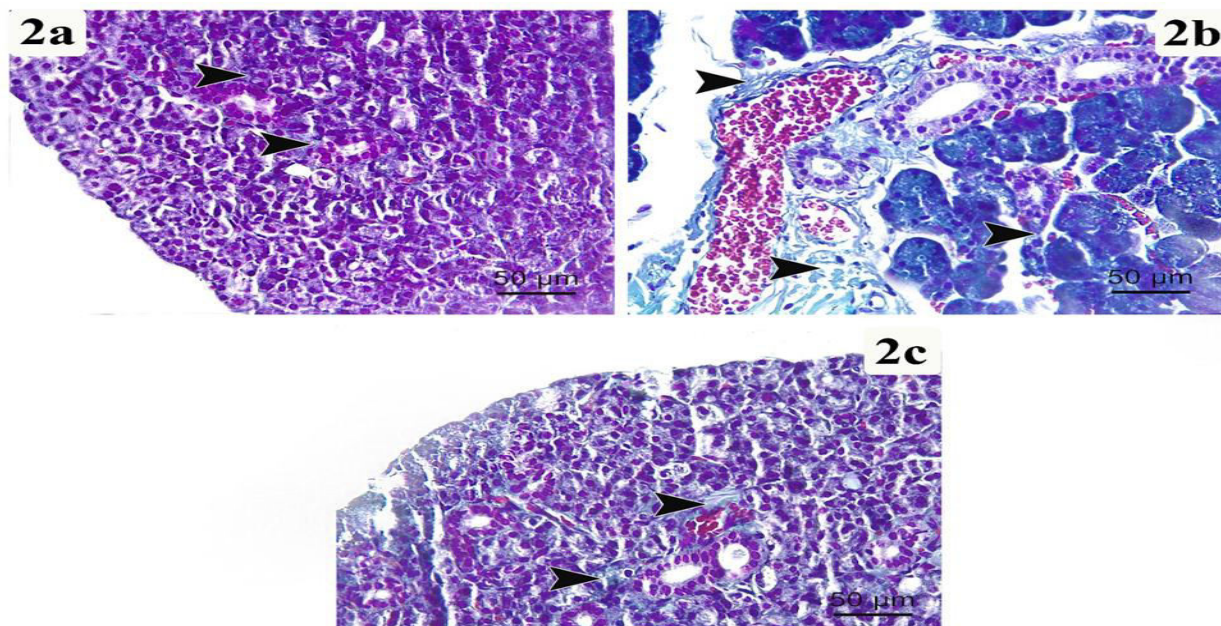


Figure 2: Photomicrographs of Masson's Trichrome stained sections of different experimental groups presenting the collagen fibres distribution. (2a) Control group, (2b) Hypothyroidism-induced group (2c) Hypothyroidism-induced + ALA groups. Arrow heads indicate the blue staining of the collagen fibres in the interstitium and around the blood vessels.

(Masson's Trichrome, scale bar x 50 μ m, x400).

Table 1: Area percent of collagen fibers of Masson Trichrome stain for all experimental groups:

Parameter	control negative	control positive	Hypothyroidism induced	Hypothyroidism induced + Alpha Lipoic Acid	P-value
Area percent of collagen fibers	16.830±4.376	17.989±4.987	37.153±5.136 ^{ab}	15.679±4.258 ^c	0.0001

a-c Means with different superscripts in the same row are significantly different (* p<0.05, Tukey HSD test).

^ap<0.05 in comparison with control negative;

^bp<0.05 in comparison with control positive;

^cp<0.05 in comparison with Hypothyroidism induced groups

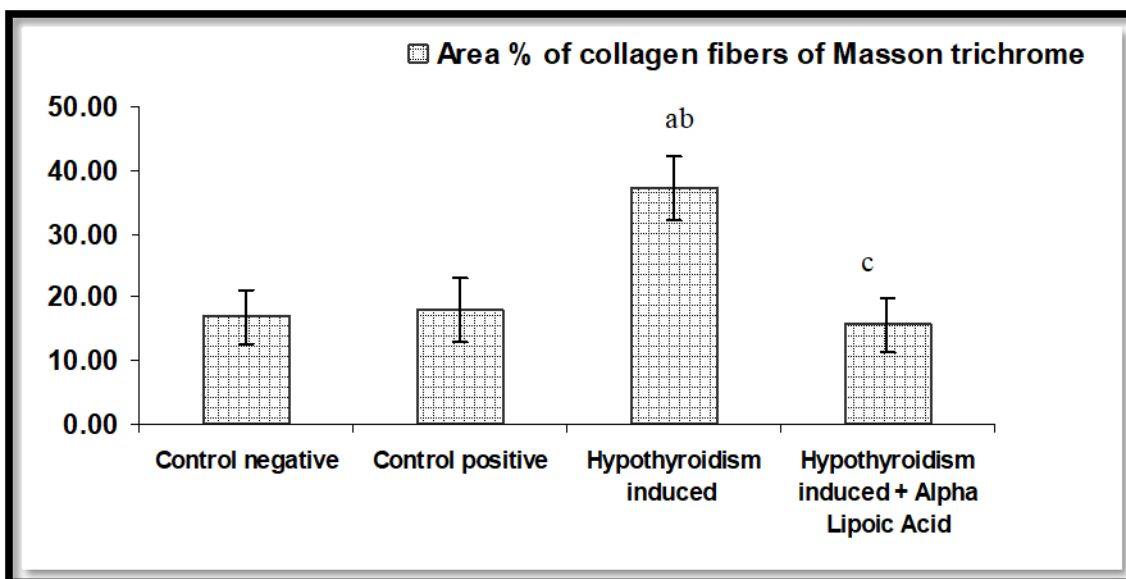


Figure 3: A bar chart demonstrating the analysis of the area % of collagen fibres of all groups.

^ap<0.05 in comparison with control negative

^bp<0.05 in comparison with control positive

^cp<0.05 in comparison with Hypothyroidism induced groups

4. Discussion

The goal of this research is to evaluate the curative ability of ALA supplement on the destructive changes produced by carbimazole-induced hypothyroidism on parotid gland tissue of the experimental animal model.

Salivary glands are essential for maintaining a good oral sanitation and preserving the quantity and quality of saliva ⁽¹⁵⁾. Thyroid hormones are essential to maintain the function and histology of salivary glands ⁽¹⁶⁾.

Hypothyroidism can cause xerostomia; early diagnosis of xerostomia is critical for keeping and helping systemic and oral health⁽¹⁷⁾.

Regarding the light microscopic examination of the control groups, the study verified that the parotid gland was formed of lobules; each lobule contained densely packed serous acini and striated ducts with a fine network of interlobular connective tissue. Each serous acinus was found to be lined by one layer of high pyramidal epithelial cells surrounding a central lumen with thin fibrous connective tissue septa among the acini. Furthermore, the striated ducts between the acini were lined with a single layer of low columnar epithelial cells.

The results come in accordance with the previous researches, it was stated that the parotid gland was composed of lobules, each lobule was formed of regular serous acini, striated ducts and a fine network of interlobular Connective tissue. The authors observed that those acini had a narrow lumen surrounded by a one layer of pyramidal cells with basal round nuclei. In addition, a single layer of columnar epithelium lined the striated ducts⁽¹⁸⁾ ⁽¹⁹⁾. Also, a previous study documented that the Histological Examination of sections of salivary gland of control rats revealed normal structure of its elements; acini were spherical, deeply stained and coalesced to each other. The acinar cells appeared pyramidal in shape with basophilic homogenous cytoplasm and clear cellular boundaries⁽²⁰⁾.

The results of the study did not show any difference in the histological pictures of the parotid glands between positive and negative control groups. This was in agreement Nasr El-Din and Abdel Fattah who proved that there wasn't statistical change between control and Nigella Sativa oil (NSO) groups in all evaluated statistical parameters⁽¹⁹⁾.

As regards the light microscopic examination of hypothyroidism-induced group, the study revealed that the acinar cells lost their normal arrangement and showed pyknosis. Most of the acinar cells showed large cytoplasmic vacuolations and cellular infiltration. The results revealed that the striated ducts and interlobar ducts were dilated, became lined with more than one layer of epithelial cells (hyperplasia) and surrounded with wide areas of fibrosis. The study also found that the blood vessels were massively congested. Periductal congestion is observed. They were surrounded by massive fibrosis.

In agreement with this study it was documented that some acinar cells were opaque while other; were cloudy. They had deeply stained nuclei and highly vacuolated cytoplasm, with ductal hyperplasia, cellular infiltration and congested blood vessels⁽²¹⁾.

The same result was obtained by other authors; the acini in hypothyroidism-induced rats showed indistinct outlines with an increase in the amount of inter acinar & interlobular connective tissue⁽²⁾. It was noticed that giving exogenous T3 to the developing rats cause separation of regular acini in salivary glands⁽²²⁾.

Consistent with those findings, it was noted that the administration of propylthiouracil and methimazole led to reduction in the number and size of the acini of the salivary glands⁽²³⁾ ⁽²⁴⁾ ⁽²⁵⁾.

In addition, a previous study stated that pancreatic tissue of hypothyroid rats showed shrunken acini and cytoplasmic vacuolation⁽²⁶⁾. It was noticed that the nuclei of the hypothyroidism-induced group in both parotid and submandibular glands appeared pyknotic, degenerated and

some show pleomorphism, the cytoplasm was darkly stained⁽²⁴⁾⁽²⁰⁾. It was found that the atrophy in serous acinar structure increased with the increase in the duration of hypothyroidism ($p < 0.05$)⁽²⁷⁾.

These degenerative changes observed in the hypothyroid group may be due to the free radicals resulting from hypothyroidism, which have a damaging effect⁽²³⁾. The study came in agreement with another study which stated that the degenerative alterations could be linked to elevated blood endotoxins and oxidative stress, which resulted in capillary damage, exudation, and apoptosis⁽²⁸⁾. Another work found that those changes might be a result of an inflammatory response, which might restrict the diffusion of nutrients and oxygen to parotid cells⁽²¹⁾. Some investigation found that hypothyroidism caused an increase in the formation of plasma Malondialdehyde (MDA) (a product of lipid peroxidation) and a reduction in the activity of plasma superoxide dismutase (SOD) (an antioxidant enzyme) this led to the development of oxidative stress in hypothyroidism resulting in cell destruction⁽²⁹⁾⁽³⁰⁾.

Regarding the light microscopic examination of hypothyroidism-induced + ALA group, this work showed that parotid tissue regained the normal shape most of the acini and the vacuoles in the cytoplasm were obviously decreased. In addition, the ducts restored their normal epithelial lining with decreased fibrosis around the ducts and blood vessels.

In line with the study results, it was reported that ALA had a therapeutic effect in hypothyroidism-induced toxicity⁽³¹⁾. It was noticed that ALA caused an enhancement in tubular diameter and germinal epithelial thickness in the testis of hypothyroid rats⁽²⁸⁾. It was conveyed that ALA acted as a strong antioxidant, which could reduce the histological alterations induced by Carbimazole in the tissue of adult male rats' testis⁽³²⁾. It was discovered that taking ALA reduced obesity, restoring blood TH levels and lowering oxidative stress⁽⁸⁾. In addition, it was reported that ALA improved human micro vascular endothelial cells dysfunction induced by oxidative stress⁽³³⁾. Another study found that postweaning administration of ALA might be useful in alleviating the developmental hypothyroidism-induced disrupted neurogenesis in Propylthiouracil (PTU)-exposed offspring⁽³⁴⁾.

These encouraging findings could be attributable to the lipophilic nature of the ALA molecule, which easily crosses biological membranes and so reaches all cellular compartments, improving oxidative stress-related diseases such as atherosclerosis, metabolic syndrome, and diabetes mellitus⁽⁸⁾. In addition, ALA has an anti-inflammatory effect, which counteracts the inflammatory signs like cellular infiltration and fibrosis⁽³⁵⁾.

Regarding the area percentage of collagen fibres, the results of this study documented that there was an obvious increase in hypothyroidism-induced group related to the control negative and control positive groups. Furthermore, there was a significant decrease in hypothyroidism-induced + ALA group in comparison with Hypothyroidism-induced group without any statistical change between control negative and control positive groups.

These findings were in line with previous researches which confirmed that Carbimazole-induced hypothyroidism had harmful properties on the parotid tissue of the animal model which included loss of normal acinar distribution, inter-acinar spaces became wide, cytoplasmic vacuoles, congested

blood vessels, dilated ducts, and excess deposition of collagenous fibres around the blood vessels and inter-lobular ducts^(3,4&24)

5. Conclusion

The study clarify a great role of ALA as a therapeutic curative agent to the toxic parotid gland histopathological effects that occurred due to carbimazole-induced hypothyroidism in rats.

Acknowledgements

The authors wish to express their gratitude to staff members of Human Anatomy and Embryology Department, faculty of medicine, Zagazig university, for the generous collaboration.

Conflict of Interest: Non declared.

Funding: No funding sources

REFERENCES:

1. Ott J, Promberger R, Kober F, Neuhold N, Tea M, Huber JC, et al. Hashimoto's thyroiditis affects symptom load and quality of life unrelated to hypothyroidism: a prospective case-control study in women undergoing thyroidectomy for benign goiter. *Thyroid*. 2011; 21(2):161-7.
2. Hayat NQ, Tahir M, Munir B, et al. effect of methimazole-induced hypothyroidism on histological characteristics of parotid gland of albino rat. *J Ayub Med. Coll. Abbottabad*. 2010; 22(3):22-27.
3. AbdElazeem A, Mohammed MZ, Hassan EZ. Effect of Experimentally Induced Hypothyroidism on the Parotid Gland of Adult Male Albino Rats and the possible Role of Thyroid Hormone Supplementation. *British Journal of Science*. 2016; 14 (1): 19-36.
4. Hayat NQ, Nadir S, Farooq MU. Histological characteristics of submandibular gland after induction of hypothyroidism in adult albino rat. *J.R.M.C*. 2016; 20 (1), 41-47.
5. Hossain AO. Carbimazole and its effects on thyroid gland of female rabbits. *Indian Journal of Forensic Medicine & Toxicology*, 2019; 13(3), 305-311.
6. Jeong BK, Song JH, Jeong H, Choi HS, Jung JH, Hahm JR, et al. Effect of alpha-lipoic acid on radiation-induced small intestine injury in mice. *Oncotarget*. 2016; 7, 15105-15117.
7. Kim JH, Kim KM, Jung MH, Jung JH, Kang KM, Jeong BK, et al. Protective effects of alpha lipoic acid on radiation-induced salivary gland injury in rats. *Oncotarget*. 2016; 7, 29143-29153.
8. Cheserek MJ, Wu G, Li L, Karangwa E, Shi Y. Cardioprotective effects of lipoic acid, quercetin and resveratrol on oxidative stress related to thyroid hormone alterations in long-term obesity. *J Nutr Biochem*. 2016; 33 :36-44.

9. Tutelyan VA, Makhova AA, Pogozheva AV, et al. [Lipoic acid: physiological role and prospects for clinical application]. *VoprPitan.* 2019; 88(4): 6–11, doi: 10.24411/0042-8833-2019-10035, indexed in Pubmed: 31722135.
10. Holmquist L, Stuchbury G, Berbaum K, et al. Lipoic acid as a novel treatment for Alzheimer's disease and related dementias. *PharmacolTher.* 2007; 113(1): 154–164, doi: 10.1016/j.pharmthera.2006.07.001, indexed in Pubmed: 16989905
11. Xiang W, Wang Li, Cheng S, et al. Protective effects of α -lipoic acid on vascular oxidative stress in rats with hyperuricemia. *Curr Med Sci.* 2019; 39(6): 920–928, doi: 10.1007/s11596-019-2124-1, indexed in Pubmed: 31845223.
12. Karafakioğlu YS. Effects of α lipoic acid on noise induced oxidative stress in rats. *Saudi J Biol Sci.* 2019; 26(5): 989–994, doi: 10.1016/j.sjbs.2018.08.008, indexed in Pubmed: 31303830
13. Al-Trad B, Al-Batayneh K, El-Metwally S, Alhazimi A, Ginawi I, Alaraj M, et al. *Nigella sativa* oil and thymoquinone ameliorate albuminuria and renal extracellular matrix accumulation in the experimental diabetic rats. *Eur. Rev. Med. Pharmacol. Sci.* 2016; 20 (12), 2680–2688.
14. Sakr SA, Mahran HA, Nofal AE. Effect of Selenium on Carbimazole-Induced Histopathological and Histochemical Alterations in Prostate of Albino Rats. *A.J.M.M.S.* 2012; 2 (1), 5–11.
15. Maeshima E, Furukawa K, Maeshima S, Koshiba H, Sakamoto W. Hyposalivation in autoimmune diseases. *Rheumatol. Int.* 2013; 33, 3079–3082.
16. Hayat NQ. Effect of Hypothyroidism on the Histology of Sublingual Salivary Gland in Adult Albino Rats. *JRMC.* 2017; 21: 395-9.
17. Saleh J, Figueiredo MAZ, Cherubini K, Salum FG. Salivary hypofunction: An update on aetiology, diagnosis and therapeutics. *Arch Oral Biol.* 2015; 60(2):242-55.
18. Hashem HA, El-Metwaly H, Mobarak YM, et al. Impact of Induced Thyroxine and Carbimazole Vacillation on Liver of Female Rats. *Egypt. Acad. J. Biolog. Sci.* 2016; 8(2): 15-29.
19. Nasr El-Din WA, Abdel Fattah IO. Histopathological and biochemical alterations of the parotid gland induced by experimental hypothyroidism in adult male rats and the possible therapeutic effect of *Nigella sativa* oil. *Tissue and Cell.* 2020; Aug 1; 65: 101366.
20. El Dahrawy D, Adawy H, Eldeeb M. Effect of Bone Marrow Derived-Mesenchymal Stem Cells on Submandibular Salivary Glands of Carbimazole Induced Hypothyroidism in Albino Rats. *Al-Azhar Dental Journal for Girls*, 2021; pp.277-284.
21. Hashem H, Saad S. Comparative study of the effect of experimentally induced hyperthyroidism and hypothyroidism on the parotid gland in adult male albino rats. *Egyptian Journal of Histology*, 2020; 43(3), pp.791-807.
22. Bano S, Ghafoor S, Naseem N. Effect of thyroid hormone on the histology of rat submandibular salivary gland during postnatal development. *J Pak. Dent. Assoc.* 2018; 27(1):37-42.

23. De Jesus VC, Beanes G, Paraguassú GM, Ramalho LM, Pinheiro AL, Ramalho MJ, et al. Influence of laser photobiomodulation (GaAlAs) on salivary flow rate and histomorphometry of the submandibular glands of hypothyroid rats. *Laser Med Sci.* 2015; 30: 1275-80.
24. Ayuob N. Histological and immunohistochemical study on the possible ameliorating effects of thymoquinone on the salivary glands of rats with experimentally induced hypothyroidism. *EJH.* 2016; 39: 125-35.
25. Elazeem A, Mohammed MZ, Hassan EZ. Effect of experimentally induced hypothyroidism on the parotid gland of adult male albino rats and the possible role of thyroid hormone supplementation. *Br J Sci.* 2016; 1: 14.
26. Arafa MA, Gouda ZA, El-naseery NI, Abdel-Nour HM, Hanafy SM, Mohamed AF, et al. Bone Marrow-Derived Mesenchymal Stem Cells Ameliorate the Pancreatic Changes of Chemically Induced Hypothyroidism by Carbimazole in Male Rats. *Cells Tissues Organs.* 2018; 206: 144-56.
27. Uzun S, Tatlıpınar A, Kınal E, Keskin S, Özbeyli D, Güneş P. Histopathological changes of parotid and larynx in hypothyroid rats: experimental study. *European Archives of Oto-Rhino-Laryngology,* 2021; pp.1-9.
28. Ibrahim AA, Mohammed NA, Eid KA, Abomughaid MM, Abdelazim AM, Aboregela AM. Hypothyroidism: morphological and metabolic changes in the testis of adult albino rat and the amelioration by alpha lipoic acid. *Folia Morphologica* 2021.
29. Ayuob NN, Abdel-Hamid AA, Helal GM, Mubarak WA. Thymoquinone reverses nonalcoholic fatty liver disease (NAFLD) associated with experimental hypothyroidism. *Rom J MorpholEmbryol.* 2019; 60: 479-86.
30. Di Domenico M, Pinto F, Quagliuolo L, Contaldo M, Settembre G, Romano A, et al. The role of oxidative stress and hormones in obesity. *Front Endocrinol.* 2019; 10: 540.
31. Gawish AM. The protective role of alpha lipoic acid against pesticides induced testicular toxicity- histopathological and histochemical studies. *J Aquaculture Res Development.* 2010; 1(1): 101, doi: 10.4172/2155-9546.1000101.
32. Prathima P, Venkaiah K, Pavani R, et al. α -lipoic acid inhibits oxidative stress in testis and attenuates testicular toxicity in rats exposed to carbimazole during embryonic period. *Toxicol Rep.* 2017; 4: 373–381, doi: 10.1016/j.toxrep.2017.06.009, indexed in Pubmed: 28959662.
33. Pang L, Deng P, Liang Y-D, Qia J-Y, Wu L-C, Yang Zhou Z. Lipoic acid antagonizes paraquat-induced vascular endothelial dysfunction by suppressing mitochondrial reactive oxidative stress. *Toxicology Research,* 2019; 8(6), 918–927.
34. Tanaka T, Masubuchi Y, Okada R, Nakajima K, Nakamura K, Masuda S, et al. Ameliorating effect of postweaning exposure to antioxidant on disruption of hippocampal neurogenesis induced by developmental hypothyroidism in rats. *J Toxicol Sci.* 2019; 44(5): 357-372. Lipoic Acid Oxidative Stress Hypothyroidism.

35. Saleh HM, El-Sayed YS, Naser SM, Eltahawy AS, Onoda A, Umezawa M. Efficacy of α -lipoic acid against cadmium toxicity on metal ion and oxidative imbalance, and expression of metallothionein and antioxidant genes in rabbit brain. *Environmental Science and Pollution Research*, 2017; 24(31), 24593-24601.