

Three Case Reports of Ameloblastoma with relevant clinico-radiographic and histopathologic correlations.

Running title:

Ameloblastoma With Relevant Clinico-Radiographic And Histopathologic Correlations.

Dr. Mohamed Abdulcader Riyaz SS

¹*Assistant Professor in Oral Medicine and Radiology, Department of Maxillofacial Surgery and diagnostic Sciences, College of Dentistry in Ar Rass Qassim University, Kingdom of Saudi, Arabia*

E-mail: m.salahudeen@qu.sa

Abstract: Ameloblastoma is one of the most common clinically significant tumor. It belongs to 1% of all oral tumors. Compared to maxilla, the mandible is quite commonly affected (4:1). It affects both male and female population equally. The age at presentation is usually between 3rd and 7th decade of life. The usual clinical presentation is that of a slow growing asymptomatic intraoral swelling. There are four clinico-radiographic types of Ameloblastoma namely Unicystic, Multicystic, Peripheral (extra-osseous) and Desmoplastic. The Histologic types include Follicular, Plexiform, Acanthomatous, Granular, Basal cell & Desmoplastic. The unicystic type has three histologic variants namely luminal, intra-luminal and mural. This article is aimed at documenting three case reports of Ameloblastoma with histopathologic variations and correlating them with clinico-radiographic findings.

Key words: Ameloblastoma, clinical, radiographic, correlations, histopathologic

1. INTRODUCTION

In 1937, Robinson defined Ameloblastoma, as a benign tumor that is “usually unicentric, intermittent in growth, nonfunctional, anatomically benign and clinically persistent.” The World Health Organization (WHO) in 1991 defined Ameloblastoma as a benign but locally aggressive tumor with a high affinity for recurrence, involving of proliferating odontogenic epithelium lying in a fibrous stroma[1]. It is a slow growing tumor and clinically asymptomatic. The clinical symptoms begin to surface only after the tumor attains a considerably bigger size. It is also diagnosed during routine radiographic examination which is further confirmed by histopathological examination. This locally aggressive and benign tumor is further classified clinico-radiographically into four types and histologically into six types. The most commonly involved site is the ramus-condyle region of the mandible [2]. En-

block resection of the involved bone with sufficient clearance is the commonly followed surgical procedure for treating Ameloblastomas[3]. Here we have discussed 3 case reports of ameloblastoma with clinic-radiographic findings.

Case 1:

A 40 year old male patient reported to the department of Oral Medicine and Radiology with a diffuse extraoral swelling involving the left parasymphiseal region, body and ramus of the mandible. Intraorally, the swelling seemed to be evident after the first molar (Fig-1a, 1b). The swelling was hard in consistency with some areas firm in consistency. Egg shell crackling was evident while palpating the buccal cortical plate. Multilocular, soap-bubble appearances involving left parasymphysis, body, ramus and condyle region were evident in the panoramic and lateral oblique radiographic views (Fig- 2a, 2b). Root resorption was evident in the first molar. Enblock resection was carried out and the postoperative period was uneventful. The Histopathological findings suggested that it was a Plexiform type of Ameloblastoma (Fig 3, 4a, 4b).

Case 2:

A 60-year-old female came to the department of Oral Medicine and Radiology with a large diffuse extraoral swelling involving the right side parasymphysis, body of the mandible (Fig-1a,1b). Intraorally, the swelling extended from 43 till 47 with evidence of bicortical expansion (Fig-2). The lesion was hard in consistency in the right side mandibular anterior region and soft to firm in consistency in other areas. Honey comb appearance was evident in the conventional radiographs and also in the axial computed tomographic views of the right side anterior mandibular region (Fig 3.a, b). The axial CT views also revealed scalloping and the lesion seemed to be cross the midline (Fig 4,a,b,c). Because of the varying consistency, calcifying epithelial odontogenic cyst was included in the differential diagnosis. The histopathological findings suggested that it was a combination of follicular/plexiform/acanthomatous type of Ameloblastoma (Fig 5. a,b). Enblock resection was performed and the postoperative period was uneventful.

Case 3:

A 34 year old female came to the department of Oral Medicine and Radiology with a huge diffuse extra oral swelling involving the right side of the mandible. The lesion seemed to extend from right side body of the mandible, ramus till sub condylar region (Fig 1.a,b). The radiographs and CT views also revealed root resorption of 46 & 47 and soap bubble appearance (Fig 2a,2b, 3a, 3b). The consistency of the swelling was soft to firm in all areas owing to the extensive bone destruction and soft tissue proliferation. The histopathological findings were suggestive of Granular Ameloblastoma (Fig 4a, 4b). Enblock excision with normal margins was performed and the post-operative period was uneventful (Fig 5a, 5b).

Table-1 gives clinico histological findings of all 3 cases.

2. DISCUSSION

In 1934, Churchill first coined the term Ameloblastoma. It is derived from a) epithelial cell rests of serres and malassez b) epithelium of odontogenic cysts c) disturbances of the developing enamel d) basal cells of the surface epithelium e) heterotopic epithelium in other parts of the body, especially the pituitary gland. The presenting complaint of a patient

with Ameloblastoma could be pain, numbness, Teeth that are tender on percussion, mobile teeth, ill-fitting dentures, malocclusion, ulceration, draining sinuses, nasal obstruction and epistaxis. Trauma, infection or previous extraction was documented in 60% to 70% of the cases. The follicular type of Ameloblastoma is the common histopathological variant according to the literature followed by plexiform, desmoplastic and acanthomatous types. Ameloblastoma seems to be the most prevalent tumor in West Africa whereas Odontomas are more prevalent and common than Ameloblastoma in Latin America[4,5].

The follicular type is frequently associated with paresthesias than the plexiform type. Larger and recurrent Ameloblastomas are associated with mixed histopathological patterns and root resorption. There is an association of chronic irritation with squamous metaplasia seen in Acanthomatous Ameloblastoma variety. The follicular and plexiform Ameloblastomas occur in patients with wide age range (11-70 Years). The acanthomatous variant occurred mostly in the 6th and 7th decades. The basal cell, desmoplastic and unicystic variant were reported to be more prevalent in the fourth decade. The Granular type of Ameloblastoma occurs in a younger age group and it grows much faster and is clinically more aggressive[6,7].

The clinicoradiographic types of Ameloblastoma are Solid/Multicystic, Unicystic, Peripheral or Extra osseous and Desmoplastic variant. The Solid/Multicystic variant is the most common clinicoradiographic type (86%) and it manifests radiographically either as honeycomb (smaller locules) or as soap bubble appearance (larger locules). The Unicystic variety is the least aggressive and it is mostly pericoronal in location and rarely periapical in location. The Peripheral or extraosseous type is the soft tissue variant of Ameloblastoma and is not frequently encountered in day-to-day clinical practice. Most Soft tissue Ameloblastomas are reported as Plexiform variants histopathologically [8-10]. The Desmoplastic variant is also recognized as a distinct clinicoradiographic entity because of its resemblance with fibro-osseous lesions radiographically and the need to provide sufficient clearance during surgery[11].

Surgical management of Ameloblastoma depends on the clinic-radiographic type, location of the tumor, age and size of the tumor. A clearance of 1.5 to 2cm during surgery reduces the chances of recurrence. Incompletely removed tumor, conservative approach almost always leads to recurrence or malignant transformation in some cases. Metastasis is rare but possible to distant sites like pleura, lungs, lymph nodes and bone. Enbloc excision is carried out in most of the cases and in some types with extensive destruction and infiltration partial maxillectomy or hemimandibulectomy is carried out. Long term follow-up is required for this tumor as some cases have recurred 25 years after the first occurrence [12].

3. CONCLUSION

Ameloblastomas may cause difficulties during diagnosis especially if they mimic common clinical situations. During radiographic evaluation of periapical lesions, care must be taken to identify scalloped margins and root resorption. While performing surgery, care should be taken to send all the tissues for histopathological examination. This simple measure would avoid more unusual conditions being missed and enable appropriate treatment to be instigated early.

4. REFERENCES

- [1] Krishnapillai R, Angadi PV. A clinical, radiographic, and histologic review of 73 cases of ameloblastoma in an Indian population. *Quintessence Int.* 2010;41:e90–100.
- [2] Ooi A, Feng J, Tan HK, Ong YS. Primary treatment of mandibular ameloblastoma with segmental resection and free fibula reconstruction: Achieving satisfactory outcomes with low implantprosthetic rehabilitation. *J Plast Reconstr Aesthet Surg.* 2014;67:498–505.
- [3] Hasegawa T, Imai Y, Takeda D, Yasuoka D, Ri S, Shigeta T. Retrospective study of ameloblastoma: the possibility of conservative treatment. *Kobe J Med Sci.* 2013;59:112–21.
- [4] OA Effiom, OM Ogundana, AO Akinshipo, SO Akintoye. Ameloblastoma: current etiopathological concepts and management. *Oral Diseases.* 2018: 307 – 316.
- [5] Sharma A, Shaikh AM, Deshmukh SV, Dabholkar JP. Radical management of giant ameloblastomas: a case series. *Indian J Otolaryngol Head Neck Surg.* 2012;64:399–401.
- [6] Larsson A, Almerén H. Ameloblastoma of the jaws. An analysis of a consecutive series of all cases reported to the Swedish Cancer Registry during 1958--1971. *Acta Pathol Microbiol Scand A.* 1978;86A:337–49.
- [7] Rajendran R. Cyst and tumors of odontogenic origin. In: Rajendran R, Sivapathasundharam B, editors. *Shafer's Text Book of Oral Pathology.* 7th ed. Noida: Elsevier; 2012. pp. 259–313.
- [8] Chapelle KA, Stoelinga PJ, de Wilde PC, Brouns JJ, Voorsmit RA. Rational approach to diagnosis and treatment of ameloblastomas and odontogenic keratocysts. *Br J Oral Maxillofac Surg.* 2004;42:381–90.
- [9] Gardner DG, Corio RL. Plexiform unicystic ameloblastoma. A variant of ameloblastoma with a low-recurrence rate after enucleation. *Cancer.* 1984;53:1730–5.
- [10] Philipsen HP, Reichart PA, Nikai H, Takata T, Kudo Y. Peripheral ameloblastoma: Biological profile based on 160 cases from the literature. *Oral Oncol.* 2001;37:17–27.
- [11] Philipsen HP, Reichart PA, Takata T. Desmoplastic ameloblastoma (including “hybrid” lesion of ameloblastoma). Biological profile based on 100 cases from the literature and own files. *Oral Oncol.* 2001;37:455–60.
- [12] Chukwunke FN, Ajuzieogu O, Chukwuka A, Okwuowulu T, Nnodi P, Oji C. Surgical challenges in the treatment of advanced cases of ameloblastoma in the developing world: The authors' experience. *Int J Oral Maxillofac Surg.* 2010;39:150–5.

Legends for illustrations

Table-1: Case evaluation

	CASE-I	CASE-2	CASE-3
Age at presentation	40/M	60/F	34/F
Site of Occurrence	Lt. Parasymphiseal region, Body, Ramus & Condyle	Lt. Parasymphiseal region to Rt. Angle of mandible	Rt. Body, Ramus, upto sub condylar region.
Radiographic Evaluation	Bicortical expansion – Present	Bi-cortical expansion – Present	Bi-cortical expansion – present

	MULTILOCULAR a) Soap Bubble appearance b) Root resorption present c) Marginal cortical sclerosis present	a) Honey comb appearance with irregular margins b) Root resorption present c) Marginal cortical sclerosis present d) Specks of calcification	MULTILOCULAR a) Soap bubble appearance b) Root resorption present
Provisional Diagnosis	Ameloblastoma (conventional)	a) Ameloblastoma b) Calcifying epithelial odontogenic cyst	Ameloblastoma (Conventional)
Histopathologic Diagnosis	PLEXIFORM	FOLLICULAR/ PLEXIFORM / ACANTHOMATOUS	GRANULAR – more clinically aggressive
Treatment Done	Enblock excision with normal margins	Enblock excision	Enblock excision with normal margins

Figures

Case 1

Figure_1a and 1b: Extraoral and intraoral clinical images showing the extraoral and intraoral extent of the swelling.

Figure 2a and 2b: Lateral oblique view and Panoramic view shows soap bubble appearance and root resorption.

Figure 3: The epithelium is seen proliferating as cords in this plexiform type of ameloblastoma in this photomicrographic view.

Figure 4a and 4b: Post-operative view of the patient after surgery

Case 2:

Figure 1a and 1b: Frontal and lateral view of the patient showing the extraoral extent of the lesion

Figure 2: Intraoral view showing the intraoral extent of the lesion and also bicortical expansion.

Figure 3a and 3b: Panoramic and occlusal radiographic views showing the honeycomb appearance in the left anterior region with irregular margins and the rest of the lesion appears radiolucent due to cystic degeneration.

Figure 4a, 4b, and 4c: Axial CT views showing the extent, bicortical expansion and honeycomb appearances.

Figure 5a and 5b: Low power and High power photomicrographic views showing islands, strands or cords of epithelium with squamous metaplasia representing a mixture of follicular/plexiform/acanthomatous variety.

Case 3:

Figure 1a and 1b: Frontal and lateral clinical view showing the extra oral extent of the lesion.

Figure 2a and 2b: Panoramic view and the lateral oblique view showing the anterior extent of the lesion along with root resorption and soap bubble appearances.

Figure 3a and 3b: Axial and 3D CT views depicting the soap bubble appearances and the extent of bone destruction.

Figure 4a and 4b: Low power and high power photomicrographic views revealing the presence of granular cells within the strands and cords of epithelium.

Figure 5a and 5b: Postoperative radiographic and 3D CT views.

CASE 1:

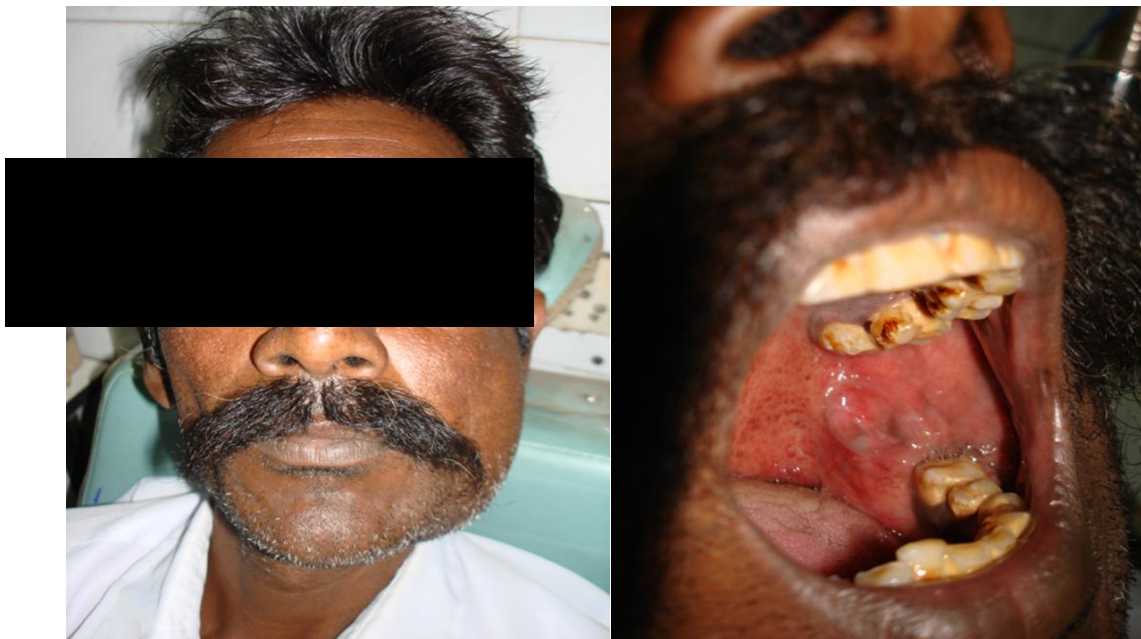

Figure 1a and 1b: Extraoral and intraoral clinical images showing the extraoral and intraoral extent of the swelling.

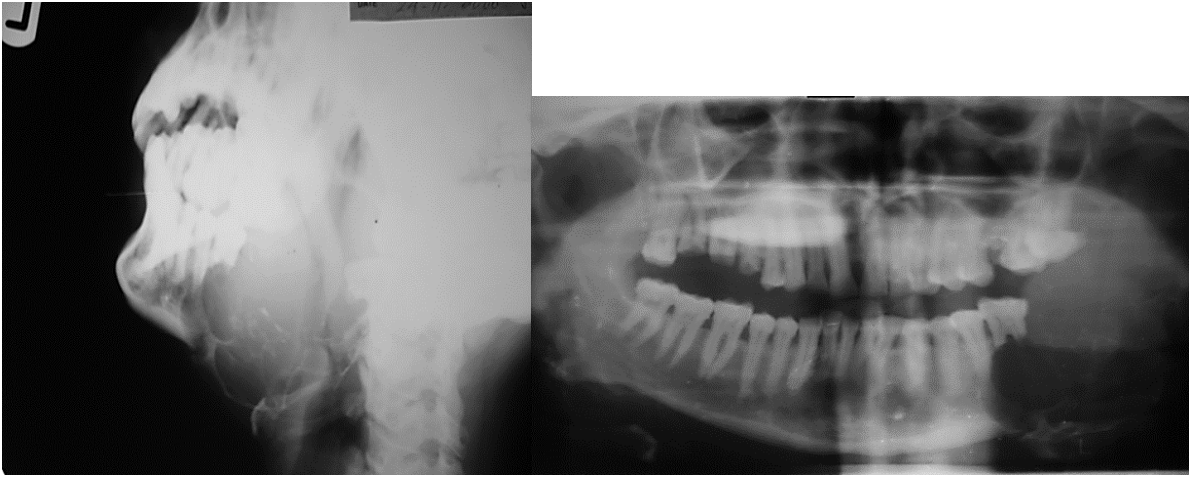


Figure 2a and 2b: Lateral oblique view and Panoramic view shows soap bubble appearance and root resorption.

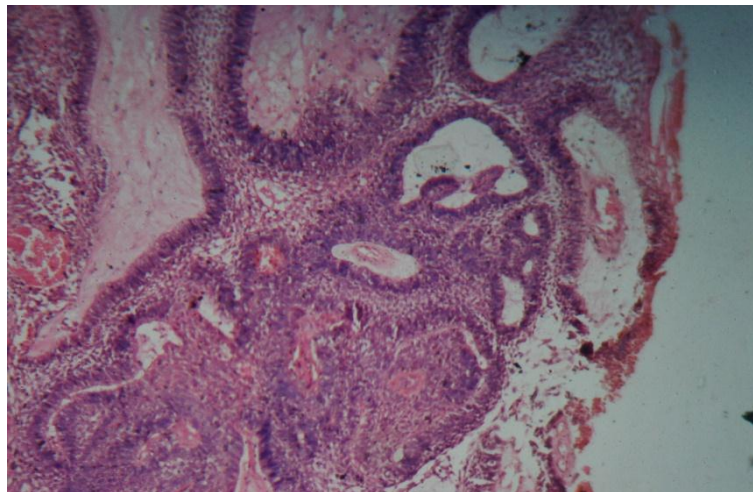


Figure 3: The epithelium is seen proliferating as cords in this plexiform type of ameloblastoma in this photomicrographic view.

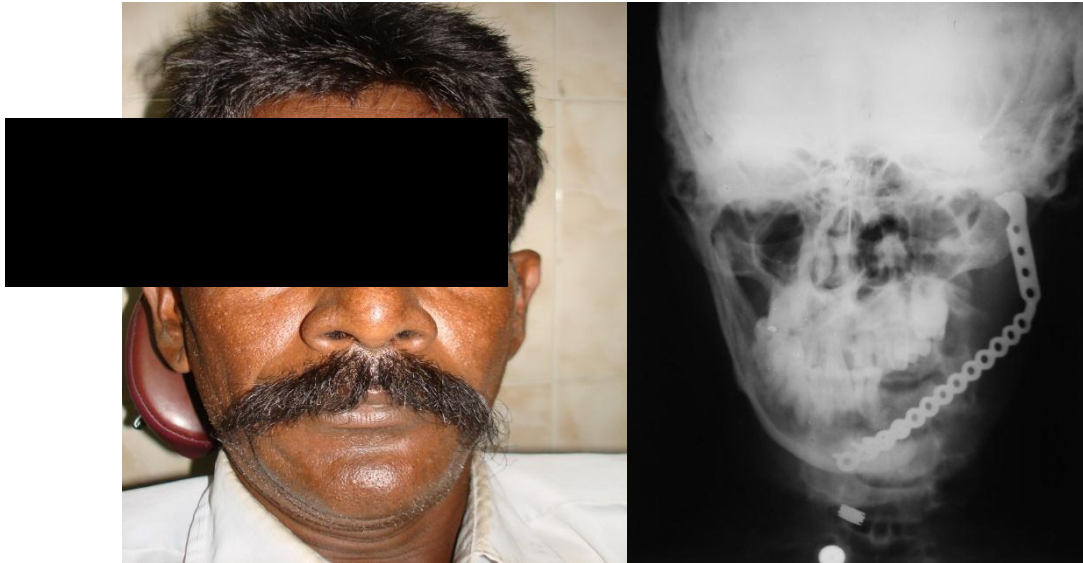

Figure 4a and 4b:Post-operative view of the patient after surgery

CASE 2:

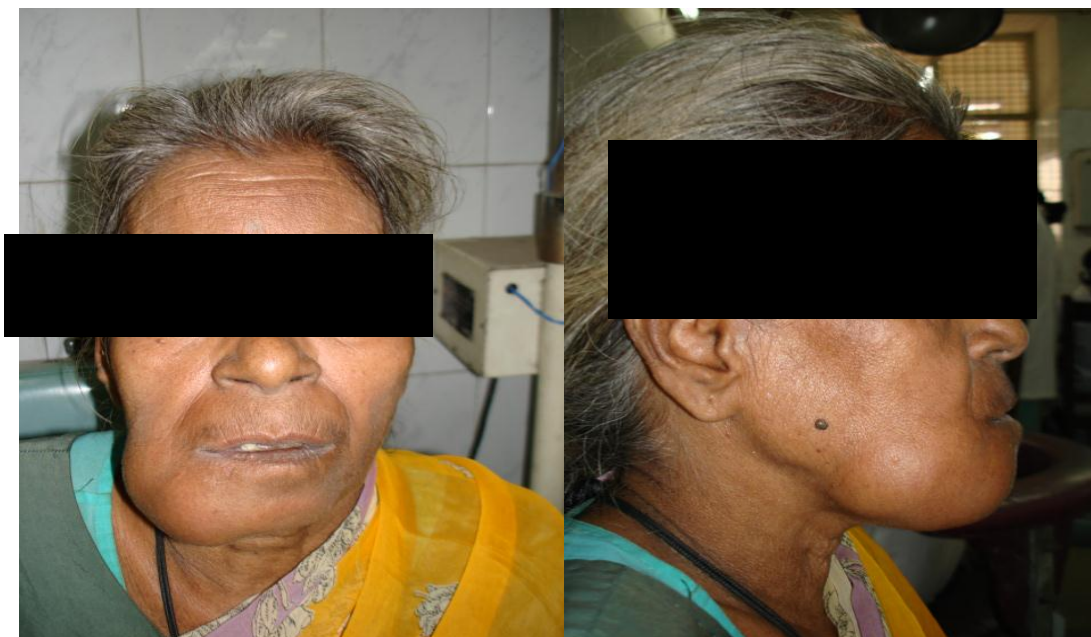

Figure 1a and 1b: Frontal and lateral view of the patient showing the extraoral extent of the lesion

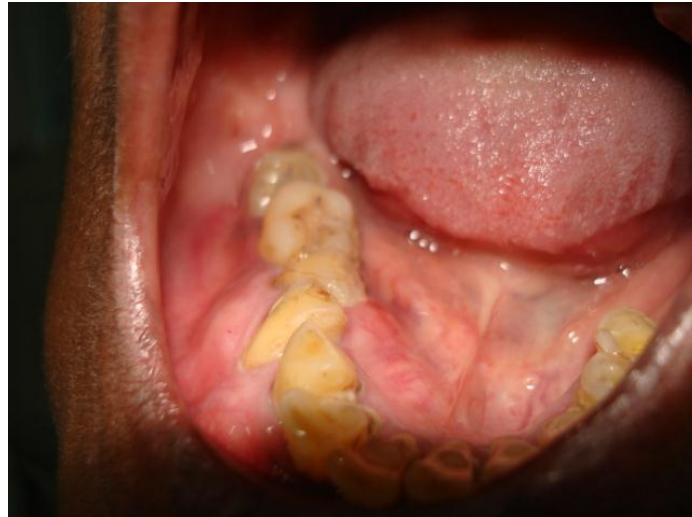

Figure 2: Intraoral view showing the intraoral extent of the lesion and also bicortical expansion.

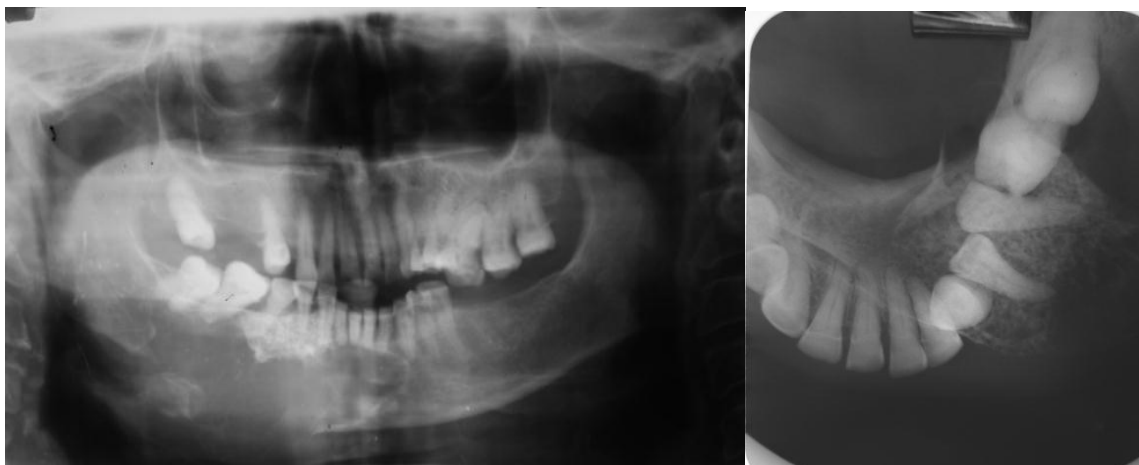


Figure 3a and 3b: Panoramic and occlusal radiographic views showing the honeycomb appearance in the left anterior region with irregular margins and the rest of the lesion appears radiolucent due to cystic degeneration.

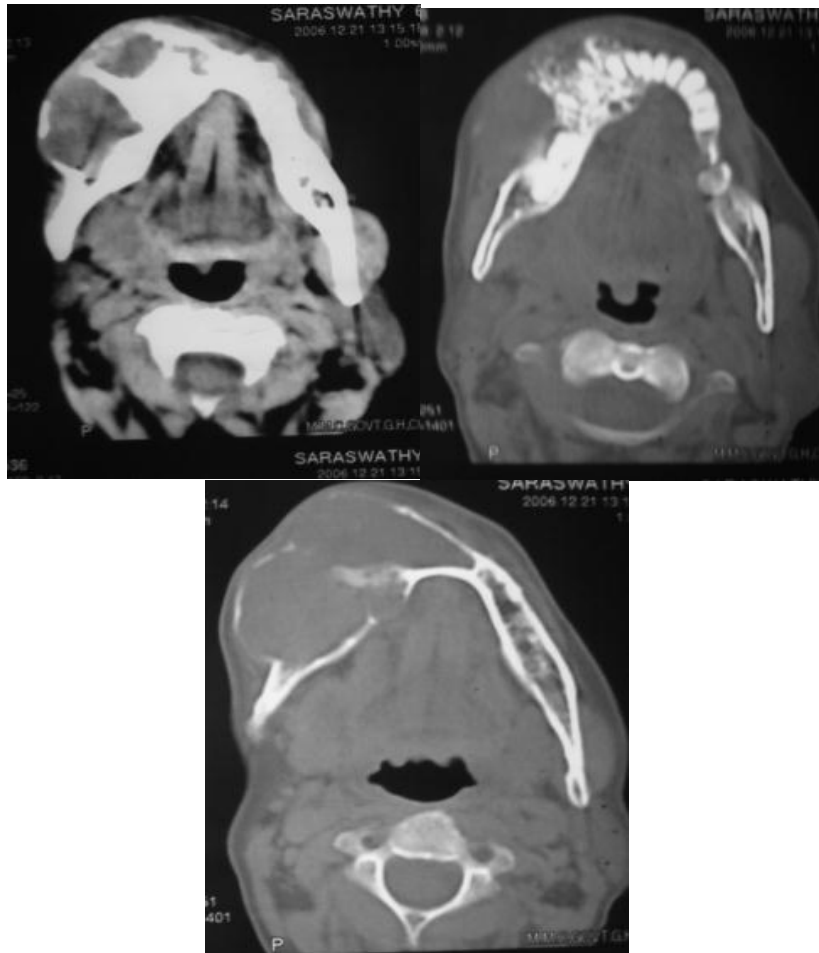


Figure 4a, 4b, and 4c: Axial CT views showing the extent, bicortical expansion and honey comb appearances.

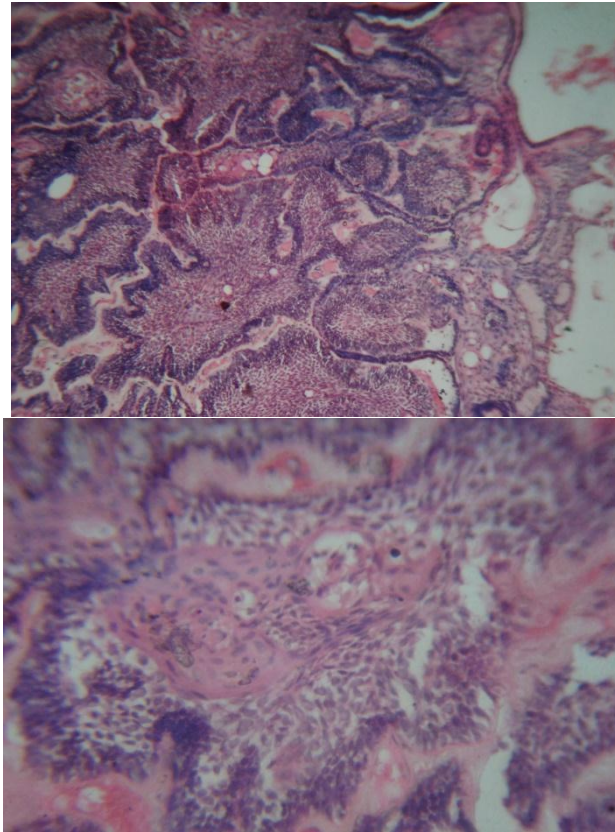


Figure 5a and 5b: Low power and High power photomicrographic views showing islands, strands or cords of epithelium with squamous metaplasia representing a mixture of follicular/plexiform/acanthomatous variety

CASE 3:

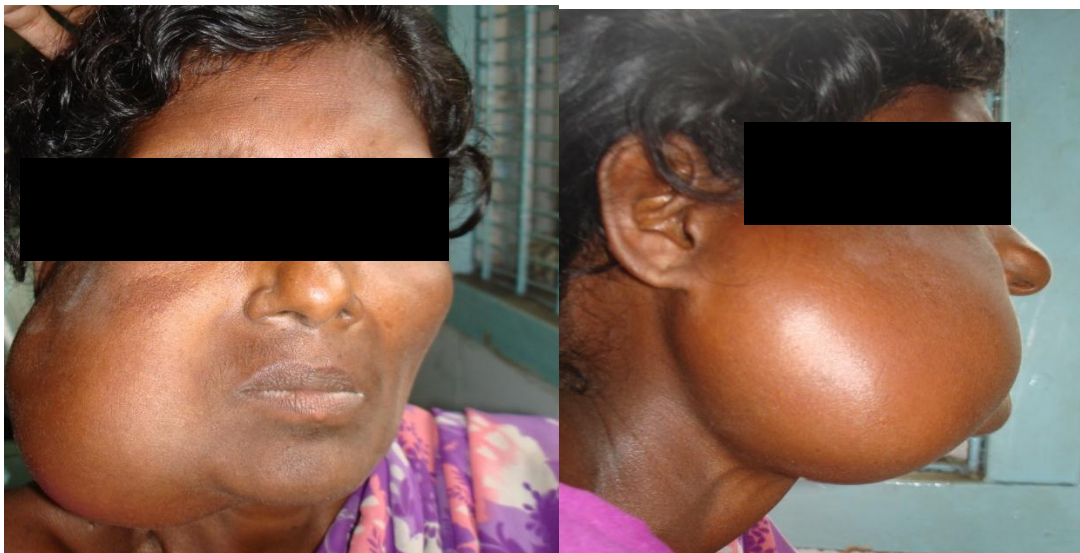

Figure 1a and 1b: Frontal and lateral clinical view showing the extra oral extent of the lesion.

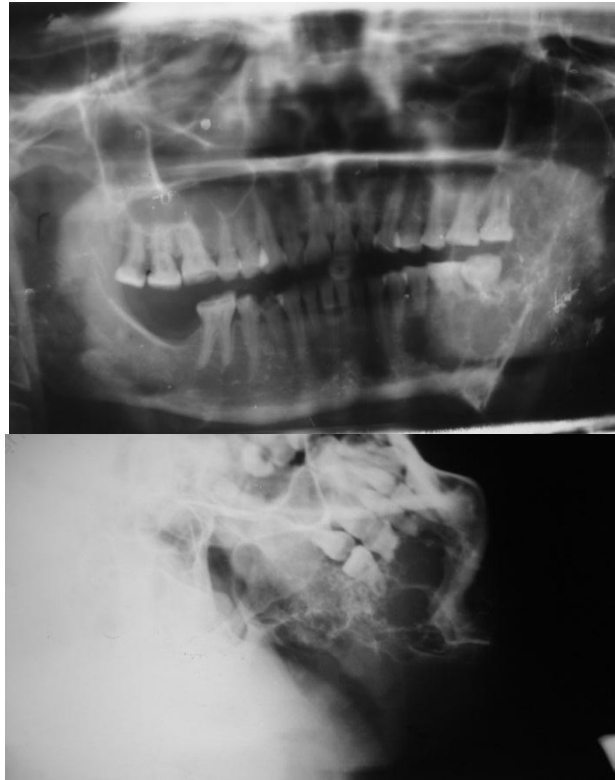

Figure 2a and 2b: Panoramic view and the lateral oblique view showing the anterior extent of the lesion along with root resorption and soap bubble appearances.

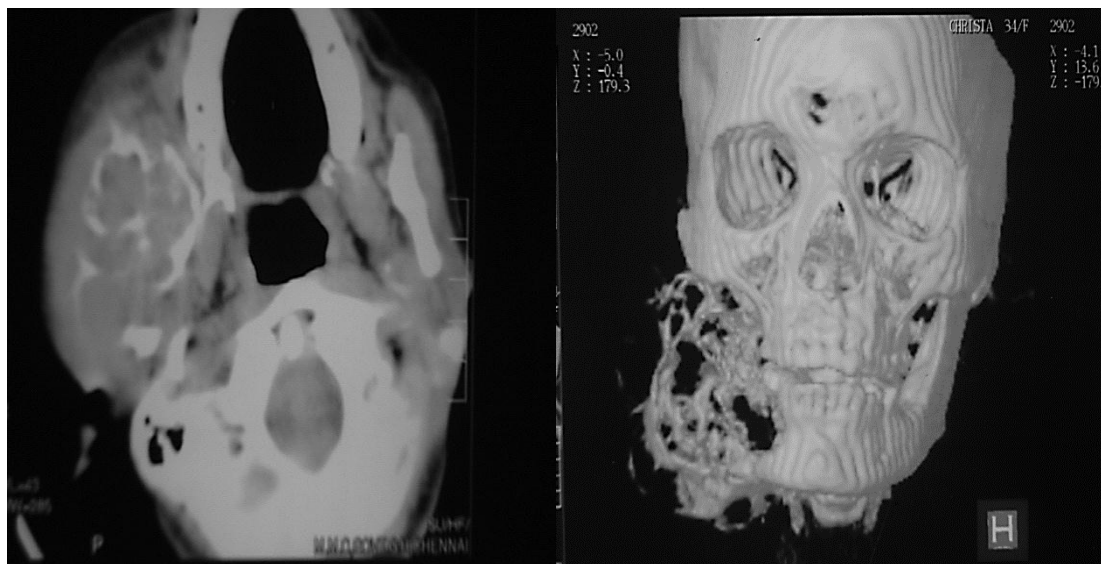


Figure 3a and 3b: Axial and 3D CT views depicting the soap bubble appearances and the extent of bone destruction.

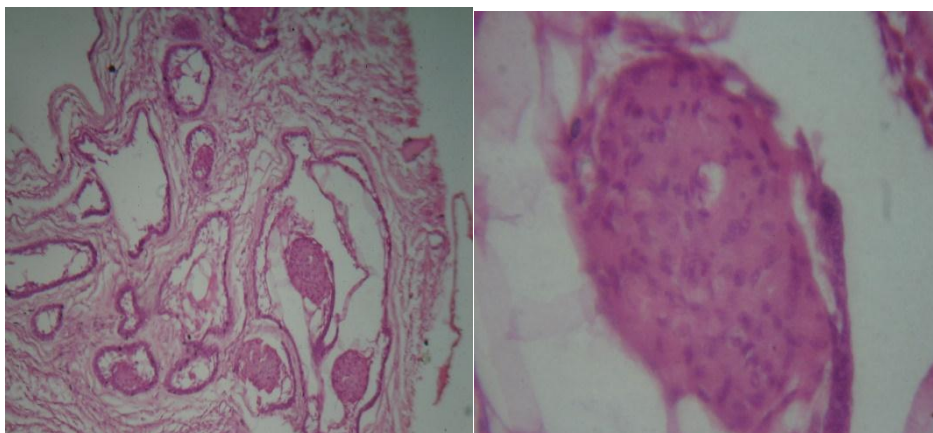


Figure 4a and 4b: Low power and high power photomicrographic views revealing the presence of granular cells within the strands and cords of epithelium.

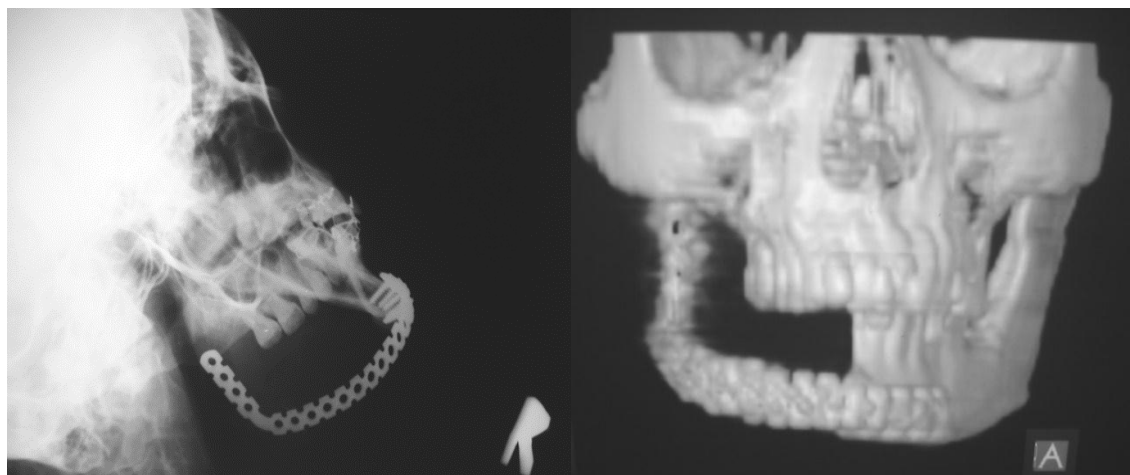

Figure 5a and 5b: Postoperative radiographic and 3D CT views.