

Original Research Article

“ROLE OF CT UROGRAPHY IN CASE OF HEMATURIA”

Dr. Bharat Lal Ahirwar¹(PG Resident 3rd year), Dr. Sukrati Shrivastava²(PG Resident 3rd year), Dr. Sheetal Singh³(Professor and Head) & Dr. Amlendu Nagar⁴(Professor)

Department of Radio-diagnosis, Index Medical College Hospital and Research Center, Indore M.P. PIN 452016^{1,2,3&4}

Corresponding Author: Dr. Amlendu Nagar

ABSTRACT

Aim: 1. To evaluate the role of CT urography in investigating causes of hematuria.
2. To determine the sensitivity and specificity of CT urography in evaluation and differentiation of the upper and lower urinary tract pathologies causing hematuria.

Material and methods: A prospective study of 75 patients with urinary Symptomatology was performed who presented at **Index Medical College Hospital and Research Center, Indore (M.P.)**. The study was conducted during the period from JAN 2021 to JUL 2022. 75 patients were referred for CT Examination. Almost all these patients were symptomatic and many had multiple symptoms related to urinary tract. However, pain was the predominant symptom in as many as 54 cases. Patient registration in form of individual details, clinical history, past history. Recording of previous X-Ray, USG, IVU & other relevant laboratory reports whenever available for evaluation.

Results: Majority of the subjects 68% were male and 32% were female. Majority of the subjects 78.7% had macro hematuria and 21.3% had micro hematuria. Majority of the subjects 72% had hematuria with symptoms and 28% had hematuria without symptoms. Majority of the subjects 36% had Calculi followed by 20% of the subjects had Neoplasm, 16% had Infection, 8% had trauma and 8% had developmental anomaly. Among the subject who had infection as cause for hematuria 100% of subject had hematuria with symptoms. Majority of the subjects who had carcinoma as cause for hematuria had without symptoms. 87.1% of the subject who had macro hematuria had symptoms and 57.1% did not had symptoms. 12.9% of the subject who had micro hematuria had symptoms and 42.9% did not had symptoms. Majority of the subjects who had calculi 48.1% had renal calculi followed by ureteric in 37% and vesical in 14.9%. Majority of the subjects who had developmental anomaly 33.3% had polycystic and ectopic kidney followed by horseshoe shaped kidney and duplication of ureter 16.7%. Equal number of the subjects who had trauma 33.3% had kidney, bladder and urethral injury.

Conclusion: Multidetector CT urography detects with high accuracy the entire spectrum of urinary tract pathologies causing hematuria in comparison with other modalities like X-ray and ultrasonography. Multi detector CT urography is highly sensitive and specific for detecting renal and urinary bladder masses. It is useful for further characterization and

staging of neoplastic masses. Thus, multidetector CT urography has the potential to become a one investigation for evaluation of urinary tract, especially in cases of hematuria.

Keywords: MDCT urography, hematuria, calculi, hydronephrosis, neoplasms, ureters.

1. INTRODUCTION

Hematuria is one of the many common manifestations of urinary tract pathologies such as calculi, neoplasm, infection, trauma, medications, coagulopathy, developmental anomalies, and renal parenchymal diseases and always warrants serious concern,¹ both to the patient as well as the treating physician.² Its reported prevalence does range from 0.2% to 21%.³ Hematuria, being one of the most common presentations of patients with urinary tract diseases, is a common reason for urinary tract imaging.⁴ Hematuria can originate from any site along the urinary tract and, whether gross or microscopic, may be a sign of serious underlying disease including malignancy.² The advanced MDCT scanners with its superior spatial resolution, higher speed, and isotropic reconstruction capability has ushered in a revolution in diagnostic imaging of urinary tract disorders.²

MDCTU can acquire thinly collimated data sets, which can be used to create excellent 3D quality images of the urinary tract.³ The MDCTU test has the capacity to function independently as a thorough "one-stop" procedure for imaging the upper and lower urinary tracts.⁵ It is especially appropriate for patients who have hematuria and need to have their urinary system checked for kidney and/or urothelial neoplasms as well as stone disease.⁵ MDCTU is also regarded as the "gold standard" imaging test for the assessment of renal parenchyma for renal masses in individuals with hematuria.⁵

The American Urological Association (AUA) guidelines recommended upper tract imaging for low-and high-risk patients with microscopic hematuria, defined as three or more Red Blood Cells (RBCs) per high-power field from two of three properly collected urinalysis specimens.⁴ Cross-sectional methods like MDCTU are less vulnerable to underlying bowel gas and better capable of detecting calculi and tiny cancers.⁴ The etiologies for gross and microscopic hematuria are vast and include multiple systems in numerous anatomic locations along the urinary tract. Organization of these etiologies using a combination of systems and anatomic approach can help the provider make the appropriate diagnosis and treatment.⁶

Purpose of imaging investigations for hematuria Imaging studies may be warranted when certain disease processes are suspected such as urolithiasis and malignancy. These studies include the Intravenous Pyelogram (IVP), CT, ultrasonography, and Magnetic Resonance Imaging (MRI).⁷

Hematuria is determined by nonimaging diagnosis of hematuria and radiology imaging of hematuria. In both the methods, radiologic imaging, plays a major role in the diagnosis of hematuria. However, the performances of individual imaging techniques within a specific diagnostic algorithm for hematuria have not been studied well. Diseases that are the primary causes of hematuria, such as urolithiasis, infections, Renal Cell Carcinoma (RCC), and Urothelial Cell Cancer, require to have their sensitivity and specificity reduced. There are different types of radiology imaging techniques, and each plays a different role in the investigation of hematuria.⁸ Imaging techniques have gained an increasingly crucial role in diagnosis of bladder cancer; in particular, Intravenous Urography (IVU) has been the reference standard for decades. Currently, ultrasound is the first choice of investigation in clinical practice, but requests for CT have also increased in recent days.⁹ CTU is an optimized examination for evaluating kidney or urinary tracts and includes high-resolution

excretory phase–enhanced CT. There are 2 major approaches in terms of contrast material delivery and CT acquisitions: a single-bolus contrast medium injection technique with 3 CT acquisitions during the unenhanced, nephrographic, and excretory phases (i.e., single-bolus CTU) and a split-bolus contrast medium injection technique with 2 CT acquisitions during the unenhanced and synchronous nephrographic and excretory phases (i.e., split-bolus CTU). One of the main problems with CTU, especially with the single-bolus CTU protocol, is a higher radiation exposure, however new imaging techniques have arisen to lower the radiation dosage of CTU.¹⁰

Aim:

1. To evaluate the role of CT urography in investigating causes of hematuria.
2. To determine the sensitivity and specificity of CT urography in evaluation and differentiation of the upper and lower urinary tract pathologies causing hematuria.

2. MATERIAL AND METHODS

A prospective study of 75 patients with urinary Symptomatology was performed who presented at **Index Medical College Hospital and Research Center, Indore (M.P.)**. The study was conducted during the period from JAN 2021 to JUL 2022.

Inclusion criteria:

- Patients presenting with hematuria referred to department of radio-diagnosis
- Patients having normal renal function as assessed by Serum Creatinine level & Estimated GFR (eGFR)
- Patients with good breath-holding capacity

Exclusion criteria:

- Patients below 17 and above 75 years of age.
- Severe renal failure
- Cardiac failure
- Previous allergic reaction to contrast media
- Pregnant and lactating patient

3. METHODOLOGY

75 patients were referred for CT Examination. Almost all these patients were symptomatic and many had multiple symptoms related to urinary tract. However, pain was the predominant symptom in as many as 54 cases.

Patient registration in form of individual details, clinical history, past history.

Recording of previous X-Ray, USG, IVU & other relevant laboratory reports whenever available for evaluation.

One litre of drinking water was given 30 minutes prior to the scan.

Oral positive iodinated contrast was given whenever necessary or requested by the consulting physician.

Patient position: Supine with axial images taken, with respiration suspended at mid–inspiration. Prone scans whenever necessary for demonstration. Hands were raised above the head.

To clear the area of interest of removable metal objects to avoid artifacts.

Breath-holding technique was practiced on table with patient, as it improves patient compliance, decreases patient anxiety and may lessen artifacts during acquisition.

Patients were informed about the experience of diffuse warmth at the end of the injection.

Intravenous injection: An intravenous line of no. 20 gauge intracath was taken on the forearm.

Contrast concentration used was 350 mg iodine/ml. Normally amount of contrast used was 80 ml. A saline chaser of 40 ml was used. Rate of injection was 3 ml per second (Using Auto-injector).

Equipment: All patients were scanned with a SIEMENS GO TOP 128-slice CT scanner equipped with a new feature in multislice CT technology, so called z-axis flying focus technology. A topogram was performed followed by a plain scan from a level just above the domes of diaphragm to the level of pubic symphysis. Then 3-phase CT Urography as described below was performed. Additional phases, e.g. arterial phase for renal tumors and delayed prone scans for demonstration of ureters were taken as and when needed. After the procedure, the patient was kept under observation for 15 to 30 minutes.

Image post-processing: The axial images were generated from the source raw data images. The slice thickness of 1.0 mm with reconstruction increment of -1.0 mm was used. The images were then transferred to a dedicated GE Workstation for image post-processing techniques. The various techniques used were Multiplanar Reconstruction (MPR), Maximum Intensity Projection (MIP), Curved Planar Reconstruction (CPR) and Volume Rendering Technique (VRT). Although from the radiological point of view, the axial images were sufficient to diagnose, the referring urologists/physicians preferred the 3D images. In addition to film interpretation, image interpretation was performed on the dedicated 3D (GE) Workstation in an interactive manner. Two or three dimensional post processing displays such as MPR, MIP, cMPR and VRT may be helpful for a first glance to see the course of the ureters. It should be considered that any 2D or 3D reconstruction may come along with a loss of spatial resolution. Smaller calculi for instance, which are visible in the axial source, may not be seen in volume rendered images and the diagnosis can be completely missed. Therefore the primary axial slices are superior to any post processing method.

4. RESULTS

Table 1. Distribution of the subjects according to the age group

Age group	No. of case	Percent %
18-27	11	14.7
28-37	13	17.3
38-47	10	13.3
48-57	20	26.7
58-67	9	12
68-75	12	16
Total	75	100

Majority of the subjects 26.7% were in 48-57 yrs age group followed by 17.3% were in 28-37yrs age group, 16% were in 68-75 yrs age group, 14.7% were in 18-27 yrs age group, 13.3% were in 38-47 yrs age group and 12% were in 58-67yrs age group. Majority of the subjects 68% were male and 32% were female.

Table 2. Distribution of the subjects according hematuria

Hematuria	No.of case	Percent %
Macro	59	78.7
Micro	16	21.3
Total	75	100

Majority of the subjects 78.7% had macro hematuria and 21.3% had micro hematuria. Majority of the subjects 72% had hematuria with symptoms and 28% had hematuria without symptoms.

Table 3. Distribution of the subjects according causes of hematuria

Cause	No.of case	Percent %
Calculi	27	36
Infection	12	16
Neoplasm	15	20
Developmental Anomaly	6	8
Trauma	6	8
Miscellaneous	9	12
Total	75	100

Majority of the subjects 36% had Calculi followed by 20% of the subjects had Neoplasm, 16% had Infection, 8% had Trauma and 8% had Developmental Anomaly.

Table 4. Distribution of the subjects according causes of hematuria and type of hematuria

Cause	Hematuria		Total
	Macro	Micro	
Calculi	23 (85.2%)	4(14.8%)	27 (100%)
Infection	7(58.3%)	5(41.7)	12 (100%)
Neoplasm	15(100%)	0	15 (100%)
Developmental Anomaly	3(50%)	3(50%)	6 (100%)
Trauma	6(100%)	0	6 (100%)
Miscellaneous	5(55.5%)	4(44.5%)	9 (100%)
Total	59(78.7%)	16(21.3%)	75 (100%)

Among the subject who had calculi as cause for hematuria 85.2% of subject had macro hematuria and 14.8% had micro hematuria. All the subjects who had neoplasm & trauma had macro hematuria. Majority of the subjects with infection had macro hematuria. Among the subject who had developmental anomaly as cause for hematuria 50% of subject had macro hematuria and 50% had micro hematuria.

Table 5. Distribution of the subjects according causes of hematuria and type of symptom

Cause	Hematuria		Total
	Symptom	Asymptomatic	
Calculi	23(85.2%)	4 (14.8%)	27
Infection	12 (100%)	0	12
Neoplasm	6 (40%)	9(60%)	15

Developmental Anomaly	0	6(100%)	6
Trauma	6(100%)	0	6
Miscellaneous	7(77.8%)	2(22.2%)	9
Total	54	21	75

Among the subject who had calculi as cause for hematuria 85,2%% had hematuria without symptoms. Among the subject who had infection as cause for hematuria 100% of subject had hematuria with symptoms. Majority of the subjects who had carcinoma as cause for hematuria had hematuria without symptoms.

Table 6. Distribution of the subjects according symptom and type of hematuria

Symptoms	Hematuria		Total
	Macro	Micro	
Symptomatic	47 (87.1%)	7(12.9%)	54
Asymtomatic	12 (57.1%)	9(42.9%)	21
Total	59	16	75

87.1% of the subject who had macro hematuria had symptoms and 57.1% did not had symptoms. 12.9% of the subject who had micro hematuria had symptoms and 42.9% did not had symptoms.

Table 7. Distribution of the calculi according location

Calculi	No. of case	Percent %
Renal calculi	13	48.1
Ureteric calculi	10	37
Vesical calculi	4	14.9
Total	27	100

Majority of the subjects who had calculi 48.1% had renal calculi followed by ureteric in 37% and vesical in 14.9%.

Table 8. Distribution of the calculi according sex

Calculi	No. of case	Percent %
Male	15	55.6
Female	12	44.4
Total	27	100

Majority of the subjects i.e. 55.6% who had calculi were male and rest were female.

Table 9. Distribution of the calculi cause of hydronephrosis

Cause	Hydronephrosis		Total
	Present	Absent	
Renal calculi	9 (69.2%)	4 (30.8%)	13
Ureteric calculi	10 (100%)	0	10
Vesical calculi	0	4(100%)	4
Total	19	8	27

69.2% of the subject who had renal calculi had hydronephrosis and 30.8% did not had hydronephrosis. 100% of the subject who had ureteric calculi had hydronephrosis. 100% of the subject who had vesical calculi did not had hydronephrosis.

Table 10. Distribution of the subjects according to infection

Infection	No. of case	Percent %
Renal	5	41.7
Bladder	6	50
Urethra	1	8.3
Total	12	100

Majority of the subjects who had infection 50% had bladder infection followed by renal in 41.7% and urethral in 8.3%.

Table 11. Distribution of the infection according sex

Infection	No. of case		Percent %
	Male	Female	
Renal	3 (60%)	2(40%)	5
Bladder	3 (50%)	3 (50%)	6
Urethra	1 (100%)	0	1
Total	7	5	12

60% of the subject who had renal infection were male and 40% were female. 50% of the subject who had bladder infection were male and 50% were female. 100% were male with urethral infections.

Table 12. Distribution of the subjects according to neoplasm

Neoplasm	No. of case	Percent %
Renal ca.	7	46.6
Bladder ca.	4	26.7
Urethral ca.	0	0
Prostate ca.	4	26.7
Total	15	100

Majority of the subjects who had neoplasm 46.6% had renal carcinoma followed by Ca bladder and Ca prostate 26.7%.

71.4% of the subject who had renal cancer were male and 28.6% were female. 100% of the subject who had bladder cancer were male.

Table 13. Distribution of the subjects according to developmental anomaly

Developmental Anomaly	No. of case	Percent%
Polycystic kidney	2	33.3
Horseshoe shape	1	16.7
Ectopic kidney	2	33.3
Duplication of ureter	1	16.7
Total	6	100

Majority of the subjects who had developmental anomaly 33.3% had polycystic and ectopic kidney followed by horseshoe shaped kidney and duplication of ureter 16.7%.

50% of the subject who had polycystic kidney and ectopic kidney were male and 50% were female. 100% of the subject who had horseshoe shaped kidney and duplication of ureter were male.

Table 14. Distribution of the subjects according to trauma

Trauma	No. of case	Percent%
Kidney injury	2	33.3
Bladder injury	2	33.3
Urethral injury	2	33.3
Total	6	100

Equal number of the subjects who had trauma 33.3% had kidney, bladder and urethral injury.

100% of the subject who had kidney, bladder and urethral injury were male.

Table 15. Distribution of the subjects according to miscellaneous

Miscellaneous	No. of case	Percent%
BPH (benign prostatic hyperplasia)	4	44.5
Renal cysts	2	22.2
Post operative	1	11.1
Urethral stricture	2	22.2
Total	9	100

Majority of the subjects in miscellaneous who had BPH 44.5% followed by renal cysts and urethral stricture 22.2% and post-operative were 11.1%.

100% of the subject who had BPH and urethral stricture were male. Equal number of male and female subjects of renal cysts. 100% of the subjects who had post-operative category were females.

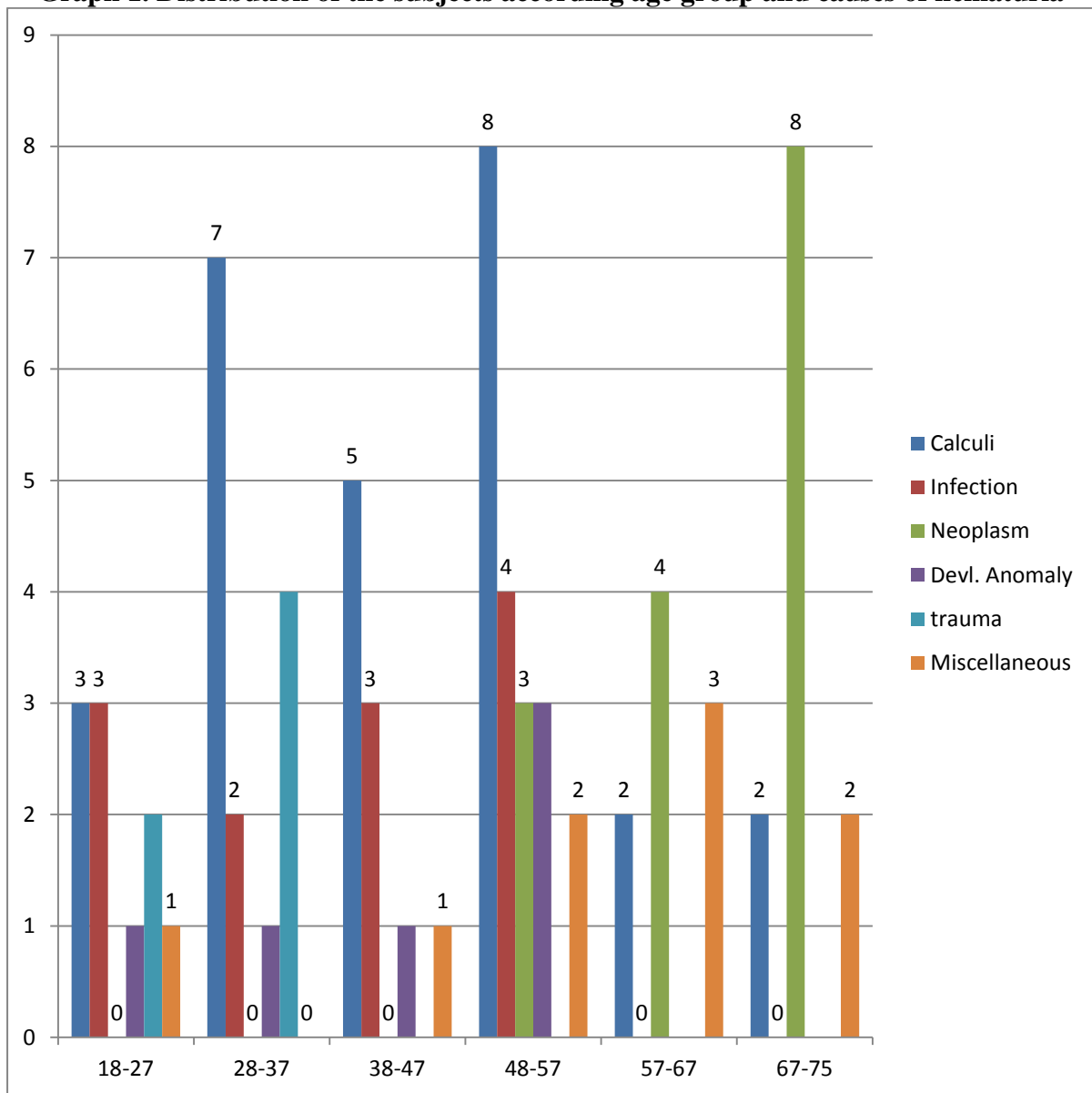
Table 16. Distribution of the subjects according age group and causes of hematuria

Age group	Calculi	Infection	Neoplasm	Developmental Anomaly	Trauma	Miscellaneous
18-27	3 (11.1%)	3 (25%)	0	1 (16.7%)	2(33.3%)	1 (11.1%)
28-37	7 (25.9%)	2 (16.7%)	0	1 (16.7%)	4 (66.7%)	0
38-47	5 (18.6%)	3 (25%)	0	1 (16.7%)	0	1 (11.1%)
48-57	8 (29.6%)	4 (13.3%)	3 (20%)	3 (50%)	0	2 (22.2%)
57-67	2 (7.4%)	0	4 (26.7%)	0	0	3 (33.3%)
67-75	2 (7.4%)	0	8 (53.3%)	0	0	2 (22.2%)
Total	27	12	15	6	6	9

Among the subject who had calculi 29.6% were in 48-57yrs, 25.9% in 28-37 yrs, 18.6% in 38-47 yrs age group, 11.1% in 18-27yrs age group and 7.4% in 57-67 yrs and 67-75 yrs age group. Among the subject who infection 25% were in 18-27 yrs and 38-47yrs and 16.7% in 28- 37yrsage group and 13.3% in 48-57 yrs age group.

Among the subject who had neoplasm 53.3% were in 67-75yrs and 26.7% in 57-67 yrs and 20% in 48-57 yrs. Among the subject who had developmental anomaly 50% were in 48-57yrs,16.7% in 18-27yrs, 28- 37 yrs age group and 38-47 yrs age group. Among the subject who had trauma 66.7% were in 28-37yrs and 33.3% in 18-27 yrs.

Graph 1. Distribution of the subjects according age group and causes of hematuria



5. DISCUSSION

One of the most typical symptoms of disorders of the urinary system is hematuria. It has a variety of causes, including calculi, neoplasms, infections, trauma, medicines, coagulopathies, and renal parenchymal disorders, and it can develop from any point along the urinary system. The evaluation of urological malignancies is perhaps the most crucial factor in determining the importance of these patients in order to make an early and correct diagnosis. As a result, highly sensitive exams are crucial for neoplasm detection. It's also crucial to be able to identify additional potential causes of hematuria.

Present study comprised of 75 patients who presented with hematuria (both macroscopic and microscopic) and were referred to radiology department for work up with CT urography. All the patients underwent CT urography and diagnosis was established after analyzing all the

phases of study with required post processing techniques. In this study the macroscopic hematuria was seen in 59 patients which constituted 78.7% and microscopic hematuria was seen in 16 patients which constituted 21.3% .

In this study, prevalence of painful hematuria (54) was more common than painless haematuria (21). Macroscopic hematuria constitutes (78.7%) which was more than microscopic hematuria. Abdominal pain was the most common complaint other than hematuria followed by fever. In these 75 patients, the cause of hematuria was divided into uro-lithiasis, infective, neoplasm, developmental anomalies, traumatic, and other miscellaneous conditions.

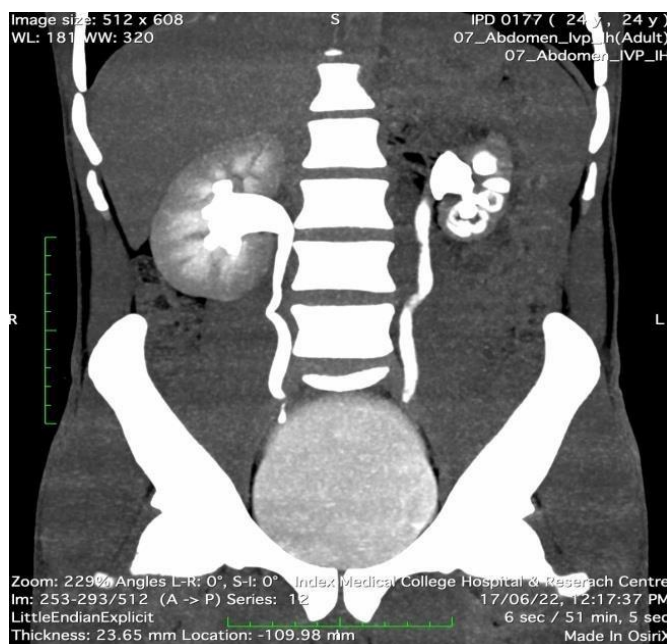


Figure 1. Normal CT Urogram coronal image

Urolithiasis: In the present study, CT Urography detects 27 patients having urolithiasis (small calculi as well as staghorn calculus) as the cause for hematuria including renal, pelviureteric junction, ureteric, vesico-ureteric junction and vesical calculi and which constitutes to nearly about 36% in the total number of cases and thus becomes the main cause of hematuria in the present study. Urolithiasis was identified as the source of microscopic hematuria in roughly 24% of patients in a study by Mahmoud MA et al (2015) on the use of Multi-detector row computed tomography urography (MDCTU) in the evaluation of microscopic hematuria in adults.¹¹ The majority of urolithiasis patients exhibit excruciating microscopic hematuria, and in the current investigation, the ureteric (35%) and VUJ (23%) regions were the most often affected. Most urolithiasis patients also have hydronephrosis, with ureteric calculus being the most frequent cause of this condition.

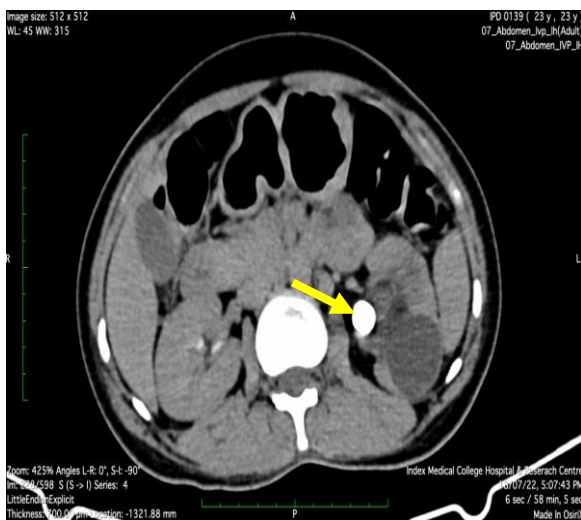


Fig 2. Left Renalcalculus with hydronephrosis axial view

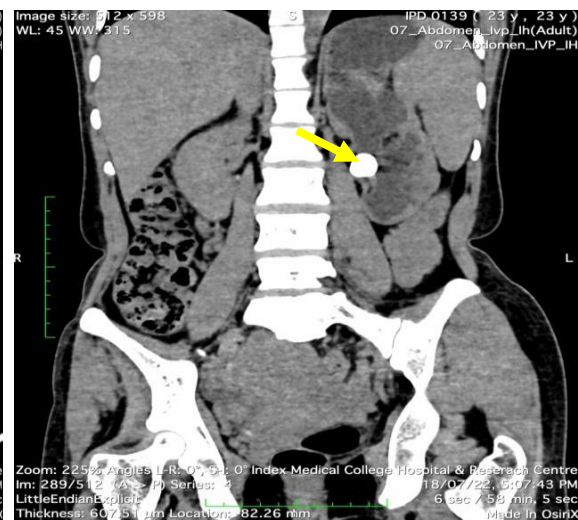


Fig3. Left Renal calculus with hydronephrosis coronal view

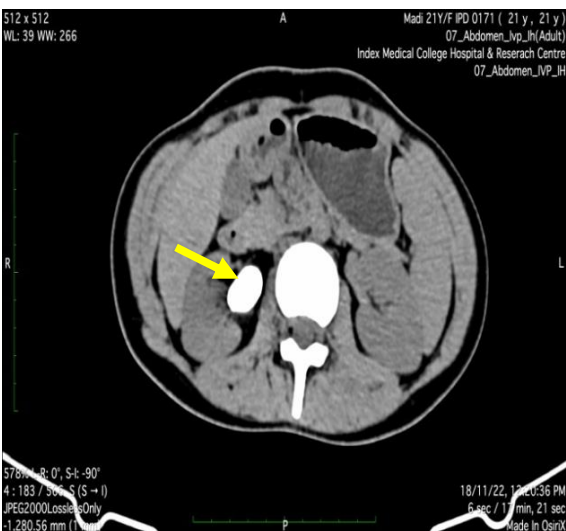


Fig 4. Right Staghorn calculs axial view

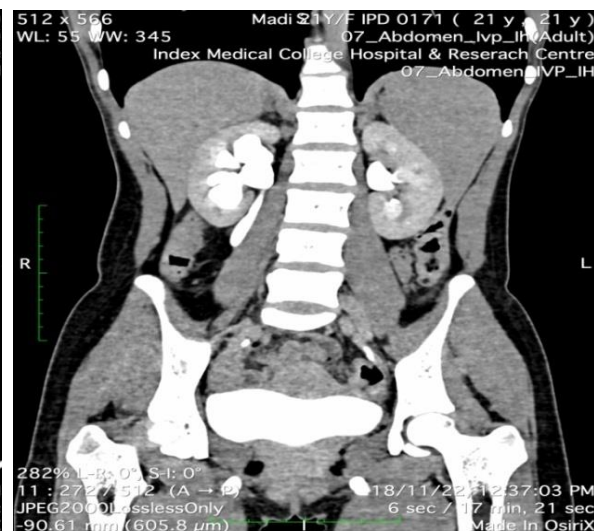

Fig 5. Right staghorn calculus contrast enhance coronal view

Infection: In present study 6 cases, presented with fever since 2 months, weight loss and on urine examination red blood cells were noted and on further investigation with CT urography, it revealed thimble shaped bladder with circumferential wall thickening. **O'malley ME et al(2003)**, similar study conducted on patients presenting with painless hematuria in sample of 91 patients by CT urography, about two patients confirmed of cystitis.¹² **Shinagare AB et al (2011)**, described many infective and inflammatory causes of bladder such as cystitis which simulate as bladder carcinoma on CT urography and concluded that they should be confirmed by cystoscopic biopsy.¹³

Developmental Anomaly: In present study, a case of 56 year old female patient presented with microscopic painless hematuria. On CT urographic evaluation, cause of hematuria was found to be ectopic kidney with renal calculus, both acting synergistically as cause for hematuria in the present case. In a similar study by **Bhoil R et al(2015)**, described a similar case of ectopic kidney with renal calculus as source of hematuria. In present study, another male patient of 50 years age, presented with painless hematuria and revealed horseshoe kidney with renal calculus on CT urography as cause of hematuria.¹⁴ CT urography detect

most anomalies of renal position, number, and form. The exact orientation and position of the ureters and pelvicalyceal system can be determined. The superior z-axis reconstructions with multidetector CT aid in obtaining high diagnostic quality three dimensional reconstructions, particularly in the coronal plain (**Kalra et al.**).¹⁵ In our study we detected 2 cases of ectopic kidney, 2 cases of adult polycystic kidney, 1 case of pelvicalyceal and ureteric duplication and 1 case of horseshoe kidney.

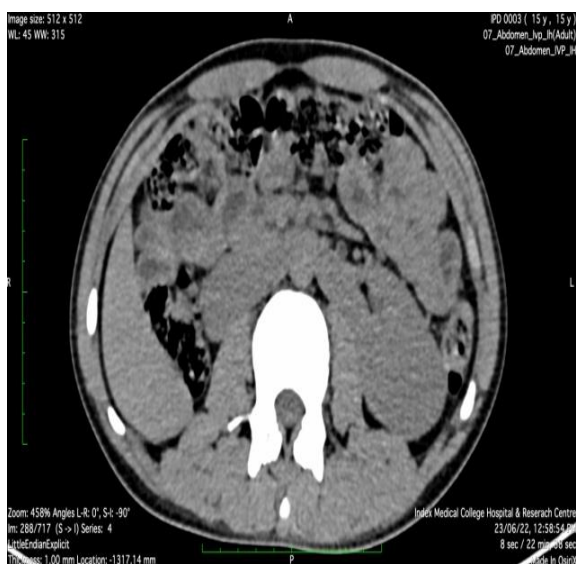


Fig 6. Horseshoe shape kidney axial view

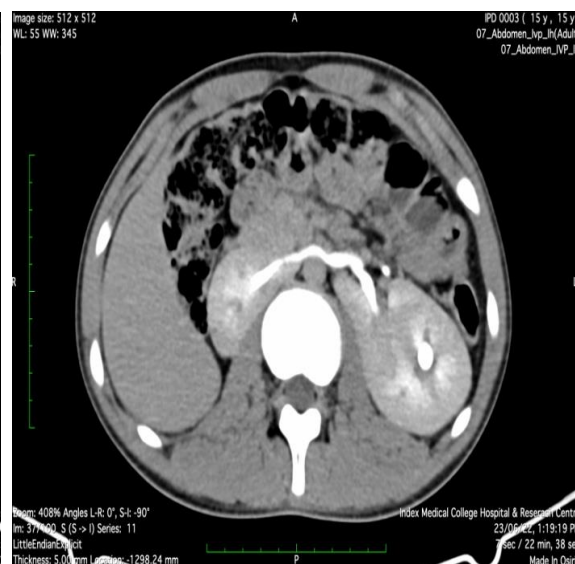

Fig 7. Horseshoe shape kidney contrast axial view

Trauma: In present study, 6 cases of trauma were evaluated who presented with painful macroscopic hematuria. They underwent CT urographic examination that revealed contrast extravasation into peritoneal cavity in pyelographic delayed scans and was diagnosed as a case of intra-peritoneal bladder rupture. Nephrogenic phase is helpful in diagnosing upper urinary tract injuries (mostly renal injuries) and pyelographic phase is helpful in diagnosing lower urinary tract injuries (mostly bladder injuries). Important anatomical and physiological data from CT urography helps doctors manage injuries to the urinary tract. It aids in the precise assessment of pelvicalyceal disruption, the degree of perirenal bleeding, the extent of parenchymal devascularization, and the existence of significant vascular pedicle damage. (**Kalra et al.**).¹⁵

Neoplasms: There were 15 cases of neoplasm in our study, 7 of renal, 4 of urinary bladder and 4 of prostate. In malignant cases the predominant age group in present study was above 50 years and almost all the cases presented with painless macroscopic hematuria along with abdominal mass.

In present study, a total of 7 renal neoplasms were identified as cause of hematuria out of which 6 were detected to be malignant, 1 case was benign neoplasm. Bladder carcinoma was found to be a major cause of hematuria in lower urinary tract neoplasms in the present study. All the cases of lower urinary tract neoplasms presented with macroscopic painless hematuria. Lower urinary tract neoplasms were about 26.7% of all cases, that is about 4 cases. In a study by **Chow NC et al**, 500 patients (327 patients with painless hematuria) underwent CT urography for urinary tract abnormalities and it was concluded that CT urography detected all proven cases of renal cell carcinoma yielding high sensitivity and

specificity.¹⁶ Venous phase images in coronal plane reveal heterogeneously enhancing soft tissue mass lesion involving the upper pole of right kidney with extension of tumor thrombus into the ipsilateral renal vein & IVC, a feature highly suggestive of renal cell carcinoma. Final histopathological diagnosis was high-grade renal cell carcinoma. Prostate carcinoma was identified as cause of haematuria in lower urinary tract neoplasms in the present study. All the cases of lower urinary tract neoplasms presented with macroscopic painless hematuria. Prostate carcinomas were about 26.7% of all cases, that is about 4 cases.

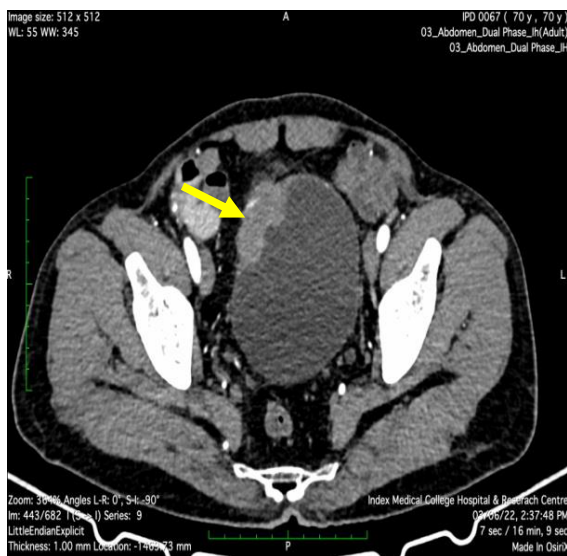


Fig 8. Right lat. wall of Bladder carcinoma contrast axial view

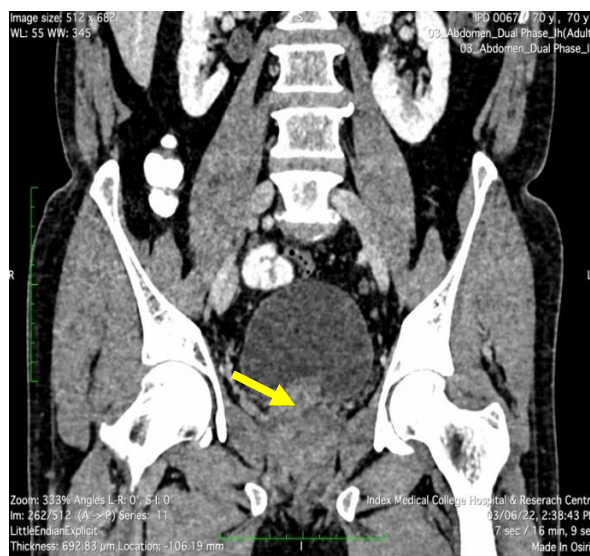


Fig 9. Right lat. wall of Bladder carcinoma contrast coronal view

Miscellaneous: Ct urography revealed BPH, urethral stricture, post operative and multiple simple and complex cysts, in kidneys with no involvement of other organs. In present study, about 4 cases presenting with macroscopic hematuria were detected on CT urography as having BPH. In present study, about 2 cases presenting with microscopic hematuria were confirmed on CT urography as having cysts in kidneys. Diagnostic accuracy of CT Urography in evaluating the etiology of hematuria.

In present study group of 75 patients, all the patients having upper urinary tract pathologies were diagnosed accurately with CT urography. There were no false negatives or false positive results among those patients of upper urinary tract pathologies.

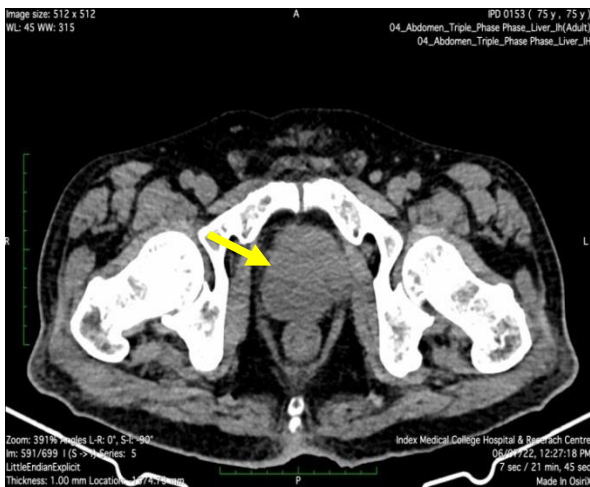


Fig 10. Prostatomegaly axial view

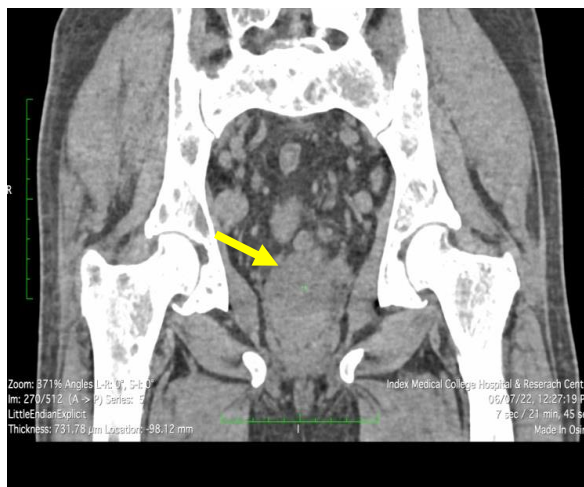


Fig 11. Prostatomegaly coronal view

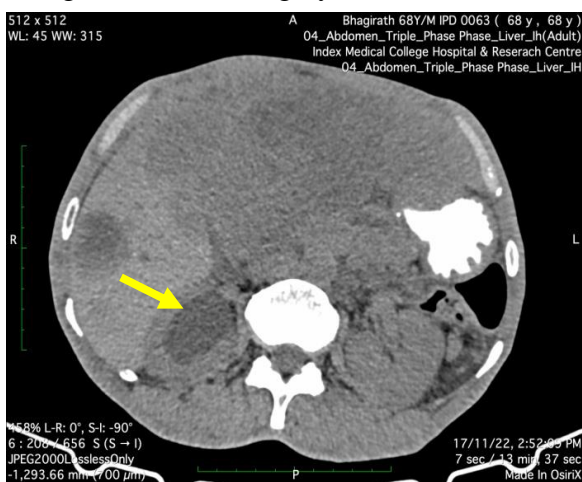


Fig 12. Right Renal cyst axial view

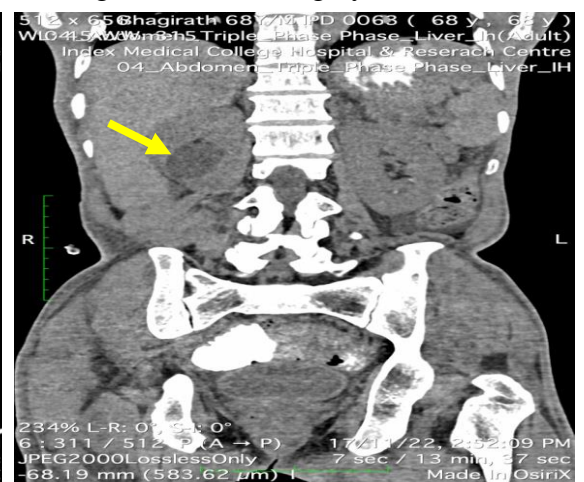


Fig 13. Right Renal cyst coronal view

6. CONCLUSION

Multidetector CT urography detects with high accuracy the entire spectrum of urinary tract pathologies causing hematuria in comparison with other modalities like X-ray and ultrasonography. Multi detector CT urography is highly sensitive and specific for detecting renal and urinary bladder masses. It is useful for further characterization and staging of neoplastic masses. Thus, multidetector CT urography has the potential to become a one investigation for evaluation of urinary tract, especially in cases of hematuria. Even through dedicated protocols, side effects of contrast material, radiation exposure and time consumption are limitations of MDCTU.

7. REFERENCES

1. Kadam SM and Patel P. Role Of Multidetector CT Urography In Evaluation Of Patients with Haematuria. *Indian Journal of Research, Paripex*. 2017;2:64–66.
2. Rathi V, Shah S, Nimbalkar C, et al. Role of multidetector ct urography in evaluating patients with haematuria. *Journal of Evolution Of Medical And Dental Sciences-JEMDS*. 2016;5(59):4130–6.
3. Kumar R, Airon RK, Mittal A, et al. Evaluation of Multidetector Computed Tomography in Haematuria. *Maedica*. 2017;12(2):87.
4. Choyke PL. Radiologic evaluation of hematuria: guidelines from the American College of Radiology's appropriateness criteria. *American family physician*. 2008;78(3):347–52.
5. Maher MM, Kalra MK, Rizzo S, et al. Multidetector CT urography in imaging of the urinary tract in patients with hematuria. *Korean journal of radiology*. 2004;5(1):1–0.
6. Tilak P, Hyder ZZ, Moeller A, et al. Evaluation and Workup of Hematuria in Adults. *Physician Assistant Clinics*. 2018;3(1):23–35.
7. Karnath BM, Rodriguez G, and Narat R. Evaluation of hematuria. *Hospital Physician*. 2007;43(4):20.
8. van der Molen AJ and Hovius MC. Hematuria: a problem-based imaging algorithm illustrating the recent Dutch guidelines on hematuria. *American Journal of Roentgenology*. 2012;198(6):1256– 65.
9. Capalbo E, Kluzer A, Peli M, et al. Bladder cancer diagnosis: the role of CT urography. *Tumori Journal*. 2015;101(4):412–7.
10. Takeuchi M, Konrad AJ, Kawashima A, et al. CT urography for diagnosis of upper urinary tract urothelial carcinoma: are both nephrographic and excretory phases necessary?. *American Journal of Roentgenology*. 2015;205(3):W320–7.
11. Mahmoud MA, Mahmoud MZ, Omer MA, et al. Multi-Detector Row Computed Tomography Urography (MDCTU) in the Evaluation of Microscopic Hematuria in Adults. *Open Journal of Radiology*. 2015;5(01):20
12. O'malley ME Hahn P.F., Yoder I.C., Gazelle G.S., McGovern F.J., Mueller P.R. Comparison of Excretory Phase, Helical Computed Tomography with Intravenous Urography in Patients with Painless Haematuria. *Clinical Radiology*. 2003;58(4):294-300.
13. Shinagare AB, Davenport MS, Park H, Pedrosa I, Remer EM, Chandarana H, Doshi AM, Schieda N, Smith AD, Vikram R, Wang ZJ, Silverman SG. Lexicon for renal mass terms at CT and MRI: a consensus of the society of abdominal radiology disease-focused panel on renal cell carcinoma. *AbdomRadiol (NY)*. 2021 Feb;46(2):703-722.
14. Bhoil R, Kumar R, Kaur J, Attri PK, Thakur R. Diagnosis of Traumatic Pneumothorax: A Comparison between Lung Ultrasound and Supine Chest Radiographs. *Indian J Crit Care Med*. 2021 Feb;25(2):176-180. doi: 10.5005/jp-journals-10071-23729. PMID: 33707896; PMCID: PMC7922442.
15. Kalra MK, Rizzo S, et al. Multidetector CT urography in imaging of the urinary tract in patients with hematuria. *Korean journal of radiology*. 2004;5(1):1–0
16. Cowan NC. CT urography for hematuria. *Nature Reviews Urology*. 2012;9(4):218