

# Ameloblastic-Fibrodentinitoma

Dr. Sangeetha Priya.P ,Dr.N.Anitha, Dr.L.Malathi, Dr.K.M.K.Masthan

*Professor, Department of Oral Pathology and Microbiology  
Sree Balaji Dental College and Hospital  
Bharath Institute of Higher Education and Research*

## **ABSTRACT:**

*Ameloblastic fibrodentinitoma is a benign odontogenic tumor belonging to the category of "odontogenic epithelium with odontogenic ectomesenchyme" along with recognition of induction in the form of dentin in atypical or dysplastic forms. The biological behaviour of ameloblastic fibrodentinitoma is not very different from ameloblastic fibroma; hence, it is treated similarly by conservative procedures. It is important to understand the histopathogenesis of these rare tumors. Though rare, they are an independent entity awaiting recognition. Here, we report a case of ameloblastic fibrodentinitoma.*

**KEY WORDS:** *Ameloblastic fibrodentinitoma, odontogenic tumors, ameloblastic fibroma, odontogenic mixed tumor*

## **INTRODUCTION:**

The Ameloblastic fibrodentinitoma (AFD) is a rare benign tumor, belong to mixed odontogenic tumour. There is a limited proliferation of odontogenic epithelium of the enamel organ and odontogenic mesenchyme of the primitive dental pulp. This results in soft tissue recapitulation of the dental follicle, which produces predominantly dentin. This group of lesion includes Ameloblastic fibroma (AF), AFD, Ameloblastic fibroodontoma (AFO). The extent of histodifferentiation of AFD is considered to be intermediate stage between the AF and AFO<sup>1</sup>. It is a rare occurrence with less than 1% of odontogenic tumor and more in males compared to females in the ratio of 3:1<sup>2</sup>. The first case of AFD was reported by Straith in 1936<sup>3</sup>. As this entity is uncommon and difficult to interpret, the related nomenclature has been subjected to changes during these years. Different classifications and terminologies have been used for this tumor. According to World Health Organisation classification<sup>4</sup> this tumor is termed as "ameloblastic fibrodentinitoma." And WHO states that Ameloblastic fibrodentinitoma is not a true neoplasm and has features similar to ameloblastic fibroma. In addition there are inductive changes that lead to the formation of dentin. AFD is also called as Dentinoma<sup>5</sup>.

## **MIXED ODONTOGENIC TUMOR:**

Mixed odontogenic tumors are composed of both epithelial and mesenchymal tissues. These tumors recapitulate proliferation and differentiation as seen in the developing teeth which often includes the deposition of the dental hard tissues – enamel and dentin, sometimes even leading to the development of multiple tiny teeth. Lesions with an identical histology can show either a neoplastic as well as an hamartomatous behavior<sup>6</sup>. Ameloblastic fibrodentinitoma fall under the category of mixed odontogenic tumor but most often encountered with less literature details as this is one of the rare benign tumor.

## **CLINICAL FEATURES OF AMELOBLASTIC FIBRODENTINITOMA:**

This tumor is commonly seen in the younger age group, with most patients being below 30 years. However, there are other reports showing development of this tumor in older age group<sup>7</sup>. The most commonly involved site is the mandible as compared to maxilla (maxilla:mandible = 1:3), molar region being most commonly involved site<sup>7,8</sup>.Ulmansky et al<sup>8</sup>. in their review of literature stated that, the maxilla was affected only in nine instances (27%) while in the remaining 24 cases (72.4%) the tumor developed in the mandible (ratio 1:3). It has been

reported that when the lesion is associated with deciduous teeth it is generally located in the incisor area, while those occurring in the vicinity of permanent teeth show a preference for the molar region<sup>8</sup>. In the maxilla all the cases reported have occurred in the molar region. Only two cases showed occurrence of this tumor in the anterior region of maxilla involving a deciduous incisor<sup>8,9</sup>. A recent case presentation shows occurrence of this tumor involving the maxillary canine. But occurrence of AFD in the anterior region of the maxilla involving a permanent incisor is not reported so far. Thus to the best of our knowledge, the present case would be the first report of development of AFD in the maxillary anterior region involving the permanent incisor. AFD is a controversial neoplasm with respect to its biological nature and histological diagnosis. There is still discussion about the biological nature of this tumor. It has been suggested that AFD is not a true neoplasm but a hamartoma. The limited growth potential of the tumor may support this suggestion. But World Health Organization publication on histological typing of odontogenic tumors defined AFD lesion as “a very rare neoplasm composed of odontogenic epithelium and an immature odontogenic connective tissue, and characterized by the formation of dysplastic dentin”.

### **HISTOGENESIS OF AMELOBLASTIC FIBRODENTINOMA:**

Mixed Odontogenic tumours are a heterogeneous group of lesion with diverse clinical and histopathological features. Ameloblastic fibroma, Ameloblastic fibroodontoma, Ameloblastic fibrodentinoma and Odontoma belong to this group. The inter relationship between odontogenic tumours, regarding origin histodifferentiation and maturation is often debated. The exact histogenesis of ameloblastic fibrodentinoma is unclear. It is thought to fall in a stage between the ameloblastic fibroma and the ameloblastic fibro-odontoma in histogenesis<sup>10</sup>. The general pattern of primitive odontogenic epithelium and connective tissue in AFD is similar to that of ameloblastic fibroma. Hence the term “ameloblastic fibrodentinoma” has been applied. It seems that majority of cases of AFD occur as central intraosseous tumor. However, a case of peripheral ameloblastic fibrodentinoma occurring in the gingiva has been reported<sup>11</sup>.

### **RADIOLOGIC FEATURES:**

Radiographically it appears as a mixed radiolucent - radiopaque lesion. AFD are well delineated radiolucencies with varying degrees of radiopacity and frequently found in relation to malposed, unerupted teeth<sup>12</sup>. Various differential diagnosis to consider are ameloblastic fibrodentinoma, calcifying epithelial odontogenic tumor, calcifying odontogenic cyst and adenomatoid odontogenic tumor.

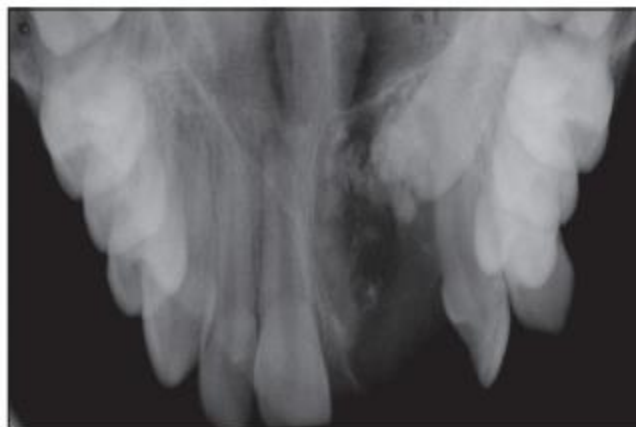

Figure-1 Maxillary occlusal radiograph showing well defined unilocular radiolucency with specks of radiopaque foci involving 21

### HISTOPATHOLOGICAL FEATURES:

Differentiating Ameloblastic fibrodentinoma from other mixed odontogenic tumour like Ameloblastic fibroma, Ameloblastic fibroma odontoma and odontoma requires knowledge about the pathogenesis, radiographic appearance and histological features of all of them. The soft tissue component of the ameloblastic fibrodentinoma is microscopically identical to the ameloblastic fibroma. The histopathological view shows strands and islands of odontogenic epithelium in cell rich/ highly cellular myxoid connective tissue stroma. The center of islands appears enclosed and the cells of the island are tall columnar cells with reverse polarity and cluster of island resembling stellate reticulum. The connective tissue consists of plump fibroblasts with ovoid hyperchromatic/vesicular nucleus with indistinct cell borders. Dentinoid or dystrophic osteodentin deposition with the presence of a hyalinized area as a halo is seen within deeper connective tissue, entrapping individual and islands of odontogenic epithelium. Sometimes few mitotic figures may also be noticed<sup>13,14</sup>.

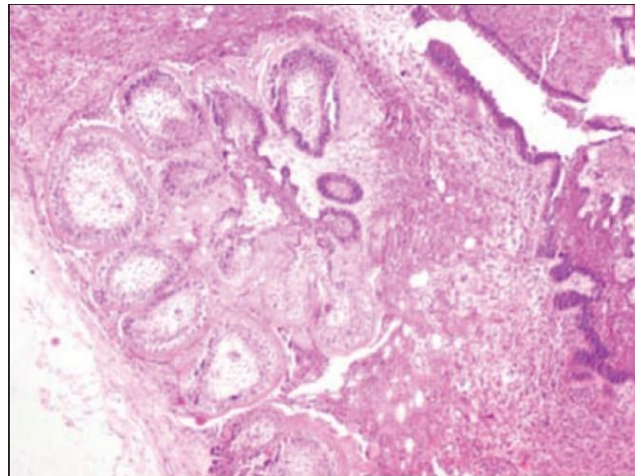


Figure 2-Histopathological view of Ameloblastic fibrodentinoma showing multiple strands and follicles of odontogenic epithelium in a cell-rich connective tissue surrounded by a fibrous capsule.

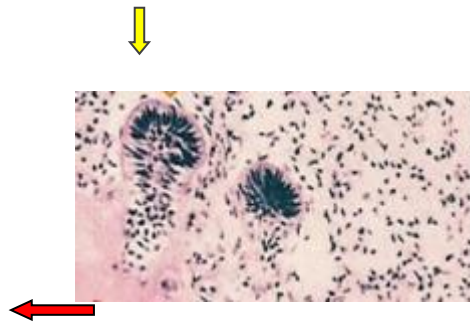


Figure 3- Yellow arrow- Islands enclosing cells resembling stellate reticulum and Red arrow- dentinoid or osteodentin deposition within deeper connective tissue

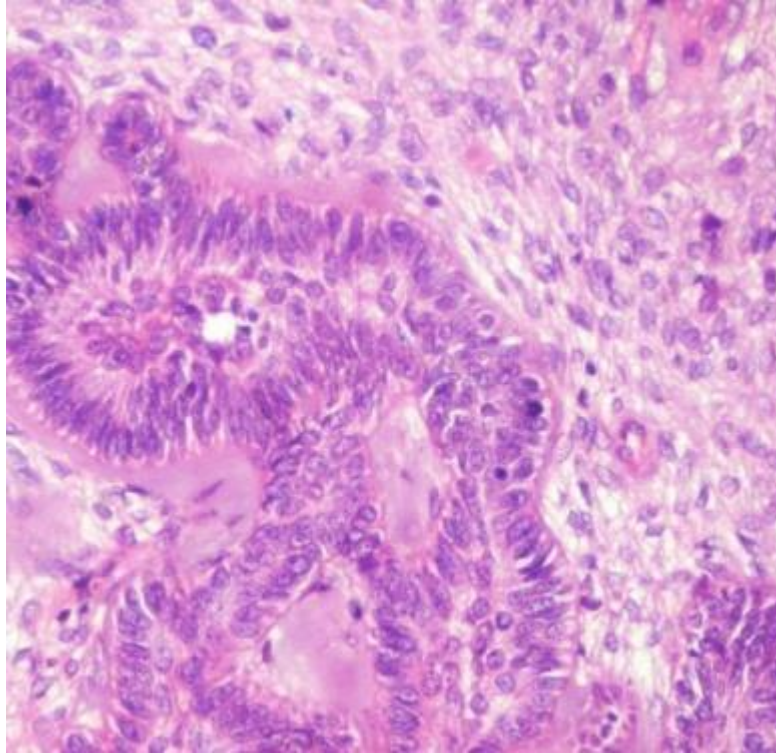


Figure 4- follicles of odontogenic epithelium surrounded by pale eosinophilic hyalinized area resembling dentin is seen.

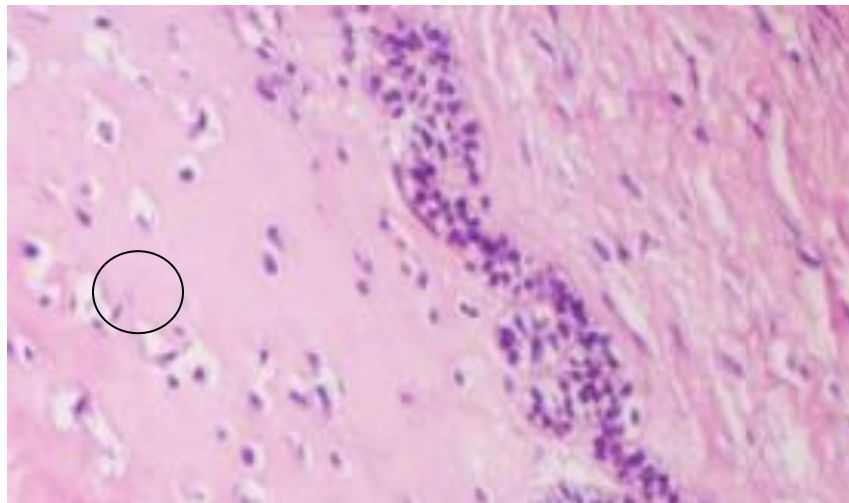

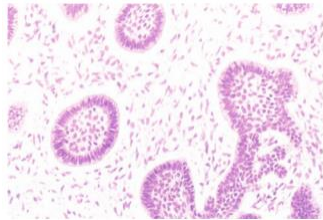


Figure 5- The encircled area show pale eosinophilic hyalinized area with entrapped epithelial cells resembling osteodentin.

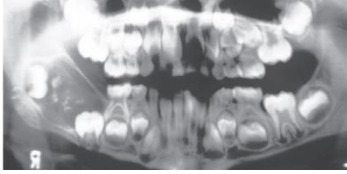
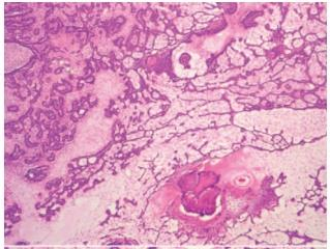

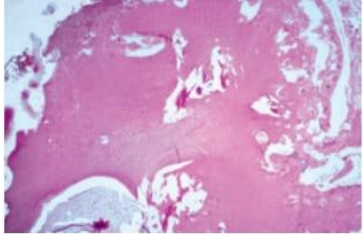
#### DIFFERENTIAL DIAGNOSIS OF AMELOBLASTIC FIBRO DENTINOMA:

As mentioned before differentiating Ameloblastic fibrodentinoma from other mixed odontogenic tumour like Ameloblastic fibroma, Ameloblastic fibroma odontoma and odontoma requires knowledge about the pathogenesis, radiographic appearance and histological features of all of them

	CLINICAL FEATURES	RADIOGRAPHIC FEATURES	HISTOLOGIC FEATURES
--	-------------------	-----------------------	---------------------

<p><b>AMELOBLASTIC FIBROMA</b></p>	<p>Occurs in younger patients-the first two decades of life. It is slightly more common in males than in females. Small ameloblastic fibromas are asymptomatic; larger tumors are associated with swelling of the jaws. The posterior mandible is the most common site<sup>13</sup>.</p>	<p>either a unilocular or multilocular radiolucent lesion is seen, with the smaller lesions tending to be unilocular. The radiographic margins tend to be well defined, and they may be sclerotic. An unerupted tooth is associated with the lesion in about 75% of cases. The ameloblastic fibroma may grow to a large size, and cases that involve a considerable portion of the body and ascending ramus of the mandible have been reported<sup>13,14</sup>.</p>  <p>Figure-6 - Well-defined radiolucent defect associated with an unerupted second molar</p>	<p>the tumour consists of strands and islets of epithelial cells somewhat resembling the arrangement seen in ameloblastoma. The intervening tissue, however, is a richly cellular connective tissue that resembles the dental papilla of the developing tooth. In the other pattern, the epithelial cells form small, discrete islands that resemble the follicular stage of the developing enamel organ. These show peripheral columnar cells, which surround a mass of loosely arranged epithelial cells that resemble stellate reticulum<sup>13</sup>. In contrast to the follicular type of ameloblastoma, these follicular islands in the ameloblastic fibroma seldom demonstrate microcyst formation.</p>  <p>Figure-7- Ameloblastic fibroma</p>
<p><b>AMELOBLASTIC FIBRO-ODONTOMA</b></p>	<p>usually encountered in children with an average age of 10 years. It is rarely encountered in adults. Like the ameloblastic fibroma, ameloblastic fibro-odontomas occur more frequently in the posterior regions of the jaws. There is no significant sex predilection. The lesion is commonly asymptomatic and is discovered when radiographs are taken to determine the reason for</p>	<p>Radiographically, the tumor shows a well-circumscribed unilocular or, rarely, multilocular radiolucent defect that contains a variable amount of calcified material with the radiodensity of tooth structure. The calcified material within the lesion may appear as multiple, small radiopacities or as a solid conglomerate mass<sup>13</sup></p>	<p>identical to the ameloblastic fibroma and has narrow cords and small islands of odontogenic epithelium in a loose primitive appearing connective tissue that resembles the dental papilla. The calcifying element consists of foci of enamel and dentin matrix formation in close relationship to the epithelial structures. The more calcified lesions show mature dental structures in the form of rudimentary small teeth or</p>



	<p>failure of a tooth to erupt. Large examples may be associated with a painless swelling of the affected bone<sup>13</sup>.</p>	 <p>Figure-8 -Radiolucent defect in the ramus containing small calcifications having the radiodensity of tooth structure</p>	<p>conglomerate masses of enamel and dentin<sup>14</sup>.</p>  <p>Figure-9 – Ameloblastic fibro-odontoma</p>
<p>ODONTOMA</p>	<p>Odontomes are essentially hamartomas consisting of fully formed dental tissues which are more or less normal qualitatively but are present in abnormal quantity and arrangement. When fully mature, odontomes consist principally of enamel and dentine, but during the period of active growth ameloblastic epithelium and odontoblastic tissue are present. Most of these lesions are detected in children and adolescents, and more often in the mandible than the maxilla. There are frequently no symptoms and the lesion may be discovered in the course of routine radiographic examination, In most cases the lesion is associated with the permanent dentition and is solitary. Multiple odontomes are rare. There are two main types of odontome, the complex and the compound. The former consists of a circumscribed tumour-like mass of dental tissues laid down in a quite irregular manner. The latter is a collection of small teeth or tooth-like structures<sup>13,14</sup>.</p>	 <p>Figure 10- Multiple/ small cluster of toothlets preventing the eruption of the mandibular cuspid<sup>13</sup></p>	<p>The compound odontoma consists of multiple structures resembling small, single-rooted teeth, contained in a loose fibrous matrix. The mature enamel caps of the toothlike structures are lost during decalcification for preparation of the microscopic section, but varying amounts of enamel matrix are often present. Pulp tissue may be seen in the coronal and root portions of the toothlike structures. In patients with developing odontomas, structures that resemble tooth germs are present<sup>14</sup>.</p>  <p>Figure 11- This decalcified section shows a disorganized mass of dentin intermixed with small pools of enamel matrix.</p>

## CONCLUSION:

Ameloblastic fibrodentinoma (AFD) is a rare benign mixed odontogenic tumour which is non-invasive. This is found more in children and young adults. Ameloblastic fibrodentinoma should be considered in the differential diagnosis of mixed lesions. The treatment of choice is surgical excision and the recurrence is rare. Hence a thorough clinical, radiological and histological evaluation with long term follow up is necessary.

## REFERENCES:

1. Bhargava D., et al. "Ameloblastic fibrodentinoma". Indian Journal of Dental Research 22.2 (2011): 345-347.
2. Joseph S., et al. "Ameloblastic fibrodentinoma presenting as a false gingival enlargement in the maxillary anterior region". Case Reports in Dentistry (2015): 812087.
3. Straith FE. Odontoma. A rare type. Report of a case. Dent Dig 1936;42:196.
4. Kramer IR, Pindborg JJ, Shear M. World Health Organization histological typing of odontogenic tumors. 2nd ed. Berlin: Springer; 1992.
5. Giraddi GB and Garg V. "Aggressive atypical ameloblastic fibrodentinoma : Report of a case". Contemporary Clinical Dentistry 3.1 (2012): 97-102.
6. Barnes L, Eveson JW, Reichart PA, Sidransky D, editors. World Health Organization Classification of Tumours. Pathology and Genetics of Head and Neck Tumours. Lyon: IARC Press; 2005. Chapter 6, Odontogenic Tumours; p. 283–327.
7. Husted E, Pindborg JJ. Odontogenic tumors. Clinical and roentgenological aspects, treatment and pathology. Odontol Tidskr 1953;61:275-92.
8. Ulmanky M, Bonder L, Praetorius F, Lustman J. Ameloblastic fibrodentinoma: Report on two new cases. J Oral Maxillofac Surg 1994;52:980-4.
9. Akal UK, Gunhan O, Guler M. Ameloblastic fibrodentinoma. Report of two cases. Int J Oral Maxillofac Surg 1997;26:455-7.
10. Slootweg PJ. An analysis of the inter-relationship of the mixed odontogenic tumors-ameloblastic fibroma, ameloblastic fibro-odontoma and the odontomas. Oral Surg Oral Med Oral Pathol 1981;51:266-76
11. McKelvy BD, Cherrick HM. Peripheral ameloblastic fibrodentinoma. J Oral Surg 1976;34:826-9.
12. Slootweg PJ: Chapter 6: Odontogenic tumors. World Health Organization Classification of Tumours: Pathology and Genetics of Head and Neck Tumours. 2nd ed. Barnes L, Eveson JW, Reichart P, Sidransky D (ed): IARCPress, Lyon; 2005. 3:308.
13. Neville , Damm, Allen, Bouquot :Text book of oral and maxillofacial pathology,3<sup>rd</sup> edition,2009
14. R.B.Lucas, J.W.Evenson – Atlas of oral pathology,chapter 10-tumors of the oral tissues, odontogenic tumors